

Ultrastructural haemomicrocircular channel links of rat testicle in streptozotocin-induced diabetes

Yurij Kryvko¹, Lesa Mateshuk-Vatseba¹, Iryna Savka¹, Iwona Łuszczewska-Sierakowska², Agata Wawrzyniak², Elżbieta Radzikowska³, Ryszard Maciejewski³

¹ Danylo Galytskyi National Medical University, L'viv, Ukraine

² Department of Animal Anatomy and Histology, Faculty of Veterinary Medicine, University of Life Sciences, Lublin, Poland

³ Department of Human Anatomy, Faculty of Medicine, University of Lublin, Poland

Kryvko Y, Mateshuk-Vatseba L, Savka I, Łuszczewska-Sierakowska I, Wawrzyniak A, Radzikowska E, Maciejewski R. Ultrastructural haemomicrocircular channel links of rat testicle in streptozotocin-induced diabetes. *J Pre-Clin Clin Res.* 2014; 8(2): 86–89.
doi: 10.5604/18982395.1135656

Abstract

The first changes in rat testicle haemomicrocircular channel links ultrastructural arrangement are noticed already in a 2-week run of streptozotocin-induced diabetes mellitus, and accumulate throughout next periods of the experiment. Angiopathy is a trigger mechanism for diabetic development of testicle structural changes. This finding is a basis for further morphologist and clinician surveys for the purpose of new diabetic testicle pathology diagnostics, prevention, and elaboration of treatment techniques.

Key words

testicle, hemomicrocircular channel, diabetes mellitus

INTRODUCTION

Diabetes mellitus (DM) is one of the most serious health problems worldwide, being a group of metabolic diseases characterized by hyperglycaemia associated with a defect in insulin secretion and sensitivity to the hormone [1, 2, 3]. The increase in blood glucose level leads to structural and functional changes in a variety of target tissues and organs. Streptozotocin-induced diabetes in rats is frequently used to study the disturbances in lipid metabolism under diabetic conditions [4, 5, 6]. The main complication is a disease of the blood vessels, called angiopathy. The consequences of chronic hyperglycaemia in diabetes are divided into microangiopathy and macroangiopathy [7, 8, 9].

The most frequent and prognostically unfavourable complication of diabetes mellitus is microangiopathy [10, 11, 12]. The diabetic changes in testicle haemomicrocircular channel links serve as the basis for diabetic development of testicle structures pathological changes [13, 14, 15]. In spite of the topicality and significance of the issue, the professional literature contains scant information on testicle rearrangement in various pathological conditions [3, 16, 17, 18], and there are practically no data on diabetic testicle haemomicrocircular channel links ultrastructural arrangement.

Objectives

To discover peculiarities of rat testicle links ultrastructure in the norm and over time of streptozotocin-induced diabetes mellitus.

MATERIALS AND METHOD

The research was performed on 20 white mature male rats aged 4.5–7.5 months with body weight of 130 to 150 g. Research material is represented by ultramicroscopic testicle slice. Experimental diabetes modelling was performed through a single intraperitoneal injection of Streptozotocin (Sigma, USA), dissolved in 0.1M citrate buffer, pH=4.5 (7 mg per 100 g of body weight of animals). The diabetes mellitus progression was controlled according to glucose concentration in blood, which was measured by glucose oxidase test. Animals in whose blood glucose concentration at 2, 4, 6, 8 weeks after launch of the experiment was above 13.4 mmol/l were used for the research.

The animals were kept and experimented on in compliance with the European Convention for the Protection of Vertebrate Animals used for Experimental and other Scientific Purposes (Strasbourg, 1985) and the 'General Ethical Principles for Experiments on Animals' adopted by First National Bioethics Congress (Kiev, 2001). The work was performed with the method of electronic microscopy.

The animals were sacrificed by overdose of intraperitoneal narcosis with thiopental sodium (25 mg/kg). Straight after the death of the animal, the sampling and standard material processing for electronic microscopy was performed. Ultrathin slices were prepared at UZhTP-3 ultramicrotome with glass knives. For the research, slices of silver and lemon yellow colour were taken. Contrast was obtained by first treating the slices with 2% uranyl acetate solution, then with plumbum citrate. Material study and photographic recording were performed with UEMV-100K microscope at accelerating voltage of 75kV and microscope magnification of 10,000–12,400×.

Address for correspondence: Agata Wawrzyniak, Department of Animal Anatomy and Histology, Faculty of Veterinary Medicine, University of Life Sciences in Lublin, Poland

E-mail: agata.wawrzyniak@up.lublin.pl

Received: 24 April 2014; accepted: 28 May 2014

RESULTS AND DISCUSSION

Testicle haemomicrocircular channel links are located in the connective tissue surrounding the winding seminal ducts and in their wall. Arterioles pass between seminal ducts. The arteriolar wall consists of three coats. The cross-section of endotheliocytes proves their elongated form with scarce arterioles projecting into lumen. Plasmalemma forms numerous warts; cytoplasm has average electron optical density and contains a considerable amount of organelles and micropinocytic vesicles. Adjacent endotheliocytes come into contact forming desmosomes and interdigitations. Nuclei have an elongated form with prevailing uncondensed chromatin, but a well-defined strip of peripheral condensed chromatin by the nucleomma. The basement membrane has sharp contours and is continuous, and the inner elastic membrane is detected from outside. This is thin and has an irregular wavy contour. Smooth myocytes of the arteriole wall middle coat form a single layer, and have electron-light cytoplasm, contain elongated nuclei, and there are clearly seen the sites of myofibrils affixed throughout all plasmalemma. The adjacent smooth myocytes have desmosome contacts. Arteriole lumens are filled with blood cells (erythrocytes, thrombocytes). Longitudinal and latitudinal capillaries are seen, intertwined with one another, with the latitudinal ones forming capillary networks in the winding ducts. Some of the capillaries have narrow lumens and do not contain blood cells, whereas the rest have broad lumens filled with erythrocytes.

On the ultrastructural level, the capillary wall is typical and consists of endotheliocytes in the amount of 2–4 located on the basement membrane with sharp even contours. In each endotheliocyte there are the nucleus-containing and peripheral areas. Endotheliocyte nuclei have an elongated form with sharp contours. The nuclei contain mainly uncondensed chromatin, as well as a thin strip of peripheral condensed chromatin. Small amounts of condensed chromatin lie smoothly in karyoplasm. In the area around the nucleus there is a granular endoplasmic reticulum represented by ducts and cisterns, membranes of which hold significant ribosome amount; Golgi apparatus, and mitochondria. The plasmalemma infrequently forms small microvilli. Endotheliocyte basal surfaces have a tightly fitting solid basement membrane with pericytes between its layers. The pericyte nucleus has an oval form with chromatin proportionally located in the nucleoplasm. Located next to it are the Golgi apparatus, granular endoplasmic reticulum, mitochondria, and individual free ribosomes and vesicles. Venules, in contrast to arterioles, have broad lumens of irregular form. The venule wall consists of a thin layer of endothelial cells on the basement membrane. Endotheliocyte cytoplasm is electron-light and contains insignificant amount of organelles. Venule lumens are filled with blood elements (Fig. 1).

In the 2-weeks run of streptozotocin-induced diabetes mellitus in the testicle haemomicrocircular channel links the first signs of angiopathy were found. Endotheliocyte swelling was seen in the capillaries and the capillary lumens acquired an irregular form. In the capillary lumens the erythrocyte adhesion and aggregation took place. Electron-dense endotheliocyte nuclei projected into the vessel lumen. Endotheliocyte nuclei acquired an excessively elongated form; nucleomma formed numerous protrusions and invaginations;

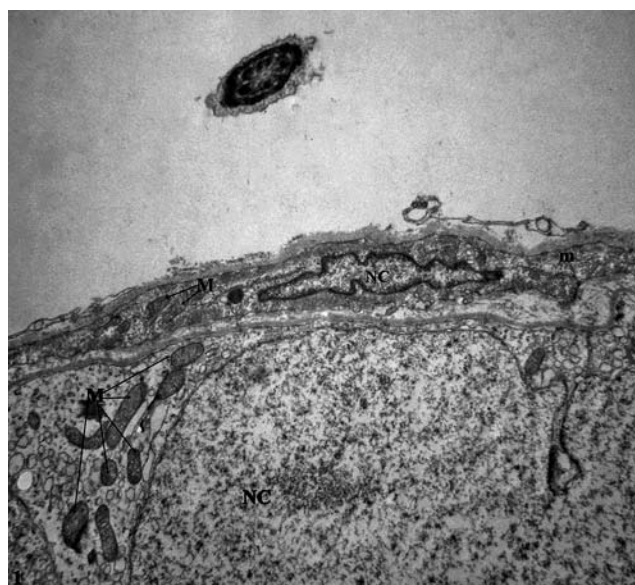


Figure 1. Electron micrograph from part of arterioles. Arteriolar wall consists of three coats. The cell has irregular chromatin in nucleus (NC), and normal tubular form of mitochondria (M) are seen in the cytoplasm. Myocyt (m) with electron-light cytoplasm, contains elongated nucleus (NC) (mag. approx 10,000 x)

chromatin had marginal location, and the nucleus-free endotheliocyte areas were thinned. Endotheliocyte cytoplasm electron optical density was increased and the number of organelles decreased. Slits between adjacent endotheliocytes were dilated. In individual mitochondria there were the matrix clarification and single cristas destruction noticed. Plasmalemma formed infrequent projections into the capillary lumen which resulted in a thickening of the basement membrane. The basement membrane had no sharp outer contour although it maintained continuity and had an expressed three-layer composition. Pericytes generally preserved their connection to the basement membrane, although they were sometimes exfoliated from it. Penetrating through the basement membrane, the pericytes had direct contact with endotheliocytes; capillary lumen was narrowed. Bundles of collagen fibres were fluffed, and exfoliated from one another with the amorphous liquid spans. By the haemocapillaries, granule cells and interstice swelling were found. The testicle arteriole lumens were somewhat narrowed in this experimental period. Some arteriolar endotheliocytes were damaged; basement membrane thickened and lost its sharp contours. Inner elastic membrane was also thickened. Nuclei of smooth myocytes acquired a rod-shaped form with even contours. The structure of the venule walls was still preserved, but venule lumens were partially dilated.

After 4 weeks of experimental diabetes mellitus, a decrease in electron optical density of capillary endotheliocytes, partial exfoliation of endothelium in the testicle capillaries was observed due to which the basement membrane was partly bare. The destroyed endotheliocyte nuclei projected into the capillary lumens. The swelling of vessel walls intensified, as well as the separation of fibres and thickening of basement membrane. The basement membrane was irregular, had vague contours and infrequent pores. In the pericytes, the marginal location of nuclear chromatin was observed; in the mitochondria there was cristas broadening and fragmentation. In the testicle arteriole endotheliocytes, nuclear pores were noticed at the nucleus periphery.

It is difficult to define the boundaries between condensed and uncondensed chromatin. Smooth myocytes cytoplasm have an average electron optical density; bundles of myofibrils are partly destructurized. Arteriole adventitious coating is also swollen, thickened, with a significant amount of amorphous liquid between the bundles of collagen fibres. Venule lumens often acquire irregular, sometimes star-shaped form. In small testicle venules, mural thrombi are found.

Six weeks after the start of the experiment, a considerable number of destroyed testicle capillaries were seen, the wall was thickened, and narrowing of the preserved capillary lumens seen. In the capillary lumens, the thrombocyte adhesion and erythrocytic sludges were discovered. Endotheliocyte nuclei in the preserved capillaries were excessively elongated, swollen, and projected deeply into the capillary lumen. Small nuclei were not found. In the endotheliocytes cytoplasm, destruction of the Golgi apparatus structural elements were observed, together with destruction of the mitochondria inner membrane with vacuole formation. Microclasmatosis phenomenon had taken place. Plasmalemma projected into the microvessel lumen, and the basement membrane thickened, without sharp contours. Pericyte nuclei acquired an elongated form with small invaginations, nuclear chromatin marginalization, mitochondrial cristas broadening and fragmentation. Arteriole lumens were filled with blood elements. Arteriole endotheliocytes were thickened, their cytoplasm had a considerable amount of mitochondria and free ribosomes. Cristas destruction was seen in the mitochondria. Endotheliocyte cytoplasm was vacuolated, with decreased electron optical density, and their cytoplasm had formed warts. Nucleomma had formed numerous small projections. The condensed chromatin had a fine-granular appearance. Arteriole middle coat smooth myocyte cytoplasm had average electron optical density, and was partly destructurized. In some places, myofibril-affixing areas were structurally preserved.

After 8 weeks of streptozotocin-induced diabetes mellitus, deep destructive changes in all rat testicle haemomicrocircular channel links were seen. Capillary lumen was decreased. Endotheliocytes in the preserved capillaries acquired columnar standing, which is peculiar to the tissue hypoxic state. The nucleus-containing endotheliocyte areas projected deeply into the capillary lumen, and had a slit-like form. Plasmalemma formed long appendices, twisted in places, and projected into the capillary lumen. Inter-cell slits between adjacent preserved endotheliocytes were narrow, disorganized, and desmosomes found in the apical and basement areas of endotheliocyte contacts. Cytoplasm had increased electron optical density; mitochondria were swollen, vacuolated, some of them having destructurized cristas, and damaged membranes. In the cytoplasm there were found round, electron-optically dense corpuscles. There were practically no micropinocytotic vesicles in the endotheliocytes, which proved a decrease in transendothelial transport. Endotheliocyte nuclei were elongated, contained condensed chromatin, and enlarged nuclear pores. Small nuclei were not found. In the basement membrane there were alternate areas of increased and decreased electron optical density, and the pericytes were swollen. Cericyte nuclei were electron dense, with destructurized chromatin, small nuclei not found, and mitochondria had destroyed cristas. Arterioles in this experimental period were dilated, but their lumens

were narrowed on account of high columnar endotheliocytes that projected deeply into the arteriole lumen. Endotheliocyte cytoplasm was dark, structureless, with single mitochondria. Endotheliocyte nuclei nucleomma formed numerous long appendices, chromatin was condensed. The basement membrane was thickened, contained electron-optically dense corpuscles, and no inner membrane was found. Smooth myocytes cytoplasm was destructurized. Each myocyte was surrounded by electron-dense plasmalemma with clearing areas (Fig. 2).

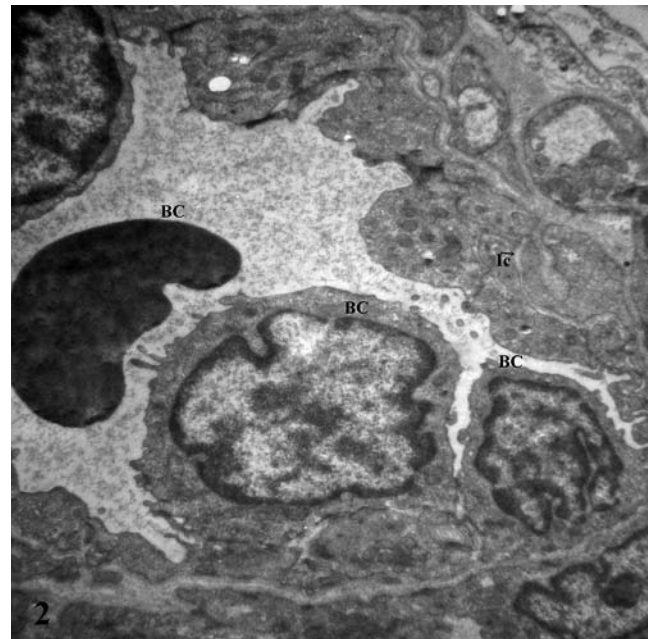


Figure 2. Electron micrograph from part of capillary vessels after 8 weeks of streptozotocin-induced diabetes mellitus. Apparent intercellular canaliculi (IC). Blood cells (BC) in the capillary lumen (BC), mag. Approx. 12,000x

After 10 weeks of the experimental diabetes run, haemocapillary channel underwent significant changes. Due to projection of increased in size endotheliocyte nuclei into the capillary lumen, the latter acquired an irregular slit-like form. The nucleoplasm of endotheliocyte and pericyte nuclei had low electron density, chromatin was condensed by the nucleomma. The perinuclear lumen was narrowed. Endoplasmic reticulum was characterized by dilations, vacuolated cisterns with irregular contours, with loosing ribosomes affixed to their surface. Mitochondria were swollen, with a cleared matrix and destroyed cristas. Endotheliocyte and pericyte cytoplasm had low electron-density, contained small and large vacuoles. Sometimes, separation of the joints between endothelial cells was seen. The basement membrane was thickened and acquired vague contours. Pericytes had an irregular form, were bigger in size with vague contours. Cericyte cytoplasmic appendices contained a substantial number of vesicles and vacuoles. In the capillary lumens there were erythrocytic sludges and thrombocyte aggregates. Endotheliocyte nuclei had marginally located chromatin and deep karyolemma invaginations. By the nucleus there were dilated and destroyed cisterns of the Golgi apparatus, granular endoplasmic reticulum, and mitochondria with destructive changes. The plasmalemma luminal surface formed numerous invaginations into the capillary lumen. The basement membrane was irregularly thickened. Capillary

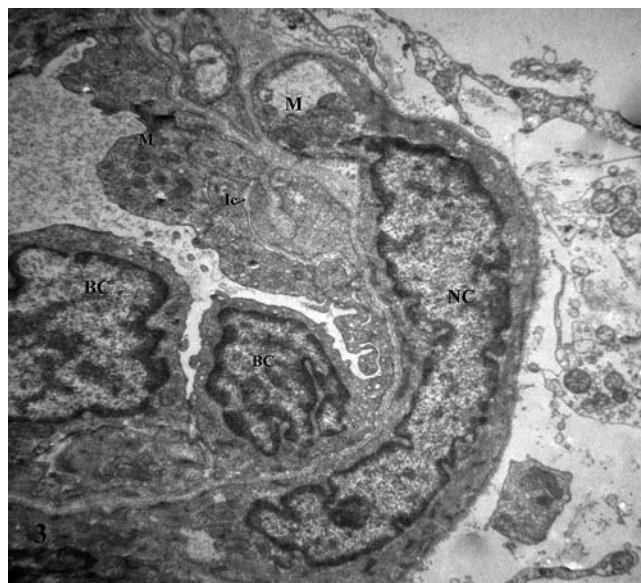


Figure 3. Electron micrograph from part of capillary vessels after 10 weeks of streptozotocin-induced diabetes mellitus. Clumps of heterochromatin located in marginal part of nucleus (NC), mitochondria are swollen, vacuolated, some of them have destructurized cristas (M). Intercellular canaliculi (Ic) between cells. Capillary lumens are filled with blood elements (BC) (mag. approx 10,000×)

sclerosis occurrences accumulated, pericapillary spaces were dilated (Fig. 3).

The first changes in rat testicle haemomicrocirculatory channel links ultrastructural arrangement were noticed already after 2-weeks run of streptozotocin-induced diabetes mellitus, and accumulated throughout following periods of the experiment.

CONCLUSIONS

Angiopathy is a trigger mechanism for diabetic development of testicle structural changes.

The findings of the presented research are a basis for further morphologist and clinician surveys for the purpose of new diabetic testicle pathology diagnostics, prevention and elaboration of treatment techniques.

REFERENCES

1. Borovkova SA. Questions of pathogenesis of diabetic angiopathy. *Bukovina Medical Bulletin*. 2006; 2: 132–135.
2. Mogylnytska LA. Endothelial dysfunction in diabetes mellitus type 2. *Endocrinology*. 2001; 1: 95–103.
3. Saltykov BB. Diabetic microangiopathy. *Moscow* 2002; 23–25.
4. Arikawe AP, Oyerinde A, Olatunji Bello II, Obika LFO. Streptozotocin diabetes and insulin resistance impairment of spermatogenesis in adult rat testis: central Vs local mechanism. *Niger J Physiol Sci*. 2012; 27(2): 171–179.
5. Gamal MA. Hassan and Tarek Abdel M. Structural Changes in the Testes of Streptozotocin-Induced Diabetic Rats. *Suez Canal Univ Med J*. 2001; 4: 17–25.
6. Ji-Ping Liu, Liang Feng, Ming-hua Zhang, Dong-ying Ma, Shu-yuan Wang, Junfei Gu, Qiang Fu, Rong Qu, Shi-ping Ma. Neuroprotective effect of Liuwei Dihuang decoction on cognition deficits of diabetic encephalopathy in streptozotocin-induced diabetic rat. *J Ethnopharmacol*. 2013; 150: 371–381.
7. Flyvbjerg A. Diabetic angiopathy, the complement system and the tumor necrosis factor superfamily. *Nat Rev Endocrinol*. 2010; 6: 94–101.
8. Hammes HP. Pathophysiological mechanisms of diabetic angiopathy. *J Diabetes Complications*. 2003; 17(2): 16–19.
9. Škrha J. Pathogenesis of angiopathy in diabetes. *Acta Diabetol*. 2003; 40(2): 324–329.
10. Fereshteh K, Ozra N, Shahriar A, Vahid N. Sesame effects on testicular damage in streptozotocin-induced diabetes rats. *A J Phytomed*. 2013; 3: 347–355.
11. Roghani M, Baluchnejadmojarad T, Roghani Dehkordi F. The Sesame Lignan Sesamin Attenuates Vascular Permeability in Rats with Streptozotocin-Induced Diabetes: Involvement of Oxidative Stress. *Int J Endocrinol Metab*. 2011; 9: 248–252.
12. Setchell BP. Human reproduction. The missing parts of the puzzle. *Adv Exp Med Biol*. 1997; 424: 1–15.
13. Fukudome D, Matsuda M, Kawasaki T, Ago Y, Matsuda T. The radical scavenger edaravone counteracts diabetes in multiple low-dose streptozotocin-treated mice. *Eur J Pharmacol*. 2008; 1:164–169.
14. Pshenychnyy NF. Model microcirculator in the testes in normal and varicocele. *J Morphol*. 2005; 11: 60–62.
15. Луцицкий EV. Structural-functional state and the blood supply to the testes in diabetic patients. *Bukovina medical Bulletin*. 2002; 1: 79–81.
16. Ivasyuk IJ. Changes in the blood vessels and testicular parenchyma after his injury. *Uzhhorod University Scientific Herald, Series Medicine* 2004; 23: 18–19.
17. Anigi S, Romanello MG, Domeneghini C. Ultrastructure of the epithelium lines that the ductuli efferentes testis in domestic eguidae, with particular reference to spermatophagy. *Acta Anat (Basel)*. 1994; 149: 174–184.
18. Shahreari Sh, Khaki A, Ahmadi-Ashtiani HR, Hajiaghahi R, Rezazadeh Sh. Effects of *Danae racemosa* on testosterone hormone in experimental diabetic rats. *J Med Plants*. 2010; 9: 114–119.