CASE REPORT

Journal of Pre-Clinical and Clinical Research
www.jpccr.eu

Metachronous breast and cervical cancers and subsequent IPMN of the pancreas in a premenopausal female patient – case report

Bartosz Kwiatek[1,A-D] ✉, Stanisław Marczuk[1,A-D], Iryna Misiura[1,B-D], Paweł Szymonek[2,C-D], Justyna Wyroślak-Najs[3,E-F]

[1] *Students' Scientific Association, 2nd Chair and Department of General Gastrointestinal Surgery and Surgical Oncology of the Alimentary Tract, Medical University, Lublin, Poland*
[2] *Independent Public Health Care Facility, Lubartów, Poland*
[3] *2nd Chair and Department of General Gastrointestinal Surgery and Surgical Oncology of the Alimentary Tract, Medical University, Lublin, Poland*
A – Research concept and design, B – Collection and/or assembly of data, C – Data analysis and interpretation, D – Writing the article, E – Critical revision of the article, F – Final approval of the article

Kwiatek B, Marczuk S, Misiura I, Szymonek P, Wyroślak-Najs J. Metachronous breast and cervical cancers and subsequent IPMN of the pancreas in a premenopausal female patient – case report. J Pre-Clin Clin Res. doi:10.26444/jpccr/242753

Abstract

Metachronous multiple primary neoplasms remain a rare clinical phenomenon, particularly in young or premenopausal women. This report describes the case of a 45-year-old woman diagnosed with two distinct metachronous primary malignancies: invasive breast carcinoma, at age 39 (within the adolescent and young adult [AYA] age spectrum) and early-stage cervical carcinoma (FIGO stage IA2) at age 43. She subsequently underwent resection of a pancreatic lesion, histopathologically confirmed as an intraductal papillary mucinous neoplasm (IPMN) with low-grade dysplasia. Although multiple primary tumours strongly suggest underlying germline predispositions, genetic testing for BRCA1 and BRCA2 was negative. This case illustrates the need for sustained oncological surveillance and accurate differentiation between precursor lesions and invasive malignancies, highlighting that further genetic evaluation and management should be individualized based on the patient's full personal and family history.

Key words

breast neoplasms, multiple primary neoplasms, second primary neoplasms, pancreatic intraductal neoplasms, intraductal papillary mucinous neoplasms, uterine cervical neoplasms

INTRODUCTION AND OBJECTIVE

Multiple primary malignant neoplasms (MPMNs) are defined by the International Agency for Research on Cancer (IARC) as two or more independent primary malignancies arising in different tissues or organs. The occurrence of metachronous MPMNs remains uncommon, with reported incidence rates ranging from 2.3% – 5.8% among cancer survivors [3,4]. Although the patient presented in this report was 45 years old at the time of diagnosis of the pancreatic neoplasm, her first primary malignancy (breast cancer) was diagnosed at the age of 39 years, placing her within the upper age limit of the adolescent and young adult (AYA) oncology cohort according to National Cancer Institute criteria (15–39 years). Breast cancer represents one of the most prevalent malignancies diagnosed in this demographic and remains a leading cause of cancer-related mortality among young women [1,2].

The subsequent diagnosis of cervical carcinoma and later histopathological confirmation of intraductal papillary mucinous neoplasm (IPMN) of the pancreas represents a rare sequence of neoplastic diagnoses with limited representation in the literature, and frequently poses significant diagnostic and management challenges. While evidence suggests that women are more susceptible to developing multiple primary cancers, these subsequent malignancies typically manifest later in life [4,5].

The aim of the study is to present a rare chronological cascade of metachronous malignancies and a precursor pancreatic lesion in a young female patient, emphasizing the diagnostic challenges and the necessity of individualized patient management and long-term oncological surveillance.

CASE REPORT

In February 2025, a 45-year-old female patient was admitted to the Department of General Surgery for the management of a pancreatic lesion. Figure 1 summarizes the patient's extensive diagnostic and therapeutic history spanning over 12 years.

The patient's medical history began in 2013, when a pancreatic cyst was discovered incidentally during a routine examination and was initially managed with clinical observation. In August 2017, the patient presented with intensified pelvic pain and haematuria. An ultrasound revealed an ovarian cyst. She underwent laparoscopic marsupialization of a left hydrosalpinx, enucleation of a right ovarian cyst (53×36 mm), adhesiolysis, and ablation of endometriosis foci. Histopathological examination confirmed an endometrioma (chocolate cyst) of the right ovary, thereby establishing a definitive diagnosis of endometriosis. At that

✉ Address for correspondence: Bartosz Kwiatek, Students' Scientific Association, 2nd Chair and Department of General Gastrointestinal Surgery and Surgical Oncology of the Alimentary Tract, Medical University, Lublin, Poland
e-mail: bartosz@kwiatek.eu

Received: 03.09.2026; accepted: 09.11.2026; first published: 27.11.2026

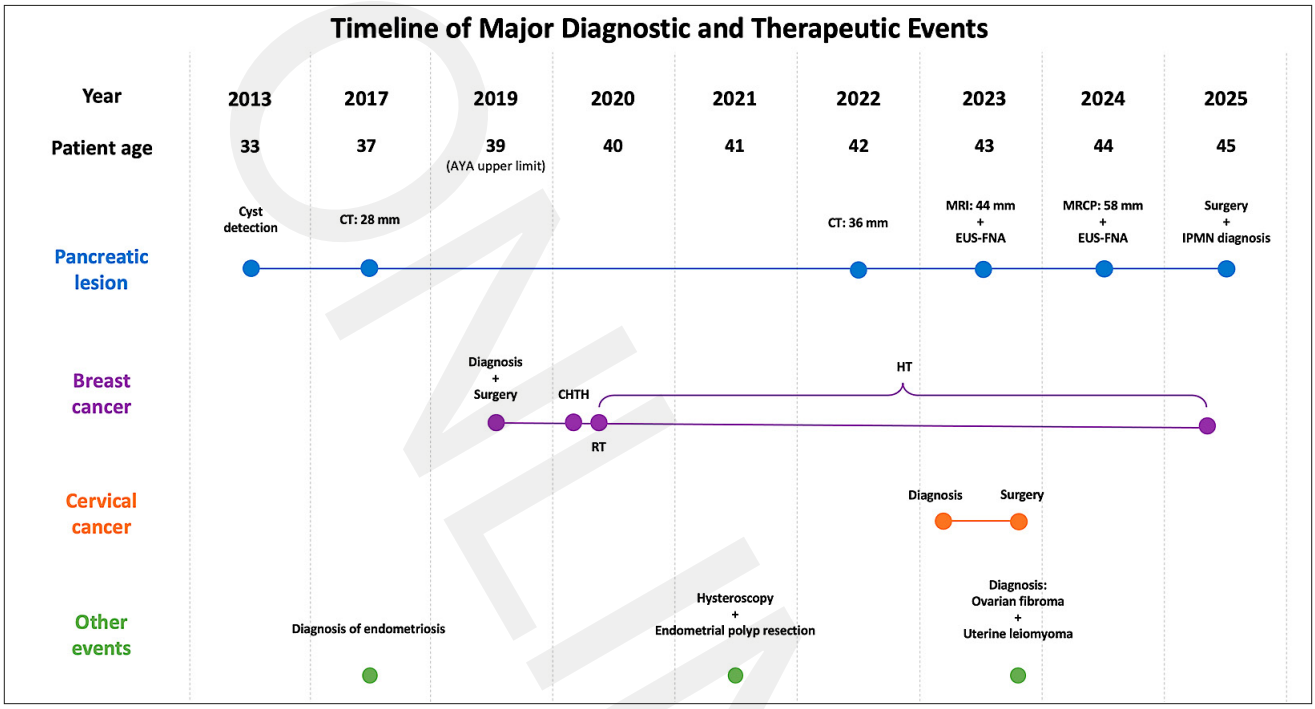

Figure 1. Timeline of Major Diagnostic and Therapeutic Events spanning over 12 years (2013–2025).
Abbreviations: **AYA** – adolescent and young adult; **CHTH** – chemotherapy; **CT** – computed tomography; **EUS-FNA** – endoscopic ultrasound-guided fine-needle aspiration; **HT** – hormone therapy; **IPMN** – intraductal papillary mucinous neoplasm; **MRI** – magnetic resonance imaging; **RT** – radiotherapy

time, a concurrent follow-up computed tomography (CT) scan noted that the known pancreatic tail cyst measured 28 mm.

Due to sentinel lymph node involvement, a completion axillary lymphadenectomy was performed. In 2020, the patient underwent systemic adjuvant chemotherapy comprising 2 cycles of the AC (doxorubicin and cyclophosphamide) regimen followed by 12 cycles of paclitaxel. This was complemented by intensity-modulated radiation therapy (IMRT) at a total dose of 45 Gy (delivered in 2.25 Gy fractions). Subsequently, adjuvant hormone therapy with tamoxifen was initiated. Tamoxifen therapy was maintained for a total duration of 5 years. During this period, specifically in December 2021, the patient underwent a hysteroscopy with resection of a benign endometrial polyp.

In 2022, a follow-up CT scan demonstrated progression of the pancreatic lesion, which had enlarged to 36×32 mm. Subsequently, in January 2023, abnormalities of the uterine cervix were detected during a routine gynaecological examination. This prompted a cervical conization with endocervical canal curettage, leading to a diagnosis of cervical cancer (FIGO stage IA2, pT1a NxMx R0). Prior to the definitive gynaecological intervention, a preoperative magnetic resonance imaging (MRI) scan was performed, which concurrently demonstrated further enlargement of the pancreatic tail lesion to 40×36×44 mm, alongside an area of diffusion restriction (14×11 mm) suggestive of a proliferative process.

Considering these imaging and clinical findings, the patient was qualified for a laparoscopically assisted vaginal hysterectomy (LAVH) with adnexal resection, which was carried out in June 2023. Postoperative histopathological examination revealed a right ovarian fibroma and a uterine leiomyoma. Notably, evaluation of the remaining ectocervical tissue demonstrated residual foci of a low-grade squamous intraepithelial lesion (LSIL) within the stratified squamous epithelium, and the surgical resection margins were clear. The endometrium showed no evidence of malignancy.

The progression and proliferative features of the pancreatic lesion observed on the 2023 MRI prompted further evaluation via endoscopic ultrasound (EUS), which revealed internal septations within the cyst. Subsequent endoscopic ultrasound-guided fine-needle aspiration (EUS-FNA) was performed. Fluid analysis demonstrated markedly elevated carcinoembryonic antigen (CEA) levels of 6,680 ng/mL (reference range: 0.0–5.2 ng/mL) and an amylase level of 635 IU/L (reference range: <250 IU/L), while fluid cultures remained sterile. Histopathological evaluation of the fluid showed proteinaceous masses, cellular elements of blood, and numerous macrophages; however, no epithelial cells were detected. The biopsy specimen from the cyst wall contained traces of proteinaceous material but lacked cellular diagnostic material for definitive evaluation. Of note, the patient had no prior history of pancreatitis or diabetes.

In September 2024, a follow-up EUS-FNA was performed; however, cytological evaluation failed to confirm malignancy. Subsequent magnetic resonance cholangiopancreatography (MRCP) revealed a fluid-filled lesion with internal septa, measuring 45×40×58 mm, with focal mural thickening (17×9 mm) in its superior component. No communication with the main pancreatic duct was identified. Although serum tumour markers (CA 125, CA 19–9, CEA, CA 15–3, CA 72–4, and HE4) were within normal limits, the markedly elevated cyst fluid CEA level, combined with these radiologically worrisome features, rendered the lesion highly suspicious for a malignant or premalignant process, strongly consistent with a mucinous cystic neoplasm (MCN).

In February 2025, due to the potential risk of malignancy, the patient underwent a laparoscopic distal pancreatectomy, splenectomy, and lymphadenectomy. Histopathological

examination of the surgical specimen confirmed an intraductal papillary mucinous neoplasm (IPMN) with low-grade dysplasia, demonstrating positive mucicarmine staining. All regional lymph nodes were negative for malignancy. The surgical procedure was completed without immediate complications. However, the early postoperative course was complicated by a transient episode of hypoglycaemia (54 mg/dL) and an asymptomatic fluid collection in the splenectomy bed. The patient was subsequently discharged in stable condition.

One week following hospital discharge, the patient presented with deteriorated clinical status and elevated inflammatory biomarkers. Empirical antibiotic therapy consisting of amoxicillin/clavulanic acid and metronidazole was initiated. During a follow-up assessment at the Department of General Surgery, a complete resolution of the inflammatory response was documented and verified by a control ultrasound examination.

Three months postoperatively, a follow-up EUS visualized a well-demarcated fluid collection. Active intervention or drainage was deferred due to the lack of a mature, well-formed wall and the high associated risk of peritonitis. At her last follow-up clinical assessment in June 2025, the patient was completely asymptomatic and remained under close surveillance, with an endoscopic cystogastrostomy deferred for future consideration if clinically indicated.

DISCUSSION

The occurrence of breast and cervical cancer in a relatively young patient raises the question of an underlying hereditary predisposition, but does not establish a shared genetic cause. The pancreatic lesion was diagnosed as an IPMN with low-grade dysplasia rather than pancreatic cancer, which is an important distinction when interpreting this combination of neoplasms. As described in the case history, the patient had undergone BRCA1/2 testing, which was reported as negative, and her grandmother had been diagnosed with colorectal cancer. These findings prompted consideration of a possible hereditary predisposition. However, the negative BRCA1/2 result should be interpreted in the context of the assay's scope and methodology, and does not exclude all hereditary cancer predispositions [15]. The single reported case of colorectal cancer in the family does not, on its own, establish a hereditary cancer syndrome. Lynch, Li–Fraumeni, and Cowden syndromes may be considered as possibilities warranting further evaluation, depending on a detailed assessment of the personal and family history. However, this report does not document confirmatory germline testing for these syndromes. Further genetic counselling and consideration of additional testing may be appropriate following an individual assessment of the age at breast cancer diagnosis, personal and family history, and previous testing. A hereditary predisposition therefore remains a possibility rather than an established explanation for the findings in this patient. The patient characteristics relevant to this assessment and the limitations of their interpretation are summarised in Table 1.

The patient reported a history of cigarette smoking and no previous pregnancies. These aspects of her history are relevant to the assessment of non-genetic risk factors. Smoking-related patterns of subsequent primary cancers have been described in population-based research [3], while reproductive factors, including age at first childbirth and breastfeeding, are relevant to breast cancer risk [6]. These observations provide context for risk assessment, but do not establish a common cause of her breast cancer, cervical cancer, and pancreatic IPMN.

The employment of the patient in the electronics industry and residence in an agricultural area also prompted consideration of possible occupational and environmental exposures. A nested case-control study among electrical manufacturing workers reported an association between chlorinated solvent exposure and breast cancer [8]. A meta-analysis identified associations between selected endocrine-disrupting chemicals and breast cancer, although results varied across compounds and studies [9]. In Poland, the Chief Inspectorate for Environmental Protection's 2018 report documented exceedances of permissible DDT concentrations

Table 1. Patient characteristics relevant to risk assessment and limitations of their interpretation

Domain	Information reported in this patient	Interpretation and limitations
Personal oncological history	Breast cancer, cervical cancer, and pancreatic IPMN with low-grade dysplasia.	The pancreatic lesion is a precursor neoplasm rather than a third primary malignancy. The coexistence of these lesions does not establish a shared etiology.
Genetic testing	BRCA1/2 testing was reported as negative.	Interpretation depends on the scope and methodology of testing. A negative result does not exclude all hereditary cancer predispositions [15]. No molecular confirmation of another hereditary cancer syndrome is presented in this report.
Family history	Colorectal cancer in the patient's grandmother.	This finding alone does not establish a hereditary cancer syndrome. Its relevance should be assessed within a detailed family history.
Reproductive history	No previous pregnancies were reported.	Reproductive history is relevant to breast cancer risk assessment [6], but this observation does not establish an individual cause or explain the coexistence of the three neoplasms.
Smoking history	A history of cigarette smoking was confirmed.	Smoking is relevant to the assessment of subsequent primary cancer risk [3]. However, its contribution to the neoplasms observed in this patient cannot be determined from this case report.
Occupational history	Employment in the electronics industry.	An association between chlorinated solvent exposure and breast cancer has been reported in electrical manufacturing workers [8]. Occupation alone does not establish the patient's exposure to solvents, cadmium, or other specific agents.
Residential and environmental history	Residence in an agricultural area.	Associations between selected environmental chemicals and cancer have been investigated [7,9], and Polish monitoring data document residual soil contamination [10]. These findings do not establish exposure at the patient's residence or a causal relationship with her neoplasms. Evidence concerning cadmium and pancreatic cancer [7] cannot be directly extrapolated to IPMN.

Note. Patient information is distinguished from associations reported in the literature. Population-level associations and environmental monitoring findings do not demonstrate individual exposure or causation. HPV infection is not listed because no confirmatory test result was available, this does not imply a negative HPV status. IPMN, intraductal papillary mucinous neoplasm; HPV, human papillomavirus

in 14 soil samples collected in 2015, with no exceedances reported for HCH [10]. These findings provide background for considering an exposure history; however, neither occupation nor residence alone demonstrates exposure in this patient. The available information does not identify specific agents, exposure intensity, or duration, therefore an environmental contribution remains hypothetical.

Cadmium exposure has also been associated with pancreatic cancer in a meta-analysis, although substantial heterogeneity limits interpretation of the pooled findings [7]. The patient's reported employment in the electronics industry prompted consideration of possible occupational exposure. However, employment in this industry alone does not establish cadmium exposure, which was not documented in this patient and remains hypothetical. Furthermore, the pancreatic lesion was an IPMN with low-grade dysplasia rather than pancreatic cancer, limiting the applicability of these findings to this case.

Cancer survivors may develop subsequent primary malignancies. In the SEER analysis covering 1973–2000, survivors had an overall 14% higher risk of a new malignancy than expected in the general population [11]. This population-level estimate should not be interpreted as an individual risk estimate, as the risk of subsequent cancers varies according to factors including age at first diagnosis, gender, and site of the initial malignancy [3,5]. Population-based studies have reported particularly elevated relative risks among survivors diagnosed at younger ages [3,5]. The presented patient was 39 years old at breast cancer diagnosis and therefore belonged to the AYA age group at the time of her first malignancy [6].

In a single-centre retrospective study, breast cancer was among the most common tumour sites in patients with multiple primary malignancies [12]. In the present case, the chronology and pathological nature of the lesions are important for interpreting their coexistence. The pancreatic cyst was detected before either cancer diagnosis and was ultimately classified as an IPMN with low-grade dysplasia, rather than a third primary malignancy. This case illustrates the importance of evaluating each lesion on its own clinical and pathological findings and maintaining appropriate follow-up of known abnormalities. It does not establish the benefit of additional screening for multiple malignancies in all young patients with cancer.

Although preoperative MRCP did not demonstrate communication between the cystic lesion and the main pancreatic duct, the diagnosis of IPMN was confirmed by histopathological examination of the resected specimen. MRI/MRCP is generally more sensitive than CT for detecting communication between pancreatic cystic neoplasms and the pancreatic ductal system; however, the visualization of such communication depends heavily on imaging quality and specific lesion characteristics. Therefore, the absence of demonstrable communication on MRCP does not, by itself, exclude an IPMN, and the definitive diagnosis must rely on the integration of clinical, radiological, and histopathological findings [16].

Because the lesion demonstrated focal mural thickening, the failure to obtain a representative sample of the cyst wall during EUS-FNA may explain why cytological evaluation did not detect neoplastic cells. The aspirated cyst fluid predominantly contained macrophages, proteinaceous material, blood cells, and cellular debris, without identifiable epithelial cells, which was consistent with the findings in our patient. Furthermore, in a complex, septated cystic lesion, the aspirated material may originate from a portion of the cyst that lacks diagnostic epithelial tissue.

Despite repeated EUS-FNA procedures, diagnostic epithelial cells were not obtained in the presented case. However, the progressive enlargement of the lesion, the presence of mural thickening, and the markedly elevated cyst-fluid CEA levels strongly raised suspicion of a mucinous neoplasm, thereby supporting the decision to proceed with surgical resection. Ultimately, the definitive diagnosis of IPMN was established upon histopathological examination of the resected specimen [17].

Beyond oncological follow-up, care for patients diagnosed with cancer at a young age should also address their psychosocial needs. Psychological distress in AYA cancer survivors [13] and difficulties involving mood, body image, and sexual functioning in younger breast cancer survivors [14], highlight the importance of attention to psychosocial needs during follow-up. However, psychological outcomes were not assessed in the information available for this case report.

CONCLUSIONS

This case describes breast and cervical cancer together with a pancreatic IPMN with low-grade dysplasia in a relatively young woman. It illustrates the importance of distinguishing malignant from precursor lesions and assessing each finding within the patient's clinical context. The available evidence does not establish a shared genetic or environmental cause. Consideration of further genetic evaluation and the planning of follow-up should be individualized according to personal and family history, previous testing, and the characteristics of each lesion. This single case does not justify universal expanded genetic testing or additional screening for multiple malignancies in all young patients with cancer.

REFERENCES

1. Wojciechowska U, Barańska K, Miklewska M, et al. Cancer incidence and mortality in Poland in 2020. Nowotwory J Oncol. 2023;73(3):129–145. https://doi.org/10.5603/NJO.2023.0026
2. Sung H, Ferlay J, Siegel RL, et al. Global cancer statistics 2020: GLOBOCAN estimates of incidence and mortality worldwide for 36 cancers in 185 countries. CA Cancer J Clin. 2021;71(3):209–249. https://doi.org/10.3322/caac.21660
3. Odani S, Tabuchi T, Nakata K, et al. Incidence and relative risk of metachronous second primary cancers for 16 cancer sites, Osaka, Japan, 2000–2015: population-based analysis. Cancer Med. 2022;11(2):507–519. https://doi.org/10.1002/cam4.4457
4. Kwon JH, Kim H, Lee JK, et al. Incidence and characteristics of multiple primary cancers: a 20-year retrospective study of a single cancer center in Korea. Cancers (Basel). 2024;16(13):2346. https://doi.org/10.3390/cancers16132346
5. Koivisto HAM, Nevala AO, Miettinen JM, et al. Relative risk of second malignant neoplasms highest among young adult cancer patients – a population-based registry study in Finland. Acta Oncol. 2024;63:418–425. https://doi.org/10.2340/1651-226x.2024.34138
6. Johnson RH, Anders CK, Litton JK, et al. Breast cancer in adolescents and young adults. Pediatr Blood Cancer. 2018;65(12):e27397. https://doi.org/10.1002/pbc.27397
7. Soleimani Y, Nayebi M, Mahmoudi S, et al. Cadmium exposure and risk of pancreatic cancer: systematic review and meta-analysis. PLoS One. 2025;20(4):e0319283. https://doi.org/10.1371/journal.pone.0319283
8. Oddone E, Edefonti V, Scaburri A, et al. Female breast cancer and electrical manufacturing: results of a nested case-control study. J Occup Health. 2014;56(5):369–378. https://doi.org/10.1539/joh.14-0034-oa

9. Liu H, Sun Y, Ran L, et al. Endocrine-disrupting chemicals and breast cancer: a meta-analysis. Front Oncol. 2023;13:1282651. https://doi.org/10.3389/fonc.2023.1282651
10. Chief Inspectorate for Environmental Protection, The state of the environment in Poland. Report 2018. Warsaw: Chief Inspectorate for Environmental Protection; 2018.
11. Curtis RE, Freedman DM, Ron E, Ries, et al., editors. New Malignancies Among Cancer Survivors: SEER Cancer Registries, 1973–2000. Bethesda, MD: National Cancer Institute; 2006.
12. Chirila DN, Turdeanu NA, Constantea NA, et al. Multiple malignant tumors. Chirurgia (Bucur). 2013;108(4):498–502.
13. Osmani V, Hörner L, Klug SJ, et al. Prevalence and risk of psychological distress, anxiety and depression in adolescent and young adult cancer survivors: a systematic review and meta-analysis. Cancer Med. 2023;12(17):18354–18367. https://doi.org/10.1002/cam4.6435
14. Champion VL, Wagner LI, Monahan PO, et al. Comparison of younger and older breast cancer survivors and age-matched controls on specific and overall quality of life domains. Cancer. 2014;120(15):2237–2246. https://doi.org/10.1002/cncr.28737
15. National Cancer Institute. Genetic Testing for Inherited Cancer Risk. https://www.cancer.gov/about-cancer/causes-prevention/genetics/genetic-testing-fact-sheet. Accessed September 19, 2026.
16. Henninger B, Steurer M, Plaikner M, et al. Magnetic resonance cholangiopancreatography with compressed sensing at 1.5 T: clinical application for the evaluation of branch duct IPMN of the pancreas. Eur Radiol. 2020;30(11):6014–6021. doi:10.1007/s00330-020-06996-2
17. European Study Group on Cystic Tumours of the Pancreas. European evidence-based guidelines on pancreatic cystic neoplasms. Gut. 2018;67(5):789–804. doi:10.1136/gutjnl-2018-316027

ONLINE FIRST