CASE REPORT

Journal of Pre-Clinical and Clinical Research
www.jpccr.eu

Co-occurrence of mosaic trisomy 12 and 21 as an extremely rare clinical phenomenon – case report

Ewelina Kawa[1,A-D], Katarzyn Skroban[1,A-D], Kamila Przyczyna[1,A-D], Paweł Zapolnik[2,A-C,E-F] ✉, Witold Błaż[2,A-C,E-F]

[1] *Students' Scientific Circle of Neonatology 'NeonatoUR', Collegium Medicum, University of Rzeszów, Rzeszów, Poland*
[2] *Department of Paediatrics, Collegium Medicum, University of Rzeszów, Rzeszów, Poland*
A – Research concept and design, B – Collection and/or assembly of data, C – Data analysis and interpretation, D – Writing the article, E – Critical revision of the article, F – Final approval of the article

Kawa E, Skroban K, Przyczyna K, Zapolnik P, Błaż W. Co-occurrence of mosaic trisomy 12 and 21 as an extremely rare clinical phenomenon – case report. J Pre-Clin Clin Res. doi:10.26444/jpccr/241389

Abstract

The case report concerns a male newborn with abnormal prenatal test results and a phenotype characteristic of chromosomal aberrations – trisomy 12 and 21. Diagnosis included prenatal aCGH analysis and amniocyte karyotype, as well as postnatal evaluation of blood lymphocytes and skin fibroblasts. Prenatal testing demonstrated the presence of trisomy 21. Amniocyte karyotyping revealed a male mosaic karyotype with two distinct cell lines: trisomy 12 and 21. Postnatal testing confirmed the finding. The infant exhibited multiple dysmorphic features. The most significant challenges involved the cardiovascular and respiratory systems, including congenital heart defects and severe pulmonary hypertension. This case highlights the crucial role of comprehensive diagnostics, particularly multi-tissue analysis. Managing complex chromosomal aberrations requires a highly individualized therapeutic approach. Documenting rare cases is essential for a better understanding of the clinical spectrum of such disorders.

Key words

trisomy 21, newborn, aneuploidy, mosaicism, trisomy 12

INTRODUCTION

Down Syndrome (DS) is a genetic disorder caused by the presence of an extra copy of human chromosome 21 [1]. DS is the most common non-lethal chromosomal aberration, occurring in approximately 1 in 1,000 live births. The mosaic form of trisomy 21 occurs in approximately 2% of patients diagnosed with trisomy 21 [2, 3]. Full trisomy of chromosome 12 is lethal and leads to spontaneous abortion in the first weeks of pregnancy. The mosaic form of this aneuploidy is a very rare defect (<0.2% of pregnancies) that can present a very diverse clinical picture – from no symptoms to severe heart defects or Potter syndrome. The craniofacial phenotype may encompass various dysmorphic traits, such as hypertelorism, epicanthus, low-set ears, an elongated nose, narrowed palpebral fissures, and a long philtrum. This pattern of trisomy occurs as a result of abnormal cell division or chromosome missegregation, which leads to the formation of a second cell line, resulting in a mosaic karyotype. The described case presents a unique situation of the coexistence of two distinct aneuploid lineages (T12 and T21) in a single patient.

✉ Address for correspondence: Paweł Zapolnik, Department of Paediatrics, Collegium Medicum, University of Rzeszów, Rzeszów, Kopisto 2a, 35-959 Rzeszów, Poland
E-mail: pawel.zapolnik@onet.pl

Received: 25.06.2026; accepted: 05.10.2026; first published:12.10.2026

CASE REPORT

Clinical presentation. A male newborn from the second pregnancy, first delivery, born at term by caesarean section (mother's neurological indications) in a good general condition, assessed for 7/9/9/9 points according to the Virginia Apgar scale with a birth weight of 3,500 g. Parents are not consanguineous; 28-year-old mother, suffering from multiple sclerosis, and 30-year-old healthy father (Fig. 1).

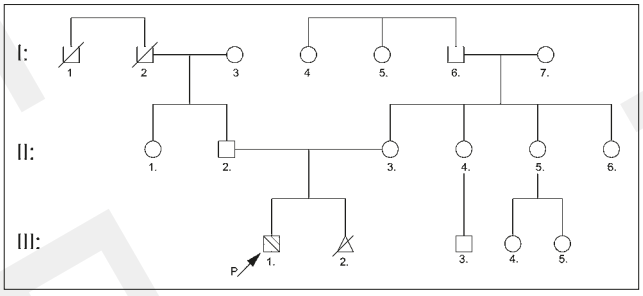

Figure 1. The family tree. The presence of the trisomy 21 is marked in the hatched box

Due to prenatal biochemical screening test results (of the I trimester) and an abnormal mid-pregnancy ultrasound scan (aberrant right subclavian artery), amniocentesis was performed. The array-based comparative genomic hybridisation (aCGH) test revealed an abnormal genotype of trisomy 21. Amniocyte karyotype analysis was also performed. Nine cells from one culture vessel showed an abnormal mosaic male karyotype with two cell lines: trisomy 12 (7/9 cells analysed) and trisomy 21 (2/9 cells analysed).



Figure 2. The proband's morphological phenotype: preaxial hexadactyly, syndactyly of the second and third toes of the right foot, a flat facial profile, and low-set ears

Following the abnormal prenatal screening and cytogenetic confirmation of mosaicism, the parents received multidisciplinary genetic counselling to discuss the diagnosis and anticipated clinical course of combined mosaic trisomy 12 and 21. Given the legal framework regarding pregnancy termination options in certain European jurisdictions, counselling focused on providing comprehensive psychosocial support, discussing the clinical prognosis, and planning specialized neonatal and paediatric management immediately upon delivery.

The patient had specific dysmorphic features, including: preaxial hexadactyly of the right hand (the additional thumb was surgically removed on the 37th day of life), syndactyly of the second and third toes on the right foot, a flat facial profile, epicanthal folds, upslanted palpebral fissure, flat nasal bridge, low-set ears, a single transverse palmar crease and cleft palate. (Fig. 2) Decreased muscle tone was observed, which is typical for trisomy 21.

In postnatal analysis, the karyotype of peripheral blood lymphocytes revealed only trisomy 21 (255 metaphases). However, cytogenetic examination of skin fibroblast culture confirmed mosaicism: trisomy 21 (24/30 cells) and trisomy 12 (6/30 cells).

The patient's main clinical problems included circulatory and respiratory issues – primarily pulmonary hypertension, which ultimately contributed to the patient's serious condition and need for a stay in the neonatal intensive care unit. The boy had experienced multiple crises of pulmonary hypertension treated with sildenafil, bosentan, milrinone and nitric oxide. An additional cardiac problem was caused by congenital heart defects, including: ventricular septal defects (multiple VSDs), an atrial septal defect (ASD II), a patent

ductus arteriosus (PDA) and an aberrant right subclavian artery (ARSA). Due to the patient's primary pulmonary hypertension and a persistently patent ductus arteriosus with predominantly left-to-right shunting, an unusual phenomenon was observed: the coexistence of pre- and post-capillary pulmonary hypertension phenotypes. To reduce shunting, cardiac catheterisation was performed on day 36 of life, with closure of the PDA using a Piccolo Amplatzer occluder. The patient's condition improved, but the residual pulmonary hypertension still required pharmacotherapy (sildenafil, bosentan, spironolactone, furosemide).

Another factor complicating the course of hospitalisation was the presence of infections – bacterial respiratory tract infections (*Klebsiella pneumoniae, Staphylococcus aureus*) and viral gastrointestinal infections (rotaviruses, noroviruses). Following targetted antibiotic therapy and symptomatic treatment, the patient's condition stabilised; however, persistent chronic atelectatic and inflammatory changes in the lungs necessitated mechanical ventilation. Ventilatory de-escalation to non-invasive ventilation and, finally, oxygen treatment was protracted and involved the administration of systemic glucocorticoids in the form of methylprednisolone pulses. Due to the necessary analgesic and sedative treatment associated with prolonged mechanical ventilation and intensive care procedures, the weaning process resulted in the onset of withdrawal symptoms, which were managed with oral replacement therapy.

On the 95th day, the boy was discharged for care of in a home hospice with continuous access to oxygen therapy.

DISCUSSION

The co-occurrence of mosaic trisomy 21 and 12 is an extremely rare phenomenon. The literature reports only a few dozen cases of mosaic trisomy 12, which often present with hexadactyly and organ malformations. A clinically significant finding is the absence of a cell line with an extra chromosome 12 in the peripheral blood, whilst it is preserved in skin fibroblasts.

Cytogenetic testing revealed the presence of 2 abnormal cell lines. One was found to have a simple trisomy of chromosome 21, and the other a trisomy of chromosome 12, indicating a mosaic trisomy of chromosomes 21 and 12. To the best of the authors' knowledge, approximately 25 cases of mosaic trisomy 12 diagnosed post-natally have been reported to date, and the global incidence of Down syndrome is estimated at 1 in 1,000 live births, whereas mosaic trisomy of chromosome 21 accounts for 1–2% of cases of the Down Syndrome population [4, 5, 6]. This makes the present clinical case report one of the few publications of its kind in the international literature. This leads to the conclusion that the cytogenetic constellation described here is a case report of extremely low incidence.

Prenatal diagnosis of rare and complex chromosomal aberrations presents profound bioethical and clinical challenges. In several European jurisdictions, statutory restrictions on pregnancy termination limit parental choice following a prenatal diagnosis of severe anomalies. In such healthcare contexts, genetic counselling must pivot toward preparing families both psychologically and logistically for the delivery of an infant with a guarded prognosis, ensuring coordinated perinatal palliative and neonatological care.

The presented case report is notable for its complex phenotype, exhibiting features common to trisomy of chromosomes 12 and 21. The co-occurrence of characteristics typical of both conditions is not simply the sum of the symptoms of both syndromes. There are an accumulation of developmental defects and an atypical dysmorphic presentation, which consequently makes diagnosis significantly more difficult.

Such aneuploidies make it difficult to predict the clinical course and prognosis. Double aneuploidy may predispose patients to the more rapid development of comorbidities, due to genetic instability. Tissue mosaicism can vary in severity across different tissues, meaning that a peripheral blood test does not allow a complete assessment of its distribution. Several factors may cause this situation. This form of mosaicism is characteristic for certain genetic aberrations and underscores the importance of testing multiple tissues in the diagnosis of rare genetic syndromes [6].

An additional factor preventing accurate prediction of the clinical course is the rarity of trisomy 12. This situation is compounded by the fact that, to the best of the authors' knowledge, the co-occurrence of mosaic trisomy 12 and 21 has not yet been described in the medical literature.

Trisomy 21 is the most common autosomal aneuploidy observed in live-born children and one of the most genetically complex aneuploidies compatible with post-natal survival. Up to 75% and 50% of foetuses with DS identified in the first and second trimesters of pregnancy, respectively, are lost before term, therefore the prevalence of Down syndrome is significantly higher at the time of conception [7].

The phenotype of a patient with Down syndrome includes characteristic facial dysmorphic features, intellectual disability and psychomotor developmental delay. Newborns often present muscular hypotonia, reduced brain volume, joint laxity and atypical dermatoglyphic features. Heart defects and gastrointestinal abnormalities, such as Hirschsprung's disease and duodenal atresia, are also frequently observed. Patients are at increased risk of haematological and thyroid disorders, and a faster progression of Alzheimer's disease also observed, with symptoms typically emerging in patients in their forties [8,9].

In the present case, the patient exhibited numerous phenotypic features characteristic of mosaic trisomy 21, including a flat facial profile, up-slanted palpebral fissures, epicanthal folds, a depressed nasal bridge, low-set ears, and complex congenital heart defects, specifically a ventricular septal defect (VSD), atrial septal defect type II (ASD II), patent ductus arteriosus (PDA), and an aberrant right subclavian artery (ARSA) [7].

Trisomy 12 is a rare aneuploidy, and foetuses with this condition tend to be spontaneously miscarried. However, mosaicism allows this anomaly to manifest in live births [10] presenting with a wide range of phenotypes, and predicting the severity of the abnormality is extremely difficult. Mosaicism of trisomy 12 detected pre-natally in amniotic fluid may not be detectable post-natally, and an additional difficulty arises from the fact that, even if it is not confirmed in one tissue, it may still be present in other tissues of the child [11].

At the phenotypic level, mosaic trisomy 12 encompasses patients with an apparently normal phenotype, as well as patients with short stature, hypotonia, microcephaly, developmental delay, dysmorphic facial features such as

epicanthal folds, a broad nasal bridge and low-set ears, congenital heart defects, abnormalities of the distal limbs and pigmentary mosaicism [5]. In the present case, typical clinical features of the condition were observed, including right-foot toe syndactyly, hexadactyly of the right hand, a ventricular septal defect, epicanthal folds, and a depressed nasal bridge.

The presented case of a patient with mosaic trisomy of chromosomes 21 and 12 demonstrates a complex clinical picture that is difficult to interpret unequivocally. The co-occurrence of two chromosomal aberrations may account for significant phenotypic variability, thereby complicating the assessment of prognosis, the prediction of disease progression, and the selection of treatment. [11]

Given the unique nature of the described aberration and the methodological limitations, this case report should not be regarded as relevant clinical guidance, but rather as a valuable resource in the diagnostic process.

CONCLUSIONS

1) **Role of post-natal diagnosis.** Mosaicism identified in prenatal testing must always be verified post-natally to confirm the mosaicism with a high degree of certainty, or to rule out a false-positive result caused by the collection of cells derived from the trophoblast.
2) **Tissue-specific diagnosis.** The presented case demonstrates that, when diagnosing rare genetic syndromes, it is essential to analyse different cell lines, as the absence of an additional aneuploid line in one tissue type does not rule out its presence in other tissues within the body, which could lead to an incomplete diagnosis.
3) **Impact of double aneuploidy on prognosis.** The coexistence of two aneuploid lines (T12 and T21) may significantly contribute to a more complex clinical course than is seen in cases of isolated trisomy 21. The accumulation of heart defects and the treatment-resistant, persistent pulmonary hypertension in the described patient suggest that the presence of an additional cell line may significantly influence the general condition and progression of symptoms.
4) **Importance of specialist care.** Every case of complex chromosomal aberration warrants genetic counselling to the patient's family in order to tailor the treatment process, assess the risk of recurrence, and ensure appropriate support, such as hospice care, psychological aid and support groups.
5) **Value of non-invasive and invasive tests.** Properly conducted prenatal screening (clinical examination, with particular emphasis on family history, ultrasound, and biochemical tests) remains a key tool enabling the early identification of high-risk groups and the implementation of targeted invasive diagnostics, which is of fundamental importance for optimising perinatal care.
6) **Variability of phenotypic features.** The systematic documentation of cases of trisomy 12 is of significant importance, as it enables a better understanding of the clinical presentation and the variability of phenotypic features. The accumulation of such observations helps to raise awareness within the medical community and facilitates a thorough analysis of the clinical presentation, thereby aiding diagnosis.

Acknowledgement

The authors express their thanks to the parents of the patient for their participation, patience and support during the diagnosis and therapeutic process,

REFERENCES

1. Korenberg JR, Chen XN, Schipper R, Sun Z, Gonsky R, Gerwehr S, et al. Down syndrome phenotypes: the consequences of chromosomal imbalance. Proc Natl Acad Sci U S A. 1994;91(11):4997–5001. doi:10.1073/pnas.91.11.4997
2. World Health Organization Regional Office for Europe. Births with Down's syndrome per 100 000 live births. https://gateway.euro.who.int/en/indicators/hfa_603-7120-births-with-downs-syndrome-per-100-000-live-births/ (access: 2026.03.23).
3. Rubenstein E, Tewolde S, Skotko BG, Michals A, Fortea J. Occurrence of mosaic Down syndrome and prevalence of co-occurring conditions in Medicaid enrolled adults, 2016–2019. Am J Med Genet C Semin Med Genet. 2024;196(4):e32097. doi:10.1002/ajmg.c.32097
4. Pal A, Daley SF. Down syndrome. https://www.ncbi.nlm.nih.gov/books/NBK526016/ (access: 2026.03.23).
5. Martínez-Hernández A, Martínez-Anaya D, Durán-McKinster C, Del Castillo-Ruiz V, Navarrete-Meneses P, Córdova EJ, et al. Pigmentary mosaicism as a recurrent clinical manifestation in three new patients with mosaic trisomy 12 diagnosed postnatally: cases report and literature review. BMC Med Genomics. 2022;15(1):224. doi:10.1186/s12920-022-01382-x
6. Senkeviciute G, Dagytė E, Sliužas V, Morkūnienė A, Kučinskas V. Mosaic trisomy 12 – A case of a rare phenotypic association and literature review. Brain Dev Case Rep. 2025;3:100058. doi:10.1016/j.bdcr.2024.100058
7. Antonarakis SE, Skotko BG, Rafii MS, Strydom A, Pape SE, Bianchi DW, et al. Down syndrome. Nat Rev Dis Primers. 2020;6(1):9. doi:10.1038/s41572-019-0143-7
8. Lao PJ, Gutierrez J, Keator D, Rizvi B, Banerjee A, Igwe KC, et al. Alzheimer-Related Cerebrovascular Disease in Down Syndrome. Ann Neurol. 2020;88(6):1165–1177. doi:10.1002/ana.25905
9. Marderstein AR, De Zuani M, Moeller R, Bezney J, Padhi EM, Wong S, et al. Single-cell multi-omics map of human fetal blood in Down syndrome. Nature. 2024;634(8032):104–112. doi:10.1038/s41586-024-07946-4
10. Roberts W, Zurada A, Zurada-Zielińska A, Gielecki J, Loukas M. Anatomy of trisomy 12. Clin Anat. 2016;29(5):633–637. doi:10.1002/ca.22726
11. Hainz D, Krüger M, Reber D, Mehnert K, Brunet T, Lederer G, et al. Mosaic trisomy 12 diagnosed in a female patient: clinical features, genetic analysis, and review of the literature. World J Pediatr. 2021;17(4):438–448. doi:10.1007/s12519-021-00438-9