CASE REPORT

Journal of Pre-Clinical and Clinical Research 2026, Vol 20, No 3, 137–140
www.jpccr.eu

The battle for life – an infant with ALCL and haemophagocytosis

Karolina Mazur[1,A-D,F] ✉, Natalia Olbrot[1,A-D,F], Kamila Krycia[1,A-D], Maciej Dubaj[2,A-D], Małgorzata Mitura-Lesiuk[2,A-B,D-E]

[1] *Student Scientific Association,Department of Paediatric Haematology, Oncology and Transplantology, Medical University, Lublin, Poland*
[2] *Department of Paediatric Haematology, Oncology and Transplantology, Medical Univesity, Lublin, Poland*
A – Research concept and design, B – Collection and/or assembly of data, C – Data analysis and interpretation, D – Writing the article, E – Critical revision of the article, F – Final approval of the article

Mazur K, Olbrot N, Krycia K, Dubaj M, Mitura-Lesiuk M. The battle for life – an infant with ALCL and haemophagocytosis. J Pre-Clin Clin Res. 2026;20(3):137–140. doi:10.26444/jpccr/226611

Abstract

Anaplastic large cell lymphoma (ALCL) is a rare paediatric non-Hodgkin lymphoma. Its course can be complicated by haemophagocytic lymphohistiocytosis (HLH), a severe hyperinflammatory syndrome. The case is presented of a 2-year-old boy with ALCL and secondary HLH, to highlight the treatment course and complications. The boy initially presented with upper respiratory symptoms and cervical lymphadenopathy; biopsy confirmed ALCL. Initial complications during the ALCL 99 Program were managed, allowing treatment to continue. A few months later, he was readmitted with fever, pancytopenia, elevated ferritin, hypertriglyceridaemia, and hepatosplenomegaly. These symptoms led to an HLH diagnosis overlapping the previously diagnosed ALCL. Despite treatment in the ICU, multi-organ failure occurred leading to death. Secondary HLH significantly worsens the ALCL clinical course. Poor outcomes despite standard HLH-directed therapies emphasize the critical need for earlier recognition and more effective strategies.

Key words

ALCL, HLH, treatment, diagnostic

INTRODUCTION

Anaplastic large cell lymphoma (ALCL) is a rare subtype of non-Hodgkin lymphoma in children, characterized by the proliferation of CD30-positive lymphoid cells and frequent expression of anaplastic lymphoma kinase (ALK). It accounts for approximately 5–20% of paediatric non-Hodgkin lymphomas and most commonly presents as systemic disease in this population [1]. ALCL typically involves peripheral lymph nodes but may also affect extranodal sites. Systemic symptoms such as fever are present in the majority of patients [2, 3].

In some cases, the clinical course of ALCL may be complicated by the development of haemophagocytic lymphohistiocytosis (HLH), a severe hyperinflammatory syndrome associated with excessive immune activation [4]. The coexistence of these conditions poses a significant diagnostic challenge due to overlapping clinical features, including persistent fever, cytopenias, and organomegaly, which may delay recognition of HLH.

Clinical deterioration in such patients may result not only from lymphoma progression but also from uncontrolled hyperinflammation, which complicates both diagnosis and treatment.

The case is presented of a 2-year-old boy diagnosed with systemic ALCL, complicated by haemophagocytic syndrome.

✉ Address for correspondence: Karolina Mazur, Student Scientific Association, Department of Paediatric Haematology, Oncology and Transplantology, Medical University, Lublin, Poland
E-mail: karolinamazur023@gmail.com

Received: 30.06.2026; accepted: 30.07.2026; first published: 25.08.2026

CASE REPORT

A 2-year-old boy was admitted to the infectious diseases ward with suspected infectious mononucleosis, presenting with upper respiratory tract symptoms and right-side cervical lymphadenopathy. The reason for hospitalization was an unsatisfactory response to antibiotic treatment in an outpatient setting. During hospitalization, the progression of nodal lesions was observed with the appearance of fever >38.5 degrees Celsius. After a few days, the boy was referred to the Department of Haematology, Oncology and Paediatric Transplantology for the diagnosis of increasing lymphadenopathy. On admission, the boy was in a good general condition, and haemodynamically stable. Physical examination of the deviations revealed the following: enlarged cervical lymph nodes on the right side, which formed a hard, non-movable package measuring 5 × 8 cm which changed the contour of the neck, an enlarged spleen, and a few café au lait spots on the skin. During hospitalization, further progression of nodal lesions was observed, manifested by enlargement of the cervical lymph nodes on the left side and progression in the size of the spleen, accompanied by fever above 39 degrees Celsius. Computed tomography of the chest (Fig. 1, Fig. 2) and neck (Fig. 3) revealed hilar thickening within the lungs and nodal mass, extending from the angle of the mandible to the right supraclavicular region (package 5 × 3,6, 6.10 cm), with the largest lesion measuring 33 × 24 × 22 mm, on the left side (33 × 24 × 22 mm), and in the mediastinum and supraclavicular area. Abdominal ultrasound revealed the presence of enlarged abdominal lymph nodes. The decision was made to perform a biopsy of the node. Histopathological examination diagnosed anaplastic large cell lymphoma (ALCL), ALK1+ (Hodgkin-like pattern) with a Ki-67 index



Figure 1. CT of the chest – interstitial window. Visible enlargement of the mediastinal lymph nodes

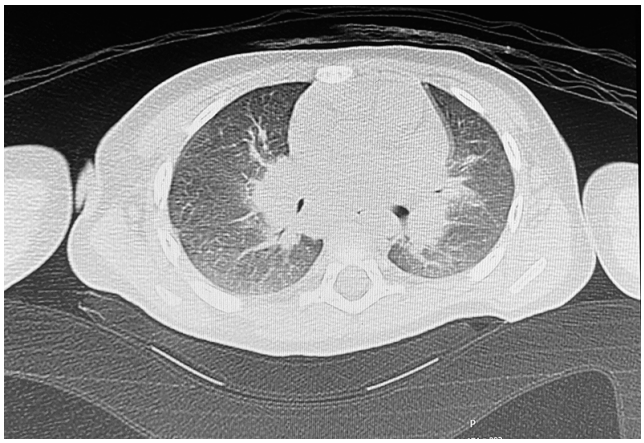

Figure 2. CT of the chest – pulmonary window. Visible thickening in the hilar area and enlargement of mediastinal lymph nodes



Figure 3. CT scan of the neck. Enlarged cervical lymph nodes

of 90%. Trepanobiopsy confirmed the presence of cancer cells in the bone marrow (CD30+, ALK1+).

On the basis of additional tests, the supraclavicular and subclavian areas as well as the bone marrow were affected. Therefore, the boy's stage of the disease was determined as IV.

It was decided to start therapy according to the ALCL 99 Programme. As a result of the treatment (prophase and AM1 course), a number of complications arose, including: bone marrow aplasia, febrile neutropenia and fluid and electrolyte disturbances with symptomatic hyponatraemia. The boy's condition improved due to actions taken, including, among others, transfusion of blood products, compensation of water and electrolyte disorders and broad-spectrum antibiotic

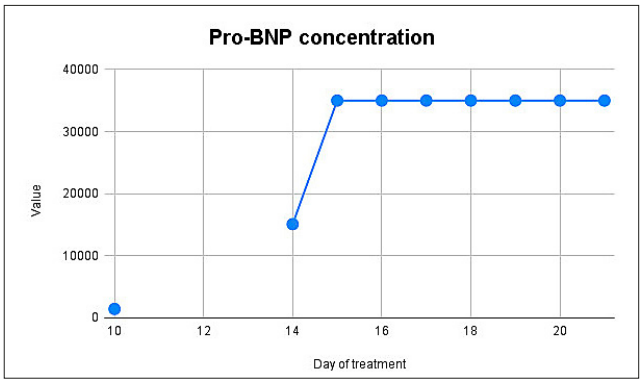

Figure 4. Pro-BNP concentration

therapy. Treatment (BM1 course) was continued as planned. Eleven days after the start of the course, the boy was admitted, unscheduled, due to an increase in the concentration of inflammatory parameters. In the following days, due to the lack of response to the previous treatment and hectic fever, it was decided that antibiotic therapy had to be intensified.

On the 12th day of hospitalization, critical pro-BNP values (Fig. 4) and redness of the skin with swelling located on the lower limbs and in the sacrolumbar region were observed, as well as an increase in abdominal circumference. The patient developed pancytopenia, elevated ferritin levels, hypertriglyceridaemia and hepato-splenomegaly, and the fever persisted. In addition, laboratory tests showed high values of inflammatory parameters (CRP) and liver function disorders. Based on the clinical presentation and laboratory findings, haemophagocytic lymphohistiocytosis was suspected.

Therefore, it was decided to include steroids and ciclosporin in the treatment and to administer Etoposide, according to the HLH treatment regimen. Despite treatment, the patient's condition worsened. On the 17th day of hospitalization, there were signs of cardiorespiratory failure and severe epidermal creep. Despite the inclusion of catecholamines in the therapy, the patient's condition deteriorated significantly. The boy was transferred to the Department of Anaesthesiology and Intensive Care. Due to the increase in features of multi-organ failure (deterioration of morphological parameters monitored by a haemodynamic platform) and sepsis, the boy was intubated, corotrope and catecholamine infusions were applied; haemodynamic treatment was continued. Despite intensive care, no clinical improvement was observed. Multi-organ failure progressed, and the patient died on the seventh day of ICU hospitalization.

DISCUSSION

ALCL is a distinct subtype of peripheral T-cell lymphoma characterized by uniform CD30 expression and, in paediatric patients, frequent *ALK* gene rearrangement resulting in constitutive kinase activation [5–7]. ALK-positive ALCL predominates in children and is generally associated with a favourable prognosis compared to ALK-negative disease [6]. The oncogenic *NPM-ALK* fusion protein activates signalling pathways such as JAK/STAT3 and PI3K/Akt, promoting proliferation and cytokine production, which may contribute not only to tumour growth, but also to systemic immune dysregulation.

Although ALK-positive status confers improved long-term survival in most paediatric patients, the presented case illustrates that this prognostic advantage may be rapidly negated by the development of haemophagocytic lymphohistiocytosis (HLH). HLH is a hyperinflammatory syndrome characterized by uncontrolled activation of cytotoxic T lymphocytes and macrophages, excessive secretion of pro-infammatory cytokines (including IFN-γ, IL-6, IL-10, TNF-α), and progressive multi-organ dysfunction [8, 9]. Increasing evidence indicates that the pathophysiology of HLH reflects a failure of immune homeostasis, particularly impaired cytotoxic function leading to sustained antigenic stimulation and cytokine amplification.

HLH is classified as primary (genetic) or secondary (acquired). Primary HLH typically presents in early childhood, with a median age of onset of approximately 1.8 years, and is associated with mutations in genes regulating cytotoxic granule exocytosis, such as *PRF1*, *STXBP2*, *UNC13D* (*MUNC13–4*), and *STX11* [10, 11]. Secondary HLH may be triggered by infections, autoimmune diseases, or malignancies [8, 10]. In paediatric cohorts, malignancy-associated HLH accounts for a minority of cases – approximately 8.4% according to available data – but carries disproportionately high mortality [12].

The diagnosis of HLH is established either by identification of a pathogenic mutation consistent with HLH, or by fulfilling at least five of eight diagnostic criteria defined in the HLH-2004 protocol [13, 9]. These criteria include fever, splenomegaly, cytopenia affecting at least two haematopoietic lineages, hypertriglyceridaemia (≥265 mg/dL) and/or hypofibrinogenaemia (≤1.5 g/L), hyperferritinaemia (≥500 µg/L), haemophagocytosis in bone marrow, spleen or lymph nodes, low or absent NK-cell activity, and elevated soluble CD25 (sIL-2 receptor) levels (≥2400 U/mL) [13, 9].

The presented patient fulfilled at least five of the criteria, including persistent fever, splenomegaly, cytopenia affecting two lineages, hypertriglyceridaemia, and markedly elevated ferritin levels, thereby meeting diagnostic requirements for HLH. Although genetic testing for primary HLH-associated mutations was not performed, the clinical presentation strongly suggested secondary HLH triggered by ALCL. However, given the young age of the patient, an underlying genetic predisposition cannot be definitively excluded [10, 11].

Malignancy-associated HLH is well described in adults, particularly in association with T-cell and NK-cell lymphomas, but remains rare in the paediatric population. Available literature consists mainly of case reports and small series. Lackner et al. reported six children with malignancy-associated HLH, three of whom died shortly after diagnosis [14]. Mann et al. described a fatal case of ALCL complicated by HLH despite intensive therapy [15]. Similarly, Sahoo et al. documented paediatric ALCL cases with concomitant HLH and poor outcomes [16]. These reports suggest that the development of HLH significantly worsens prognosis in children with ALCL.

Larger paediatric HLH cohorts further emphasize the severity of this condition. Li et al. reported a 30-day mortality rate of 28.8% among 160 paediatric HLH patients, with 11.3% dying within the first week of diagnosis [17]. Zhang et al. demonstrated a 30-day mortality rate of 30.9% in a cohort of 110 children [18]. A meta-analysis by Tan et al., including 493 patients, estimated overall HLH mortality at 32.6%, with significantly worse outcomes observed in malignancy-associated HLH, compared to infection-triggered forms [19]. These data underscore the aggressive nature of HLH, particularly when associated with underlying malignancy.

Importantly, accumulating clinical evidence suggests that in lymphoma-associated HLH, hyperinflammation rather than lymphoma progression *per se* constitutes the principal determinant of early mortality [20]. This concept is strongly supported by the current case. Despite initiation of treatment according to the HLH-2004 protocol – including corticosteroids, etoposide, and cyclosporine – the patient developed progressive hepatosplenomegaly, liver dysfunction, and multi-organ failure.

The fulminant course suggests that once a critical threshold of immune activation is exceeded, the inflammatory cascade may become self-propagating and refractory to standard immunochemotherapy. This observation raises important therapeutic considerations. The HLH-2004 protocol remains the standard of care; however, outcomes in malignancy-associated HLH remain suboptimal [8, 21]. Emerging therapeutic strategies targeting specific inflammatory mediators – such as IFN-γ blockade or JAK inhibition – have shown promise in selected HLH populations, although their role in lymphoma-associated HLH requires further investigation. Given the mechanistic involvement of JAK/STAT signalling in ALK-positive ALCL, targetted pathway inhibition may theoretically provide dual anti-tumour and anti-inflammatory effects, representing a potential avenue for future research.

Another clinically relevant issue is diagnostic timing. The overlap of HLH features with systemic lymphoma manifestations – fever, cytopenias, hepatosplenomegaly, elevated inflammatory markers – may obscure recognition of HLH and delay appropriate immunosuppressive therapy [8, 9]. Early measurement of ferritin and triglyceride levels in paediatric patients with ALCL who demonstrate rapid clinical deterioration, may facilitate earlier identification of HLH and potentially improve outcomes. The current case reinforces the concept that malignancy-associated HLH should be regarded not as a coincidental comorbidity, but as a biologically integrated hyperinflammatory complication of lymphoma. In ALK-positive ALCL, oncogenic signalling may paradoxically create a pro-infammatory milieu capable of precipitating life-threatening immune dysregulation. Thus, the favourable prognostic implication of ALK positivity may be overridden by the emergence of HLH, which becomes the dominant driver of mortality.

Although ALK-positive ALCL in children is generally associated with favourable survival, the development of HLH fundamentally alters the disease trajectory and confers high risk of early mortality. Given the rarity of paediatric ALCL complicated by HLH, the current evidence base remains limited to small series and case reports. Prospective multi-centre data are urgently needed to clarify risk factors, identify early biomarkers of impending hyperinflammation, and optimize integrated therapeutic strategies addressing both malignant proliferation and immune dysregulation

CONCLUSIONS

The presented case demonstrates that the development of secondary HLH may significantly worsen the clinical course and become the primary determinant of early mortality.

Due to the overlap between lymphoma-related symptoms and HLH manifestations, early diagnosis requires a high index of suspicion and careful monitoring of laboratory parameters, particularly ferritin, triglycerides, and cytopenias.

The authors' observations suggest that in malignancy-associated HLH, uncontrolled hyperinflammation rather than lymphoma progression may drive rapid deterioration. Despite the use of standard HLH-directed therapy, outcomes remain poor, highlighting the need for earlier recognition and more effective treatment strategies targeting both the underlying malignancy and immune dysregulation.

REFERENCES

1. Agrusa JE, Egress ER, Lowe EJ. Brentuximab vedotin use in pediatric anaplastic large cell lymphoma. Front Immunol. 2023;14:1203471.
2. Rigaud C, Knörr F, Brugières L, et al. Diagnosis and management of ALK-positive anaplastic large cell lymphoma in children and adolescents. Best Pract Res Clin Haematol. 2023;36:101444.
3. Khoubila N, Sraidi S, Madani A, et al. Anaplastic large-cell lymphoma in children: state of the art in 2023. J Pediatr Hematol Oncol. 2024;46:217–224.
4. Aksu T, Bayhan T, Gülhan B, et al. Children with lymphoma presenting with hemophagocytic lymphohistiocytosis. Turk J Pediatr. 2020;62:284–288.
5. Chen Z, Chai F, Xi Y, et al. Aberrant expression and genetic alteration of c-MYC in anaplastic large cell lymphoma. J Cancer Res Clin Oncol. 2022;148:267–278.
6. Shustov A, Soma L. Anaplastic large cell lymphoma: contemporary concepts and optimal management. Cancer Treat Res. 2019;176:127–144.
7. Nizamuddin I, Galvez C, Pro B. Management of ALCL and other CD30+ peripheral T-cell lymphomas with a focus on brentuximab vedotin. Semin Hematol. 2021;58:85–94.
8. Canna SW, Marsh RA. Pediatric hemophagocytic lymphohistiocytosis. Blood. 2020;135(16):1332–1343. doi:10.1182/blood.2019000936
9. Chinnici A, Beneforti L, Pegoraro F, et al. Approaching hemophagocytic lymphohistiocytosis. Front Immunol. 2023;14:1210041.
10. Ponnatt TS, Lilley CM, Mirza KM. Hemophagocytic lymphohistiocytosis. Arch Pathol Lab Med. 2022;146:507–519.
11. Griffin G, Shenoi S, Hughes GC. Hemophagocytic lymphohistiocytosis: an update on pathogenesis, diagnosis, and therapy. Best Pract Res Clin Rheumatol. 2020;34:101515.
12. Kaçar AG, Celkan TT. Hemophagocytic lymphohistiocytosis. Balkan Med J. 2022;39:309–317.
13. Canna SW, Marsh RA. Pediatric hemophagocytic lymphohistiocytosis. Blood. 2020;135:1332–1343.
14. Lackner H, Urban C, Sovinz P, et al. Hemophagocytic lymphohistiocytosis as severe adverse event of antineoplastic treatment in children. Haematologica. 2008;93(2):291–294. doi:10.3324/haematol.11704
15. Mann G, Gadner H. Comment on HLH in a child with anaplastic large cell lymphoma (ALCL). J Pediatr Hematol Oncol. 2008;30(10):721–722. doi:10.1097/MPH.0b013e318182e789
16. Sahoo D, Gupta AK, Wajid MA, et al. Clinical presentation and outcomes of pediatric anaplastic large cell lymphoma: a tertiary center experience from India. Indian J Cancer. Published online August 9, 2023. doi:10.4103/ijc.IJC_368_20
17. Li X, Yan H, Zhang X, et al. Clinical profiles and risk factors of 7-day and 30-day mortality among 160 pediatric patients with hemophagocytic lymphohistiocytosis. Orphanet J Rare Dis. 2020;15(1):229. doi:10.1186/s13023-020-01515-4
18. Zhang L, Dai L, Li D. Risk factors of early death in pediatric hemophagocytic lymphohistocytosis: retrospective cohort study. Front Pediatr. 2022;10:1031432. doi:10.3389/fped.2022.1031432
19. Tan CJ, Ng ZQ, Bhattacharyya R, et al. Treatment and mortality of hemophagocytic lymphohistiocytosis in critically ill children: a systematic review and meta-analysis. Pediatr Blood Cancer. 2023;70(3):e30122. doi:10.1002/pbc.30122
20. Jordan MB, Allen CE, Weitzman S, et al. How I treat hemophagocytic lymphohistiocytosis. Blood. 2011;118(15):4041–4052. doi:10.1182/blood-2011-03-278127
21. Ariffin H. Incorrigible inflammation. Br J Haematol. 2024;205(5):1679–1680. doi:10.1111/bjh.19773