CASE REPORT

Journal of Pre-Clinical and Clinical Research 2026, Vol 20, No 3, 131–136
www.jpccr.eu

Unusual presentations of large mature ovarian teratomas in adolescents

Zuzanna Helena Skiba[1,A-E] ✉, **Aleksander Siwek**[1,B-D], **Anna Torres**[2,A,D-F]

[1] *Student Scientific Association at the Department of Paediatric and Adolescent Gynaecology, Medical University, Lublin, Poland*
[2] *Department of Paediatric and Adolescent Gynaecology, Medical University, Lublin, Poland*
A – Research concept and design, B – Collection and/or assembly of data, C – Data analysis and interpretation, D – Writing the article, E – Critical revision of the article, F – Final approval of the article

Skiba ZH, Siwek A, Torres A. Unusual presentations of large mature ovarian teratomas in adolescents. J Pre Clin-Clin Res. 2026;20(3):131–136. doi:10.26444/jpccr/226321

Abstract

Introduction. Mature cystic teratoma (MCT) is the most common ovarian neoplasm in young women. It is comprised of mature tissues derived from three germ layers: ectoderm, mesoderm and endoderm. Typically, its clinical presentation includes slow growth and benign nature.

Case Reports. Three case reports are presented of adolescents with unusual presentations of MCT, who were successfully treated by laparoscopy.

Conclusions: Slow growth, small size, specific symptoms, and typical ultrasound features of MCTs assist in distinguishing them from immature teratomas, but do not provide a definitive diagnosis. Comprehensive preoperative assessment and careful surgical planning are essential. These cases demonstrate that laparoscopic ovarian-sparing surgery can be a safe and effective treatment, even for very large lesions, while preserving future fertility.

Key words

adolescent, fertility preservation, mature ovarian teratoma, immature ovarian teratoma, laparascopic surgery

INTRODUCTION

Ovarian neoplasms in paediatric and adolescent populations are rare but clinically significant, accounting for an incidence of approximately 2.6 per 100,000 girls per year [1]. Among these, mature cystic teratoma (MCT) is the most common, comprising more than 50% of cases [2]. MCT is defined as a tumour containing mature tissues derived from three germ layers: ectoderm, mesoderm and endoderm [3]. Despite their generally slow growth and benign nature, the presentation and management of such tumours in young patients can be complex, especially when symptoms overlap with more common paediatric conditions or when the tumour reaches an unusually large size.

The case reports are presented of three adolescents with unusual presentations of MCT who were successfully treated by laparoscopic removal of the lesion.

CASE REPORT 1

A 16 year-old patient weighing 56 kg, with height of 166 cm (BMI 20 kg/m^2), was admitted to the Department of Paediatric and Adolescent Gynaecology after presenting to the Paediatric Emergency Department due to increased abdominal circumference. The significant enlargement of the abdomen was the patient's first noticeable symptom. The girl additionally reported abdominal pain, which she rated as 5 /10 in the NRS scale, and constipation. The patient had been hospitalized previously, in 2012, 2016, 2017 and 2021, in the same hospital due to upper abdominal pain and gastrointestinal infections. Transabdominal ultrasound examinations conducted on each admission, did not revealed any abnormal findings. However, no ultrasound examination of the patient's reproductive organs was performed during those admissions, nor had she been consulted by a gynaecologist. Gynaecological interview revealed that the patient's first menstruation had occurred at the age of 11. Her menstrual cycles usually lasted for 27–28 days, however, in the last 3 months they shortened to approximately 23 days. Menses typically lasted for 5 days and were without additional complaints. A family history review revealed the presence of uterine malignancy in the patient's grandmother. Upon admission, a physical paediatric examination revealed that the abdominal circumference was significantly enlarged (Fig. 1). On palpation, slight tenderness was noted, and a hard, immobile mass was detected in the abdominal cavity, palpable 3 cm above the umbilicus. Vaginal exam was not performed due to lack of patient's consent. However, she



Figure 1. Picture of the abdomen (Case 1)

✉ Address for correspondence: Zuzanna Helena Skiba, Student Scientific Association at the Department of Paediatric and Adolescent Gynaecology, Medical University, Lublin, Poland
E-mail: zuzannaskiba01@o2.pl

Received: 10.06.2026; accepted: 23.07.2026; first published: 20.08.2026

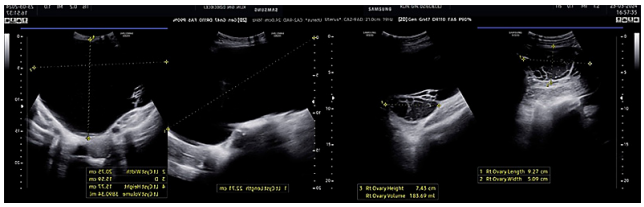

Figure 2. Ultrasonography (Case 1)

agreed to transrectal palpation to asses any abnormalities within the reproductive system. The examination revealed no deviations from the normal findings. On the transabdominal ultrasonography (US) examination, the uterus and left ovary were within normal echogenicity and size. Instead of the right ovary, however, an oval lesion measuring 18 × 10 × 13 cm, volume of 3,890 mL, was observed in the suprapubic region. The lesion was mostly cystic and had a smooth capsule. The examination also identified a cystic-solid component inside the lesion with a volume of 184 mL, located peripherally and connected to the capsule without visible vascularization (Fig. 2). The patient underwent laboratory tests and a chest X-ray. An examination of the patient's tumour marker levels was conducted. The results indicated that the levels were within the norm: Beta-hCG <0.10 mIU/ml, AFP: 1.1 ng/ml, CBC and basic biochemistry were also within normal ranges.

On the day of admission, cardiologic and surgical consultations were conducted. No indications for urgent intervention were identified. After haematologic consultation, an MRI of the patient's abdomen was performed which revealed a formation with 2 cysts measuring 18 × 9 × 23cm and 5 × 2,6 × 7cm. At the border between the cysts, a tissue area measuring 2.7 × 1.4 cm was detected, with small follicles that supported the ovarian origin of the lesion (so-called ovarian crescent sign – OCS) [4] (Fig. 3). No enlarged lymph nodes or signs of tumour spread were present. No signals typical for fat tissue or other components typical for MCT were detected. After the consultations with the gynaecological oncology specialist and Paediatric Haematooncology Unit, the decision was made to discuss with the patient and her parents, the performance of laparoscopy as the surgical treatment During the discussion, all the information about proposed treatment were presented, including the possibility of capsule rupture and its consequences. Informed consent was signed for the laparoscopic removal of the tumor with preservation of the affected ovary, if feasible. The closed laparoscopy technique with two working and one optical trocar was utilized. After cystectomy, the pneumoperitoneum was established which revealed that the tumour was confined to the right ovary, the

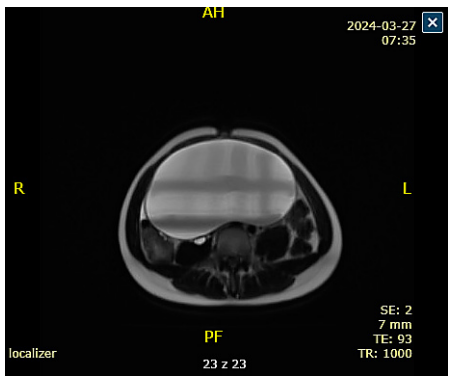

Figure 3. Magnetic resonance imaging (Case 1)

capsule was smooth, no torsion was present, and the fallopian tube on the right side was without abnormalities. The procedure was performed during which a large volume of the normally appearing ovarian tissue was preserved. The tumour was removed from the abdominal cavity using an Endobag. The gross appearance of the tumour was not typical for the MCT, and was therefore sent for the intraoperative frozen section examination. No malignancy was revealed. The operation continued but was limited only to tumour removal. Patient's postoperative course was uneventful and she was released home on the second postoperative day. The final pathology report stated that the lesion was an MCT. On the subsequent follow-up visits, the transabdominal US examinations revealed normalization of the size and echogenicity of the right ovary, and the patients did not present any abnormal symptoms. Her menses were regular without co mplaints.

CASE REPORT 2

A 16-year-old female patient weighing 54 kg, with a height of 163 cm (BMI 29 kg/m^2) presented to the Outpatient Clinic complaining of gradually increasing abdominal girth. This symptom had appeared during the previous year, and in the preceding six months it had been accompanied by significant abdominal pain. During the patient's visit, a diagnosis of ovarian tumour was made, and she was referred to the Department of Paediatric and Adolescent Gynaecology for further evaluation and treatment. Gynaecological interview revealed that menarche occurred at the age of 15. The patient reported shortened menstrual cycles, ranging in length from 14–21 days. Menses typically lasted for 5 days and were without symptoms of dysmenorrhea. A subsequent comprehensive paediatric physical examination demonstrated a notable increase in abdominal circumference. Palpation detected the presence of hard mass filling the abdominal cavity, up to one finger above the umbilicus. During the gynaecological examination, an abnormal discharge was observed in the genital tract. A vaginal swab was obtained from the patient, which gave positive results for the presence of Candida albicans and Group B Streptococcus. The empirical treatment plan included metronidazole and clotrimazole administered vaginally, and fluconazole administered orally. Initial laboratory investigations, including a complete blood count, revealed severe microcytic anaemia (Hb: 8.10 g/dl, MCV: 65.7 ft). The results of tumour marker levels indicated that the levels were within the normal range: Ca125: 25.9 ng/ml, beta-hCG: 0.78 mIU/ml, AFP: 2.1 ng/ml, LDH: 169 U/l. Transabdominal US revealed that the uterine corpus exhibited an even shape and contour, although compressed by a cystic lesion. The lesion was oval in shape, heterogeneous, and comprised of internal partitions without vascularization. Its diameter was approximately 19 cm and a volume of almost 900ml. Within the fluid, single hyperechoic points typical of teratomas were visible (Fig. 4). The lesion was classified as O-RADS 4. The most probable origin was the right ovary; the left ovary, however, was not visualized during the examination. Four days later, the girl underwent an MRI of the lower pelvis with intravenous contrast (Fig. 5 and 6) which revealed a well-demarcated solid-fluid lesion, measuring approximately 21 × 15 × 11cm. The lesion was located centrally and slightly on the left side, extending to the mediastinum and displacing the left kidney upward, with slight compression

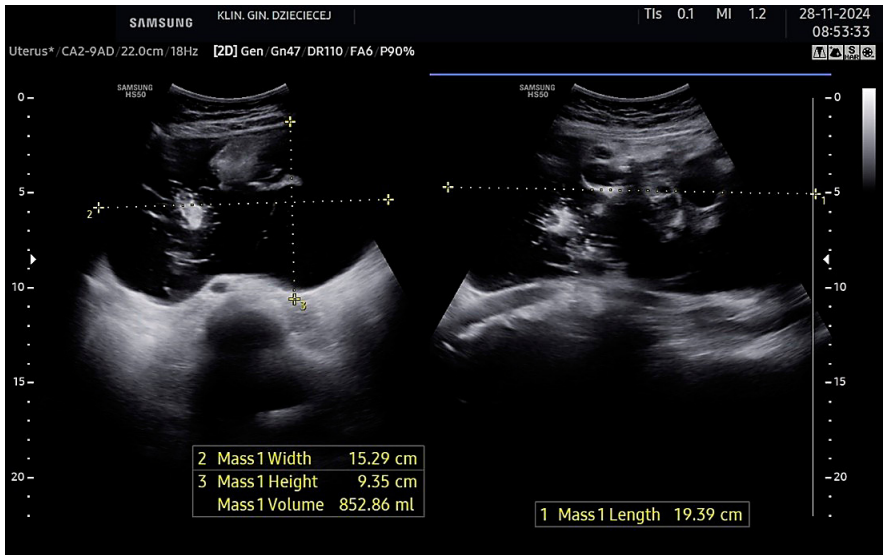

Figure 4. Ultrasonography (Case 2)

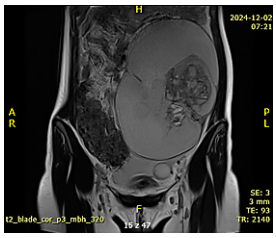

Figure 5. Magnetic resonance imaging (Case 2)

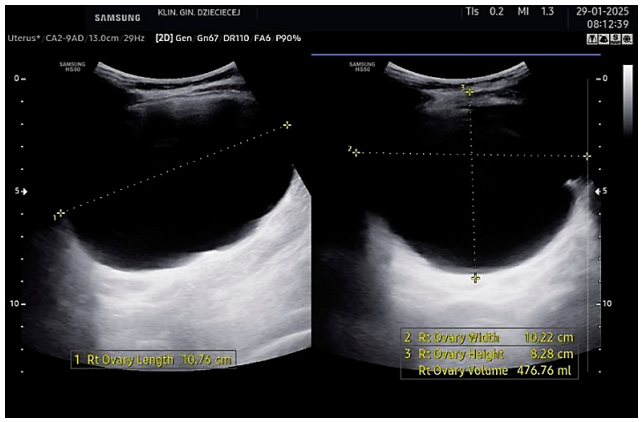

Figure 6. Ultrasonography (Case 3)

of the left ovary and uterus. Following the administration of a contrast, the solid component, cyst wall, and intra-cystic partitions underwent heterogeneous enhancement. The left ovary was also visualized. Its dimensions were assessed as 42 × 30 × 35 mm, while no preserved tissue from the right ovary could be identified. The image was indicative of a teratoma of the right ovary. No enlarged lymph nodes were identified in the pelvis. During the examination, a minimal amount of fluid was identified within the pouch of Douglas. One day prior to the scheduled surgery, the patient was consulted with a paediatric haematologist due to the presence of anaemia (Hb level of 8.1 g/dl). It was recommended that the patient receive a transfusion of two units of red blood cell concentrate prior to the procedure. Subsequently, the girl was qualified for a laparoscopy with the plan to remove the lesion and preserve the ovary. The closed laparoscopy technique with two working and one optical trocar was utilized. Upon insertion of the laparoscope, an enlarged right ovary with a smooth capsule measuring approximately 20 cm in diameter was seen which occupied the most of the lower part of abdominal cavity. Adhesions between the cyst and peritoneum were also identified. The described peritoneal adhesions were dissected and released, restoring the normal anatomical conditions of the peritoneum. The right ovarian wall was then incised. However, during dissection of the cyst, the capsule was damaged, resulting in the spillage of a transparent fluid which was instantly aspirated. After dissection of the cyst, a large portion of the healthy-appearing ovarian tissue measuring 4 × 3 × 3 cm was preserved. Haemostatic sutures were applied to the cyst lodge. The cyst was removed from the abdominal cavity using an Endobag through the left trocar entry. After the removal, the interior of the lesion turned out to be consistent with a dermoid cyst containing cartilaginous tissue, bone, hair, and sebum. Next, peritoneal lavage with saline was performed. The samples obtained from the patient were sent for histopathological examination. The results confirmed the diagnosis of a dermoid cyst of the right ovary.

CASE REORT 3

A premenarchal 11-year-old patient weighing 26 kg, with a height of 140 cm (BMI 13,27 kg/m^2, 22th percentile) was admitted to the Department of Paediatric and Adolescent Gynaecology in Lublin on an emergency basis. The admission of the patient was prompted by lower abdominal pain that had started the previous morning, and then stopped. The pain reoccurred on the day of admission and worsened after micturition. Moreover, the mother of the girl admitted that she had noticed an increase in the circumference of her daughter's abdomen two days earlier. Transabdominal US carried out in the Emergency Department visualized a tumour, likely originating from the left ovary. The girl suffered from epilepsy and cerebral palsy, and due to spastic quadriplegia, she relied on a wheelchair for mobility. At the time of admission, the patient was in general good condition and was not taking any medication. A general paediatric

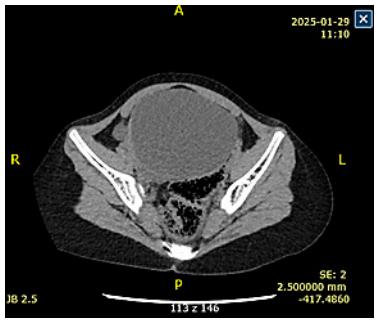

Figure 7. Computed tomography (Case 3)

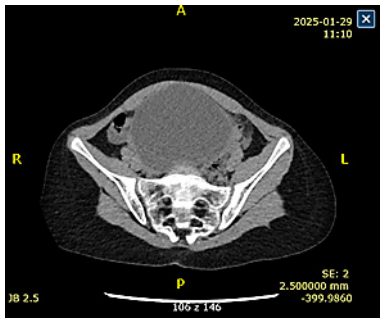

Figure 8. Computed tomography (Case 3)

physical examination revealed a low body weight (26kg) corresponding to the 3rd percentile for age. However, it was observed that the abdomen was well elevated above the thorax. On palpation, a hard resistance was found, filling the abdominal cavity approximately to the level of the umbilicus. The tumour mass was slightly tender, with limited mobility. Due to the language barrier, collecting gynaecological history resulted in considerable difficulty. Laboratory findings including complete red blood cell count, were within normal range. The tested tumour marker levels were within the normal range: Ca125: 18.9 ng/ml, beta-hCG <0.10 mIU/ml, AFP <0.9 ng/ml, LDH: 200 U/l. On US, a large, fluid-filled cystic lesion measuring approximately 10.7 × 10.2 × 8.3 cm, with a volume of almost 477 ml was identified within the right ovary (Fig. 6). The lesion contained a single septum of 4 mm in thickness and an area of single hyperechoic inclusions measuring 7.8 × 3.8 cm, without any internal vascular flow on Doppler imaging. It was classified as a benign lesion, ORADS-3. Computed tomography (CT) with contrast was performed (Fig. 7 and 8) which showed an oval, heterogenous lesion with a component of fluid, fat and bone. The lesion measured approximately 8 × 9.4 × 11 cm, localized on the right side of the pelvis. The CT image was indicative of a teratoma of the right ovary. The left ovary was visualized as a separate, small-follicular structure, measuring 28 × 10 mm. The uterine corpus measured 32 × 8 mm, and was compressed by the lesion. No enlarged lymph nodes were observed in the retroperitoneal space. The patient was qualified for laparoscopic surgery; consent was obtained from the mother and the patient. After insertion of the laparoscope, an ovarian cyst with a smooth capsule measuring 11cm in diameter was found. During the cyst dissection, its wall was disrupted and an outflow of clear, yellowish fluid was observed without other signs typical of MCT. The right ovarian cyst was removed from the abdominal cavity in an Endobag. The subsequent histopathological examination confirmed the diagnosis of MCT of the ovary.

DISCUSSION

Although MCTs are mostly asymptomatic, they may also present a range of symptoms with pelvic pain being the most prevalent [5–7]. Different manifestations include a palpable abdominal mass, sensation of abdominal fullness, constipation, nausea, vomiting, and more severe complications such as torsion or rupture [1, 5, 8, 9]. Even though immature teratoma is diagnosed even less frequently, it should always be considered in the differential diagnosis of ovarian MCT [9]. Most often, tumour size helps to differentiate the two diseases. In these cases, the patients presented with lesions measuring 23 cm, 21 cm and 11 cm in diameter, respectively, which were subsequently diagnosed as a benign neoplasm. However, in most published studies, the large tumour size is more characteristic of the immature as compared to mature teratoma. Diameters of immature teratomas usually reach more than 10 cm, with a mean value of 16 cm, whilst 6.5 cm is the average diameter typical of MCTs [2,6]. Growth rate is another feature distinguishing the two neoplasms. In general, MCTs exhibit slow growth rate, allowing for detection before they reach a larger size. Additionally, a sudden and significant enlargement of the abdomen is more typical for immature teratoma [1]. Patient 1 and Patient 2 had undergone abdominal ultrasonography examination two and four years before, respectively, before the diagnosis, which suggested that the tumour size must have increased quite rapidly. Given that it was anechoic on ultrasonography, it would be expected to be easily detectable on abdominal ultrasound if it had been significantly larger at that time. Owing to the language barrier and limited cooperation from Patient 3, additional information regarding prior physical examinations or ultrasound could not be obtained. The conventional methodologies for the assessment of paediatric ovarian masses include US, MRI and computed tomography (CT) [1]. MCTs have a variable sonographic appearance. Some researchers claim that the OCS is one of the most important sonographic findings predicting a benign ovarian lesion. It is defined as a visible piece of normal ovarian tissue adjacent to the cyst, indication that the lesion has not completely destroyed the organ's parenchyma. The identification of the OCS supports the diagnosis of a benign lesion and may facilitate the future decision to perform ovary-sparing surgery [10].

Another, more common appearance in the US is a cystic mass with a hyperechoic Rokitansky nodule that arises from the cyst wall and is composed of hair, fat and bone. It may extend into the cyst lumen and create a posterior acoustic shadowing [1, 2]. When the nodule localizes in the superficial part of the lesion, it may contribute to hindering the sonographic visualization of the deeper structures of the mass. This ultrasonographic image is referred to as the 'tip of the iceberg' [1, 2, 11, 12]. In equivocal cases, additional use of CT or MRI should be considered. CT is sensitive for fat detection and may reveal an eventual calcification of the cyst wall [1,9]. Moreover, CT and MRI are helpful for staging and assessing the tumour resectability [6]. Immature cystic teratomas, on the other hand, may have variable sonographic appearance [1]. Additionally, in Case 1 intraoperative frozen section was performed because of the significant size of the lesion. However, research has shown that frozen section histological examination of large masses does not improve the intraoperative diagnosis and is no longer recommended, especially for lesions of significant size [13, 14].

The O-RADS classification is a common tool based on a scoring system used in adult women with adnexal lesions for determining the risk of potential malignancy. Since malignancy is so rare in children and adolescents, the O-RADS system may be challenging in this particular age group [15,16]. In this, review, the lesion in Patient 1 has been described as O-RADS 4 on US, based on the examiner's clinical assessment and experience. The score of 4 could be classified as an intermediate risk of malignancy, but in fact, the lesion was benign. There is still limited data about the use of O-RADS in paediatric patients and further studies are needed for it to be evaluated. Risk of malignancy, age of the patient, and desire to preserve fertility are the most important factors in deciding on a treatment method for ovarian teratomas [17]. Surgical procedures remain the leading therapeutic strategy for ovarian tumours, and are categorized as either ovarian-sparing or total oophorectomy performed either by laparoscopy or laparotomy [18]. In recent years, laparoscopy has been gaining in popularity Its advantages over laparotomy include improved visualization, shorter hospital stays, less post-operative pain, and better cosmetic outcomes – factors that are particularly important for the psychological well-being of children and young adolescent girls [19,20]. Furthermore, it is highly beneficial to perform laparoscopy in young women, especially because of the reduced risk of adhesion formation, which directly contributes to the preservation of fertility [21]. Conversely to the cases presented in the current review, in the study by Guille´n et al., laparoscopy was recommended for ovarian teratomas smaller than 6 cm in diameter [22] as concerns have been raised about the safety of minimally invasive management of large ovarian dermoid cysts due to a higher risk of cyst rupture and spillage in the abdominal during surgery. Such spillage is concerning because of the potential presence of malignant components, as larger teratomas are more likely to exhibit malignant features [23]. In the currently presented cases, considering the young age of the patients, mild pain symptoms and low levels of serological tumour markers – Ca 125, beta-hcG, AFP, CEA and AMH, the decision was made to proceed with closed laparoscopy. Additionally, in Cases 1 and 3, a sonographic image typical of mature teratoma further supported this approach. Intraoperatively, the macroscopic appearance of the lesion was initially evaluated to exclude the possibility of malignancy. Despite the large sizes of the tumours, closed laparoscopy was possible, and proved to be safe in all of the cases. Nevertheless, in recent years, a new surgical technique – mini-laparotomy – has also been growing in popularity. This could be considered a minimally invasive approach, involving a transverse or vertical abdominal incision measuring 2–3 cm in length [24, 25]. This technique represents an intermediate option between laparoscopy and conventional laparotomy – it provides greater working space than laparoscopy, while resulting in a small and aesthetic scar, unlike standard laparotomy [25]. Mini-laparotomy may be used as an alternative to laparoscopy in paediatric management of ovarian masses, particularly when laparoscopy is not viable. In a study conducted by Trotman et al. in 2017, the outcomes of 44 patients aged 6–21 years with benign adnexal lesions were analyzed. Twenty-six patients underwent laparoscopy, while 18 underwent mini-laparotomy, and the two techniques were compared in terms of intra-operative and post-operative outcomes. The procedures did not differ significantly in terms of operative time, post-operative pain, or duration of hospital stay. The only disadvantage of mini-laparotomy compared with laparoscopy was the intra-operative blood loss, which averaged 53.6 mL and was nearly five times greater than the one that observed during laparoscopy (11.9 mL) [26]. However, in the event of difficult access to laparoscopy, mini-laparotomy remains a valuable and effective alternative. Once the surgical approach has been selected, the next decision concerns determination of the extent of lesion resection. In the case of ovarian teratomas, two surgical procedures are standard – cystectomy and salpingo-oophorectomy. It would appear that cystectomy offers better fertility preservation and is mostly proposed for management of MCTs, whereas salpingo-oophorectomy remains the more effective treatment in terms of preventing disease recurrence in more advanced cases [27, 28]. In 2017, Zhao et al. conducted a clinical trial assessing this problem which included 43 patients with suspicion of early-stage immature ovarian teratoma, and a median age of 22 years. Fourteen patients underwent ovarian cystectomy, while 29 underwent unilateral salpingo-oophorectomy. Adjuvant chemotherapy was additionally administered to 32 patients (74.4%). The median follow-up duration was 41 months. During this period, three patients were lost to follow-up, three patients in the salpingo-oophorectomy group experienced disease relapse, however, no deaths occurred. The 5-year disease-free survival rates were 100% for the cystectomy group and 88% for the salpingo-oophorectomy group, with no statistically significant difference between them.

The findings suggest that cystectomy offers comparable oncologic safety to unilateral salpingo-oophorectomy, while providing superior fertility preservation in patients with early-stage immature ovarian teratoma [29]. In extreme situations, when a large lesion leads to ovarian torsion and subsequent necrosis, preserving the contralateral ovary should be a priority. This may also apply to benign ovarian lesions – mature teratomas. In a 2022 article describing a 10-year-old girl with symptoms analogous to those of the patients in the current review, a bilateral synchronous MCT was diagnosed. Due to the large size of the right ovarian mass (9cm), torsion, and subsequently occurring necrosis, the complete removal of right adnexectomy on that side was necessary. Meanwhile, preserving the left ovarian tissue via cystectomy was feasible and could maintain the future fertility potential of the patient [30]. During laparoscopic surgery for ovarian masses, appropriate choice of the haemostatic technique is crucial for minimizing intra-operative bleeding and post-operative complications. The methods include bipolar coagulation, haemostatic sutures and surgical haemostatic sponges. In an article by Won et al., bipolar coagulation was the most frequently used method in the laparoscopy group, while haemostatic sutures were reserved for robotic procedures. The study aimed to evaluate ovarian reserve based on the chosen surgical method. However, no difference in the degree of AMH decline was found between the two groups, and the haemostatic method used was not found to be a significant factor in this regard [31]. According to the meta-analysis by Baracat et al., haemostatic suturing is generally recommended over bipolar coagulation, as in fact, it results in a smaller decrease in AMH levels [32]. In the authors' Department of Paediatric and Adolescent Gynaecology, suturing is the method of choice when it comes to laparoscopic surgeries for ovarian teratomas in young

adolescents. Nonetheless, more research is needed to further evaluate which method of combination of methods provides the optimum results.

CONCLUSIONS

According to the literature, it is typical for MCTs to grow slowly, but they are generally detected before they reach large sizes. These presented case reports present evidence that MCTs can grow fast and mimic features of immature teratomas. It also shows that laparoscopy is a reasonable approach for the management of large size teratomas, as it offers minimal scarring, adhesions, and quick recovery. However, it is of outmost importance to explain the consequences of the capsule rupture to the family and to facilitate the informed, shared decision process [33].

Disclosure / Conflict of Interest Statement. The authors report no proprietary or commercial interest in any product mentioned or concept discussed in the article.

Acknowledgements / Funding. The research received no external funding.

Patient Consent Statement. Written informed consent for publication was obtained from all patients included in the Case Reports, and is retained by the authors.

REFERENCES

1. Birbas E, Kanavos T, Gkrozou F, et al. Ovarian Masses in Children and Adolescents: A Review of the Literature with Emphasis on the Diagnostic Approach. Children (Basel). 2023;10. doi:10.3390/CHILDREN10071114
2. Lala S V, Strubel N. Ovarian neoplasms of childhood. Pediatr Radiol. 2019;49:1463–1475. doi:10.1007/S00247-019-04456-8
3. Höhn AK, Brambs CE, Hiller GGR, et al. 2020 WHO Classification of Female Genital Tumors. Geburtshilfe Frauenheilkd. 2021;81:1145–1153. doi:10.1055/A-1545-4279
4. Stankovic ZB, Bjelica A, Djukic MK, Savic D. Value of ultrasonographic detection of normal ovarian tissue in the differential diagnosis of adnexal masses in pediatric patients. Ultrasound Obstet Gynecol. 2010;36:88–92. doi:10.1002/UOG.7557
5. Wu SY, Giannini A, Girardo M, et al. Malignant Transformation of Squamous Cell Carcinoma in Mature Cystic Teratoma of the Ovary: A Systematic Review and Meta-Analysis of Data. Gynecol Obstet Invest. 2025;90:255–267. doi:10.1159/000542672
6. Tarca E, Trandafir LM, Cojocaru E, et al. Diagnosis Difficulties and Minimally Invasive Treatment for Ovarian Masses in Adolescents. Int J Womens Health. 2022;14:1047–1057. doi:10.2147/IJWH.S374444
7. Gkrozou F, Tsonis O, Vatopoulou A, et al. Ovarian Teratomas in Children and Adolescents: Our Own Experience and Review of Literature. Children (Basel). 2022;9. doi:10.3390/CHILDREN9101571
8. Rathore R, Sharma S, Arora D. Spectrum of Childhood and Adolescent Ovarian Tumors in India: 25 Years Experience at a Single Institution. Open Access Maced J Med Sci. 2016;4:551–555. doi:10.3889/OAMJMS.2016.090
9. Grisales-Gallo JE, Salinas-Castro KJ, Nasner D, Toro-Gutiérrez JS. Mature cystic teratoma overlapping with giant serous cystadenoma of the ovary: A case report. Radiol Case Rep. 2024;19:218–222. doi:10.1016/j.radcr.2023.10.030
10. Stanković ZB, Dural O. A maturing approach to the assessment of ovarian teratomas. Best Pract Res Clin Obstet Gynaecol. 2026;105:102701. doi:10.1016/J.BPOBGYN.2026.102701
11. Heo SH, Kim JW, Shin SS, et al. Review of ovarian tumors in children and adolescents: radiologic-pathologic correlation. Radiographics. 2014;34:2039–2055. doi:10.1148/RG.347130144
12. Sahin H, Abdullazade S, Sanci M. Mature cystic teratoma of the ovary: a cutting edge overview on imaging features. Insights Imaging. 2017;8:227–241. doi:10.1007/S13244-016-0539-9
13. Stanković ZB, Sedlecky K, Savić D, et al. Ovarian Preservation from Tumors and Torsions in Girls: Prospective Diagnostic Study. J Pediatr Adolesc Gynecol. 2017;30:405–412. doi:10.1016/j.jpag.2017.01.008
14. Gil LA, Lutz CM, Dillon PA, et al. Use and Accuracy of Intraoperative Frozen Section Analysis for Ovarian Masses in Children and Adolescents. J Pediatr Adolesc Gynecol. 2023;36:155–159. doi:10.1016/j.jpag.2022.10.001
15. Bae J, Kim HK, Lee I, et al. Clinical Features of Surgically Managed Adnexal Masses in Children and Adolescents at a Tertiary Referral Center. Children. 2026;13:549. doi:10.3390/CHILDREN13040549/S1
16. Epstein K, Dillman J, Abu Ata N, et al. Assessment of ultrasound ovarian-adnexal reporting & data system (O-RADS) for pediatric patients. Pediatr Radiol. 2026;56:856–866. doi:10.1007/S00247-026-06546-W
17. Cong L, Wang S, Yeung SY, et al. Mature Cystic Teratoma: An Integrated Review. Int J Mol Sci. 2023;24. doi:10.3390/IJMS24076141
18. Spinelli C, Strambi S, Masoni B, et al. Surgical management of ovarian teratomas in childhood: a multicentric study on 110 cases and a literature review. Gynecol Endocrinol. 2021;37:950–954. doi:10.1080/09513590.2021.1948527
19. Tankou J, Foley OW, Liu CY, et al. Dermoid cyst management and outcomes: a review of over 1000 cases at a single institution. Am J Obstet Gynecol. 2024;231:442.e1–442.e7. doi:10.1016/j.ajog.2024.04.021
20. Pecorelli S, Tonegatti uca G, Stern MV, et al. Management of Large Pediatric and Adolescent Ovarian Neoplasms with a Leak-Proof Extracorporeal Drainage Technique: Our Experience Using a Hybrid Minimally Invasive Approach. J Pediatr Adolesc Gynecol. 2021;34:394–399. doi:10.1016/j.jpag.2020.08.009
21. Raźnikiewicz A, Korlacki W, Grabowski A. The role of laparoscopy in paediatric and adolescent gynaecology. Wideochir Inne Tech Maloinwazyjne. 2020;15:424–436. doi:10.5114/WIITM.2020.97817
22. Guillén G, Martín-Giménez MP, López-Fernández S, et al. Results of Ovarian Sparing Surgery in Pediatric Patients: Is There a Place for Laparoscopy? J Laparoendosc Adv Surg Tech A. 2020;30:458–463. doi:10.1089/LAP.2019.0515
23. Knaus ME, Onwuka AJ, Afrazi A, Breech L, et al. Laparoscopy versus laparotomy for pediatric ovarian dermoids. J Pediatr Surg. 2022;57:1008–1012. doi:10.1016/j.jpedsurg.2022.01.053
24. Lee SR. Fast Leak-Proof, Intraumbilical, Single-Incision Laparoscopic Ovarian Cystectomy for Huge Ovarian Masses: "Hybrid Cystectomy and Reimplantation" Method. Medicina (Kaunas). 2021;57. doi:10.3390/MEDICINA57070680
25. Shaltout MF, Maged AM, Abdella R, et al. Laparoscopic guided minilaparotomy: a modified technique for management of benign large ovarian cysts. BMC Womens Health. 2022;22. doi:10.1186/S12905–022–01853–4
26. Trotman G, Foley C, Taylor J, et al. Postoperative Outcomes among Pediatric and Adolescent Patients Undergoing Minilaparotomy vs Laparoscopy in the Management of Adnexal Lesions. J Pediatr Adolesc Gynecol. 2017;30:632–635. doi:10.1016/j.jpag.2017.06.009
27. Sireesha M, Chitra T, Subbaiah M, Nandeesha H. Effect of Laparoscopic Ovarian Cystectomy on Ovarian Reserve in Benign Ovarian Cysts. J Hum Reprod Sci. 2021;14:56–60. doi:10.4103/JHRS.JHRS_94_20
28. Zhang X, Yang J, Wang J, et al Early stage ovarian immature teratoma, surveillance or chemotherapy after surgery? A propensity score matched analysis. Gynecol Oncol Rep. 2022;40. doi:10.1016/j.gore.2022.100976
29. Zhao T, Liu Y, Wang X, et al. Ovarian cystectomy in the treatment of apparent early-stage immature teratoma. J Int Med Res. 2017;45:771–780. doi:10.1177/0300060517692149
30. Lešková J, Kříž JT, Štichhauer R. Bilateral Mature Ovarian Teratoma with Torsion in a Premenarchal Girl. Acta Medica (Hradec Kralove). 2022;65:33–36. doi:10.14712/18059694.2022.14
31. Won S, Choi SH, Lee N, et al. Ovarian Reserve After Robotic Versus Laparoscopic Single-Site Ovarian Cystectomy for Mature Cystic Teratoma: A Prospective Comparative Study. J Clin Med. 2025;14. doi:10.3390/JCM14113800
32. Baracat CMF, Abdalla-Ribeiro HSA, Araujo RSDC, et al. The Impact on Ovarian Reserve of Different Hemostasis Methods in Laparoscopic Cystectomy: A Systematic Review and Meta-analysis. Rev Bras Ginecol Obstet. 2019;41:400–408. doi:10.1055/S-0039–1692697
33. Pashankar F, Murray MJ, Gell J, et al. Consensus and controversy in the management of paediatric and adult patients with ovarian immature teratoma: the Malignant Germ Cell International Consortium perspective. E Clin Med. 2024;69. doi:10.1016/j.eclinm.2024.102453