



Complex neuropsychiatric disorders following *Listeria monocytogenes* encephalitis and meningitis in a 16-year-old immunocompromised patient

Natalia Biedroń^{1,A-D} , Katarzyna Cencelewicz^{2,B-D} , Zofia Piaszczyk^{1,B-D} ,
Katarzyna Góźdz-Pawęska^{3,B-D} , Klaudia Żóraw^{1,B-D} , Michał Bielak^{4,E-F} ,
Magdalena Chrościńska-Krawczyk^{4,E-F} 

¹ Student Research Group, Department of Paediatric Neurology, Medical University, Lublin, Poland

² Department of General Surgery, 1st Military Clinical Hospital with the Outpatient Clinic, Lublin, Poland

³ Department of Neonatology, Pathology and Neonatal Intensive Care, Stefan Cardinal Wyszyński District Specialist Hospital, Lublin, Poland

⁴ Department of Paediatric Neurology, Medical University, Lublin, Poland

A – Research concept and design, B – Collection and/or assembly of data, C – Data analysis and interpretation, D – Writing the article, E – Critical revision of the article, F – Final approval of the article

Biedroń N, Cencelewicz K, Piaszczyk Z, Góźdz-Pawęska K, Żóraw K, Bielak M, Chrościńska-Krawczyk M. Complex neuropsychiatric disorders following *Listeria monocytogenes* encephalitis and meningitis in a 16-year-old immunocompromised patient. *J Pre-Clin Clin Res.* 2026;20(2):118–122. doi:10.26444/jpccr/221222

Abstract

Introduction. Listeriosis in immunocompetent patients usually presents as gastroenteritis with fever; however, it can occasionally lead to severe infections such as meningitis and sepsis. The case report concerns a boy with several autoimmune diseases on immunosuppressive therapy, who developed behavioural issues due to *Listeria monocytogenes* (LM) infection.

Case Report. The patient was suspected of meningitis, and polymerase chain reaction testing of the cerebrospinal fluid revealed the presence of LM. The patient's condition worsened, neurological symptoms increased, and the patient developed sepsis, requiring treatment in the Intensive Care Unit (ICU). After a monthly stay in the ICU, contact with the patient returned, but the infection caused severe behavioural changes. Autoimmune encephalitis was suspected and psychiatric treatment initiated.

Conclusions. This case illustrates the broader issue of LM infection and emphasizes the need for special attention in the care of immunocompromised patients.

Key words

sepsis, psychiatric disorders, paediatrics, listeriosis, autoimmune encephalitis, meningitis

INTRODUCTION

Listeria monocytogenes (LM) is a facultative Gram-positive intracellular bacillus that causes listeriosis. It has virulence factors that allow it to survive and grow at low temperatures, low pH, and has the ability to produce a biofilm. This makes it significantly more difficult for food control, causing products such as cheese, cured meats, unpasteurized milk, and even fruits or vegetables, to be potential sources of infection [1–3].

Although the incidence of listeriosis is not relatively high – it remains between 0.042–0.469 per 100,000 people – it has a high rate of hospitalization and mortality (20–30%) [3, 4]. A group especially prone to LM infections due to impaired defence mechanisms are newborns, the elderly, and people with reduced levels of immunity, including patients submitted to immunosuppressive treatment [2]. The infection usually manifests as gastroenteritis and fever and is often self-limiting in immunocompetent patients [1]. However, the disease can take an invasive form, such as meningitis and

septicaemia, and there are several case reports of invasive forms in immunocompetent children [1, 2, 5]. Meningitis has a clinical manifestation similar to other infections, often showing a rapid and aggressive course [6]. A relatively new retrospective analysis of data on the subject confirmed the non-specific nature of the disease, further emphasizing that standardized treatment protocols are lacking at this point [2]. In contrast, a 2025 study of neuroinfection found that the condition in immunocompromised individuals can develop atypically without fever, and that various combination therapies demonstrate the difficulty of treatment [7].

The multifaceted nature of this issue from the virulence of the bacteria to the aggressive progression of neuroinfection, sepsis, and complicated treatment, is a major clinical problem, and data on this topic in the paediatric population is still limited [2, 7].

The case is presented of a 16-year-old boy affected by ulcerative colitis (UC), autoimmune hepatitis and primary sclerosing cholangitis treated with immunosuppressive therapy. He developed an innocuous fever that progressed to encephalitis, meningitis and sepsis, which wreaked havoc on his organism and caused significant functional neutrophil impairment. Informed consent to present this case report, clinical and laboratory data, were obtained from the patient's parents.

✉ Address for correspondence: Natalia Biedroń, The Student Research Group, Department of Paediatric Neurology, Medical University, Lublin, Poland
E-mail: nataliabiedron7@gmail.com

Received: 24.03.2026; accepted: 29.04.2026; first published: 08.05.2026

CASE REPORT

A 16-year-old boy was admitted to the district hospital due to a severe headache, which woke him from sleep, and a fever preceding sleep (Fig. 1).

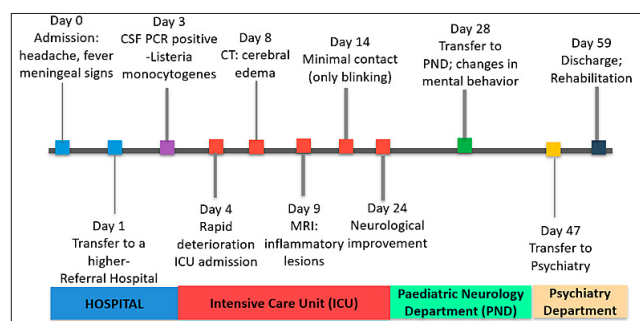


Figure 1. Course of the patient's illness

Three years earlier, the patient had been diagnosed with UC, which was treated with mesalazine and azathioprine, and one year before that, he had been diagnosed with autoimmune sclerosing cholangitis (ASC), for which oral steroid therapy with prednisone was added to his treatment.

Physical examination at the district hospital revealed meningeal symptoms: neck stiffness and positive bilateral Kernig's sign. Laboratory tests showed leukocytosis with neutrophilia and increasing inflammatory indicators. The rapid antigen test did not detect influenza, COVID-19 or RSV infection. Blood cultures were ordered and empirical antibiotic therapy was initiated – cefuroxime, followed by cefotaxime and amikacin, as well as mannitol, dexamethasone and painkillers – paracetamol and ibuprofen. Despite the use of analgesics, the boy's headache persisted. A non-contrast computed tomography (CT) scan of the head showed no abnormalities.

Due to suspected meningitis, after one day of hospitalisation at the district hospital, the boy was referred to the Emergency Department of a higher-level referral hospital. The patient was consulted by a neurologist, and was in good general condition, fully conscious and coherent. The neurological examination showed no abnormalities, and meningeal symptoms were negative. On the same day, the boy was transferred from the Emergency Department to the Paediatric Endocrinology and Diabetology Department, where his condition deteriorated. Upon admission, the patient was weak and vomiting. The previously initiated empirical antibiotic therapy was continued. Inflammatory markers were increasing (Fig. 2).

On the third day of hospitalisation, due to persistent severe headache, fever and previous positive meningeal symptoms, a

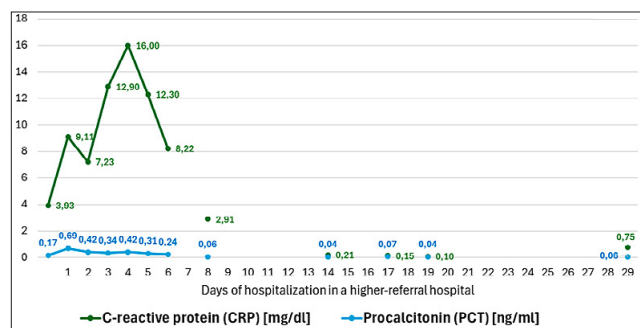


Figure 2. Results of inflammatory markers (CRP and PCT)

lumbar puncture was performed. Polymerase chain reaction (PCR) testing of cerebrospinal fluid (CSF) for 14 pathogens detected the presence of LM. Based on the test results, antibiotic therapy was modified on the third day of hospitalisation – ampicillin (2 gm per dose every 4 hours) and meropenem (2 gm per dose every 8 hours). Due to clinical symptoms suggesting cerebral oedema resulting from meningitis, treatment with dexamethasone (8 mg per dose every 8 hours), mannitol, paracetamol and ibuprofen for pain was continued. However, a repeat CT scan of the head revealed no abnormalities.

Despite treatment, the boy's condition deteriorated. As a result, multiple neurological and anaesthesiological consultations were conducted. Metamizole and nalbuphine were added to the pain management regimen, after which the boy's headache subsided. Following a neurological consultation, phenobarbital was also added to the treatment.

On the morning of the third day of hospitalisation, the boy was in logical contact. During another neurological examination in the afternoon of the same day, the patient's condition worsened again; only periodic awakenings with anxiety and screaming were observed. The patient was very restless and opisthotonos appeared, despite the addition of phenobarbital. The patient developed a high fever (38.5 Celsius), asymmetry, and significant dilation of the pupils (wider left pupil), and a poor light reaction. Meningeal symptoms, including neck stiffness and Kernig's sign, were present. Vomiting was also observed.

On the fourth day of hospitalisation, the boy was unconscious and unresponsive to pain. Although he was haemodynamically stable, passive oxygen therapy was started due to desaturation. Because of the decline in his condition, the patient was transferred to the Intensive Care Unit (ICU) and an urgent magnetic resonance imaging (MRI) scan of the head was ordered. The boy was intubated and analgesic sedation with thiopental and morphine was administered. In the ICU, the boy continued to receive antibiotic therapy with ampicillin, meropenem, and fluconazole, which was then switched to ampicillin, gentamicin, and acyclovir. Antibiotics were administered as follows: ampicillin 2 gm every 4 hours and gentamicin 5 mg per kilogram of body weight daily, in 3 doses. ICU treatment was also adjusted – azathioprine was discontinued. In addition, immune globulins were supplemented.

A contrast-enhanced MRI on the 9th day of hospitalization showed extensive symmetrical diffusion in the subcortical white matter. The left lateral ventricle was enlarged, and there was partial flattening of the cerebral sulci, indicating oedema. The MRI findings suggested inflammatory lesions in the brain (Fig. 3). In addition, a CT scan performed on the 8th day of hospitalisation confirmed signs of cerebral oedema and revealed fluid accumulation in the occipital foramen. The scan results corresponded to the lesions observed in the MRI scan (Fig. 4).

During the first 2 weeks in the ICU, the boy was unconscious. After 2 weeks, limited contact was established with the boy through him blinking his eyes (yes or no answers). The eyeballs tended to turn to the right, flaccid paresis was noted in the upper limbs, and involuntary movements were present in the lower limbs, with a positive Babinski sign on the right. No meningeal symptoms, such as neck stiffness or Kernig's sign, were observed.

In a neurological examination on the 24th day of hospitalisation in the ICU, the boy spontaneously opened

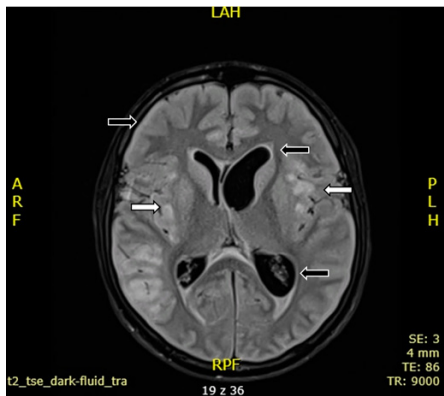


Figure 3. MRI scan on the 9th day of hospitalization. White arrows indicate the presence of subcortical diffusion, which is shown in black. Detailed information regarding brain symptoms is provided, including flattened cerebral sulci and lateral ventricle enlargement

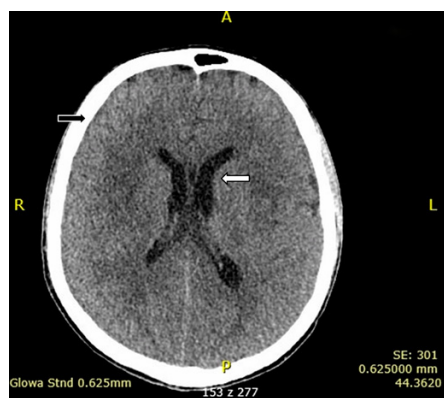

Figure 4. CT scan on the 8th day of hospitalization. The black arrow points to flattened cerebral sulci, suggesting cerebral oedema. The white arrow points to an asymmetrical, enlarged left lateral ventricle. The ventricular system is not displaced

his eyes, and a slight asymmetry of the pupils was visible. The boy was unable to look to the left when following objects with his eyes. Tendon reflexes were present in the upper limbs, while in the lower limbs, knee reflexes were discreet and ankle reflexes turned into clonus. Neck stiffness was also present.

The boy was also consulted by an endocrinologist and found to have significantly reduced thyroid-stimulating hormone and elevated cortisol levels, which were treated with levothyroxine and a reduction in the dose of hydrocortisone.

Due to the occurrence of watery stools without pathological blood admixtures, the boy was consulted by a gastroenterologist. A stool test on the 10th day of hospitalisation in the ICU revealed the presence of *Clostridium difficile* toxins A and B. Therefore, vancomycin and metronidazole were added to the treatment.

On the 28th day of hospitalisation, the patient was transferred from the ICU to the Paediatric Neurology Department for further diagnosis, treatment, and rehabilitation. Upon admission to the ward, the boy was found to have flaccid quadriplegia. The direct and consensual pupillary response to light was slowed. Tendon reflexes in the upper and lower limbs were weakened. The patient also began to utter single one- or two-syllable words, which, however, were illogical. Eleven days after admission to the Paediatric Neurology Department, quadriplegia gradually began to subside.

In addition, during hospitalisation in the Paediatric Neurology Department, a urinary tract infection caused by *Pseudomonas aeruginosa* was detected and treated with amikacin.

An MRI scan of the head was also ordered, which showed visible progression of the changes described in previous examinations, especially in the cerebral cortex of the frontal and partially parietal gyri, with thickening and the appearance of new high-signal foci in the white matter (Fig. 5).

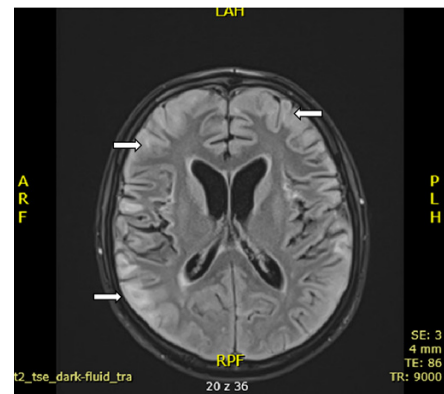


Figure 5. MRI scan during the patient's stay in the Paediatric Neurology Department. White arrows indicate a new area of high signal intensity in the parenchyma

The patient experienced a significant behaviour change. During the first two weeks of hospitalisation, the boy began to resist examination, initially by pulling his limbs away and then by using profanities. Based on the clinical picture, secondary autoimmune encephalitis (AE) was suspected. Immunoglobulin therapy was initiated for 7 days, along with prednisone. However, laboratory tests did not confirm the presence of anti-NMDA, anti-MOG, anti-neuronal, or anti-aquaporin-4 antibodies.

The boy also had increasing swelling of the lower limbs. Furosemide was added to the treatment, but without satisfactory results. Due to suspected thrombosis of the lower limbs, a Doppler ultrasound of the lower limbs was ordered. Due to the patient's lack of cooperation, it was not possible to fully assess possible changes in the vessels. In addition, possible cardiological, nephrological and gastroenterological causes were ruled out. However, it was suggested that the swelling of the limbs was most likely due to the patient's verticalisation after a long period of immobilisation.

During the following weeks of his stay in the Paediatric Neurology Ward, the patient became increasingly aggressive towards his family and medical staff. It was necessary to use direct coercive measures several times, in the form of safety belts. The boy was also caught trying to eat paper clips. As a result of such behaviour, the patient was referred to a psychiatrist, who concluded that he was not self-aware or aware of others. The psychiatrist suggested that the patient might be suffering from epileptic seizures. As a result, an attempt was made to diagnose possible seizure disorders, but due to the boy's lack of cooperation, the effort to perform an EEG test was unsuccessful. Initially, hydroxyzine and haloperidol were used to calm the patient, and then, in consultation with the psychiatrist, risperidone was added. Despite the antipsychotic treatment, the boy's condition did not improve.

Due to the failure of behavioural disorders treatment, a decision was made to transfer the boy after 47 days of

hospitalisation in the Paediatric Neurology Department, to the Child and Adolescent Psychiatry Department to stabilise the patient's mental state.

The patient had no history of mental or psychological problems. During his 12-day stay in the psychiatric ward, the patient remained difficult to communicate with – mute and with incomplete allopsychic orientation. However, no aggressive behaviour or psychomotor agitation was observed. During hospitalization, the patient began to utter simple, single sentences. He did not express delusional content and denied hallucinations. The patient's suicide risk was low. During hospitalization, 2 attempts were made to perform an EEG, but due to the patient's lack of cooperation, they were unsuccessful. Laboratory tests did not reveal any significant abnormalities.

The patient was discharged with a recommendation to continue therapy in the Paediatric Rehabilitation Unit.

DISCUSSION

There have been isolated cases of secondary AE following neuroinfection. However, apart from the presented patient, no other cases of severe psychoorganic disorders linked to *Listeria* encephalitis have been reported to date. The specific source of LM infection in the patient was not identified; however, the development of a severe form of the disease may have been the result of autoimmune comorbidities and long-term treatment with immunosuppressive drugs.

The incidence of LM infections is higher among patients with inflammatory bowel disease compared to the general population [8]. Additionally, the literature indicates an increase in cases of listeriosis affecting the central nervous system (CNS) due to the rising number of organ and bone marrow transplants. These transplants typically require the use of immunosuppressive drugs, which hinder the body's ability to phagocytize and kill pathogens [9].

In the human body, LM first crosses the intestinal barrier and then spreads to other organs. It can penetrate the blood-brain barrier, especially in immunocompromised individuals, newborns, and pregnant women, leading to neuroinfection [10]. As a pathogen, LM is highly adaptable and can thrive in a wide range of environments, which makes the infection potentially life-threatening [11]. The pathogen can survive antibiotic treatment and persist within host cells, while the rare nature of invasive listeriosis complicates the identification of effective antibiotic regimens [12]. β -lactam antibiotics, particularly penicillins and ampicillin, are primarily used to treat listeriosis, either alone or in combination with gentamicin. Other effective antibiotics include trimethoprim-sulfamethoxazole and meropenem. Rifampicin, tetracycline, chloramphenicol, and fluoroquinolones are also used [13]. In the presented patient, cefuroxime was initially administered as an empirical treatment, before culture and PCR test results for CSF were available. This was then followed by cefotaxime and amikacin, which are ineffective against LM. This misstep could have contributed to the development of a severe form of the disease due to the lack of appropriate treatment. After receiving the test results, the antibiotic regimen was correctly adjusted to include ampicillin, gentamicin, and meropenem. However, despite this targeted antibiotic therapy, the patient's condition worsened, likely due to the prolonged duration of the inadequately treated infection.

Polytherapy with antibiotics may have contributed to the development of the *Clostridium difficile* infection. Several risk

factors for *Clostridium difficile* infection include hospitalization within the past 12 weeks and antibiotic therapy during the same timeframe, particularly with clindamycin, ampicillin, amoxicillin, third- and fourth-generation cephalosporins, and fluoroquinolones. Additional risk factors include being over 65 years of age, having chronic comorbidities, being immunosuppressed, having HIV infection, undergoing gastrointestinal surgery, and using acid-blocking medications [14]. In the presented case, the patient exhibited most of the risk factors associated with *Clostridium difficile* infection.

The classic clinical triad of meningitis includes fever, neck stiffness, and headache. If meningitis is suspected, a lumbar puncture should be performed as soon as possible to collect CSF. Both CSF culture and PCR have high diagnostic sensitivity. Early administration of antibiotics is crucial for improving the patient's clinical condition and increasing the chances of survival. Dexamethasone can help reduce inflammation in the CNS [15]. In the presented case, the patient initially presented with fever and headache before developing neck stiffness, indicating meningitis. Additional symptoms, such as drowsiness, vomiting, anisocoria, seizures, impaired speech, motor coordination issues, and altered consciousness, were likely caused by increased intracranial pressure due to cerebral oedema [16]. In the presented patient, dexamethasone and mannitol were used to treat the cerebral oedema. Corticosteroids are primarily beneficial for reducing cerebral oedema in cases of bacterial meningitis. However, differences in the therapeutic response and safety between hydrochlorothiazide and mannitol may occur. Therefore, the use of these medications requires close monitoring for adverse effects [17].

Due to the presence of psychiatric symptoms, secondary AE was suspected; however, no specific antibodies were detected in the CSF. AE is a significant diagnostic consideration in patients who present with new-onset altered mental status of unclear origin, especially following CNS infections [18]. The diagnosis of AE relies on a combination of a clinical history that aligns with AE in children and supportive diagnostic tests, which include – but are not limited to – antibody testing [19]. The main symptoms of AE include dyskinesia, low-grade fever, mental and behavioural disturbances, seizures, severe alterations in consciousness, and limb weakness [20]. In children diagnosed with AE, the most commonly identified autoantibodies are those against the N-methyl-D-aspartate receptor (NMDAR), myelin oligodendrocyte glycoprotein (MOG), and glutamic acid decarboxylase 65 (GAD65). Nevertheless, not all children with AE have identifiable autoantibodies [19]. Early initiation of first-line immunotherapy, which includes corticosteroids and plasma exchange, improves patient outcomes. Some evidence also suggests that second-line immunotherapies – particularly rituximab – can reduce the rate of relapse. However, the optimal duration of immunotherapy has not yet been established [21]. A study by Song et al. indicated that months of immunotherapy might be beneficial in treating AE [20]. In the presented case report, neither plasma exchange nor immunotherapy was administered to the patient due to the absence of detectable antibodies.

Patients with diagnosis of AE may present with psychiatric symptoms, such as behavioural changes, aggression, irritability, mood swings, hallucinations and severe sleep-wake cycle disorders. Epileptic seizures may also occur [22]. The patient in this case report developed aggression and behavioural changes. The psychiatrist suggested possible epileptic seizures; however, due to poor mental status and lack of cooperation

from the patient, it was impossible to perform a full EEG test.

A study by Xiaowei Qiu et al. analysed prognostic factors in patients with AE. It was determined that factors such as increased neutrophil-to-lymphocyte ratio (NLR) (>4,45), low lymphocyte count, low serum albumin, disturbances of consciousness, epileptic seizures, extrapyramidal symptoms, departure in electroencephalogram (EEG), changes in brain MRI, and infectious pulmonary complications, correlated with poor prognosis in analysed cases [23]. In this case report, the patient presented periodically increased NLR, low serum albumin (3,05–2,61 g/dl), disturbances of consciousness, and changes in brain MRI. These findings combined might suggest a poor outcome.

Abnormal brain MRI findings in AE include hyperintense lesions in the white matter of the temporal lobes, hippocampus, cingulate gyrus and insular cortex, as well as haemorrhage, restricted diffusion and post-contrast enhancement [23]. In our the presented case, MRI showed symmetrical hyperintense lesions in subcortical white matter of the temporal lobes, hippocampus, and insular cortex, which were consistent with the above-cited study. In addition, similar lesions were found in the subcortical white matter of the frontal lobes, left splenium of corpus callosum and periventricular area. Other findings included cerebral oedema and leptomeningeal enhancement.

Abnormal findings in MRI were first visible on the 4th day of hospitalization. Follow-up scans showed progression of the existing changes, as well as new hyperintense lesions in white matter. Abnormal brain CT and MRI findings in neurolisteriosis include leptomeningeal enhancement, brain abscesses, nodules suggestive of abscesses, diffuse cerebral oedema, non-specific changes in white matter, cerebral atrophy, dilated Virchow-Robin spaces, cerebral herniation, contrast-enhancing ventricles, hydrocephalus, radiological vasculitis, haemorrhage, ischemic images and haemosiderin deposition [24]. In the presented case, CT showed cerebral oedema, hypodense regions in the cerebral matter of the right temporal region and insula cortex, left temporal region, frontal region, parietal region and insula cortex. These changes, along with the previously mentioned MRI findings, are similar to other cases of neurolisteriosis.

CONCLUSIONS

The deterioration of the patient and progression of the disease to a severe form were influenced by inadequate empirical antibiotic therapy, which was continued for 3 days after the symptoms appeared until first PCR and culture of CSF was obtained at a higher-referral hospital. While supposing a patient has autoimmune diseases, particularly UC, and is being treated with immunosuppressive drugs, LM infection should be considered, as the intestines serve as the entry point for this infection. Therefore, antibiotics effective against LM should be used in the empirical treatment of patients with this medical history. Using PCR testing for multiple pathogens enables doctors to diagnose severe cases promptly and provide appropriate treatment.

REFERENCES

- Bento D, Bomar PA. *Listeria Monocytogenes*. In: StatPearls [Internet]. Treasure Island (FL): StatPearls Publishing, 2026.
- Xia X, Zhang L, Zheng H, et al. Clinical characteristics and prognosis of pediatric *Listeria monocytogenes* meningitis based on 10-year data from a large children's hospital in China. *Microbiol Spectr*. 2024;12(3):e0324423. <https://doi.org/10.1128/spectrum.03244-23>.
- Liu YC, Liao SK, Hung CC, et al. Invasive Listeriosis in End-Stage Kidney Disease (ESKD) Patients Receiving Long-Term Dialysis: A 21-Year Case Series. *Ther Clin Risk Manag*. 2024;20:437–47. <https://doi.org/10.2147/TCRM.S452090>.
- European Food Safety Authority (EFSA), European Centre for Disease Prevention and Control (ECDC). The European Union One Health 2023 Zoonoses report. *EFSA J*. 2024;22(12):e9106. <https://doi.org/10.2903/j.efs.2024.9106>.
- Lee JE, Cho WK, Nam CH, et al. A case of meningoencephalitis caused by *Listeria monocytogenes* in a healthy child. *Korean J Pediatr*. 2010;53(5):653. <https://doi.org/10.3345/kjp.2010.53.5.653>.
- Castellazzi ML, Marchisio P, Bosis S. *Listeria monocytogenes* meningitis in immunocompetent and healthy children: a case report and a review of the literature. *Ital J Pediatr*. 2018;44(1):152. <https://doi.org/10.1186/s13052-018-0595-5>.
- Villa A, Cour M, De Prost N, et al. Severe listeriosis in intensive care units: insights from a retrospective multicentric study. *Crit Care*. 2025;29(1):201. <https://doi.org/10.1186/s13054-025-05421-8>.
- Żak-Gołąb A, Dąbrowski K, Hrycek A. Listeriosis of central nervous system in patients with ulcerative colitis – case study. *Wiad Lek*. 2017;70(3 pt 2):685–8.
- Trachuk P, Marin Saquicela T, Levi M, et al. *Listeria* brain abscess in a patient with autoimmune hepatitis. *IDCases*. 2019;17:e00569. <https://doi.org/10.1016/j.idcr.2019.e00569>.
- Quereda JJ, Morón-García A, Palacios-Gorba C, et al. Pathogenicity and virulence of *Listeria monocytogenes*: A trip from environmental to medical microbiology. *Virulence*. 2021;12(1):2509–45. <https://doi.org/10.1080/21505594.2021.1975526>.
- Meireles D, Pombinho R, Cabanes D. Signals behind *Listeria monocytogenes* virulence mechanisms. *Gut Microbes*. 2024;16(1):2369564. <https://doi.org/10.1080/19490976.2024.2369564>.
- Ravindhiran R, Sivarajan K, Sekar JN, et al. *Listeria monocytogenes* an Emerging Pathogen: a Comprehensive Overview on Listeriosis, Virulence Determinants, Detection, and Anti-Listerial Interventions. *Microb Ecol*. 2023;86(4):2231–51. <https://doi.org/10.1007/s00248-023-02269-9>.
- Olaimat AN, Al Holy MA, Shahbaz HM, et al. Emergence of Antibiotic Resistance in *Listeria monocytogenes* Isolated from Food Products: A Comprehensive Review. *Compr Rev Food Sci Food Saf*. 2018;17(5):1277–92. <https://doi.org/10.1111/1541-4337.12387>.
- Piekarska A, Panasiuk A, Stepien PM. Clinical practice guidelines for *Clostridioides (Clostridium) difficile* infection and fecal microbiota transplant protocol – recommendations of the Polish Society of Epidemiology and Infectious Diseases. *Przeegl Epidemiol*. 2020;74(1):69–87. <https://doi.org/10.32394/pe.74.06>.
- Wall EC, Chan JM, Gil E, et al. Acute bacterial meningitis. *Curr Opin Neurol*. 2021;34(3):386–95. <https://doi.org/10.1097/WCO.0000000000000934>.
- Watanabe A, Shiota T, Tsuji T. Cerebral edema during hepatic encephalopathy in fulminant hepatic failure. *J Med*. 1992;23(1):29–38.
- Cook AM, Morgan Jones G, Hawryluk GWJ, et al. Guidelines for the Acute Treatment of Cerebral Edema in Neurocritical Care Patients. *Neurocrit Care*. 2020;32(3):647–66. <https://doi.org/10.1007/s12028-020-00959-7>.
- Kelley BP, Patel SC, Marin HL, et al. Autoimmune Encephalitis: Pathophysiology and Imaging Review of an Overlooked Diagnosis. *AJNR Am J Neuroradiol*. 2017;38(6):1070–8. <https://doi.org/10.3174/ajnr.A5086>.
- Cellucci T, Van Mater H, Graus F, et al. Clinical approach to the diagnosis of autoimmune encephalitis in the pediatric patient. *Neurology(R) neuroimmunology & neuroinflammation*. 2020;7(2). <https://doi.org/10.1212/NXI.0000000000000663>.
- Song LF, Wang L, Tang ZH, et al. [Clinical features of autoimmune encephalitis secondary to epidemic encephalitis B in 5 children]. *Zhongguo Dang Dai Er Ke Za Zhi*. 2023;25(3):302–7. <https://doi.org/10.7499/j.issn.1008-8830.2211082>.
- Trewin BP, Freeman I, Ramanathan S, et al. Immunotherapy in autoimmune encephalitis. *Curr Opin Neurol*. 2022;35(3):399–414. <https://doi.org/10.1097/WCO.0000000000001048>.
- Uy CE, Binks S, Irani SR. Autoimmune encephalitis: clinical spectrum and management. *Pract Neurol*. 2021;21(5):412–23. <https://doi.org/10.1136/practneurol-2020-002567>.
- Qiu X, Zhang H, Li D, et al. Analysis of Clinical Characteristics and Poor Prognostic Predictors in Patients With an Initial Diagnosis of Autoimmune Encephalitis. *Front Immunol*. 2019;10. <https://doi.org/10.3389/fimmu.2019.01286>.
- Keeratiratwattana A, Saraya AW, Prakkamakul S. Computed tomography and magnetic resonance imaging findings in central nervous system listeriosis. *Neuroradiology*. 2024;66(5):717–27. <https://doi.org/10.1007/s00234-024-03313-2>.