



Strike in a stroke – a unique case of highly successful treatment of a paediatric patient

Alicja Szklarska^{1,A-D}✉, Maria Suchcicka^{1,A-B,D}, Natalia Domańska^{1,D}, Małgorzata Bojarska^{1,D}, Karolina Iwanicka^{1,D}, Magdalena Chrościńska-Krawczyk^{2,A,E-F}

¹ Student Scientific Society at the Department of Paediatric Neurology, Medical University, Lublin, Poland

² Department of Paediatric Neurology, University Children's Hospital, Medical University, Lublin, Poland

A – Research concept and design, B – Collection and/or assembly of data, C – Data analysis and interpretation, D – Writing the article, E – Critical revision of the article, F – Final approval of the article

Szklarska A, Suchcicka M, Domańska N, Bojarska M, Iwanicka K, Chrościńska-Krawczyk M. Strike in a stroke – a unique case of a highly successful treatment of a paediatric patient. J Pre Clin Clin Res. 2025;19(4):164–168. doi:10.26444/jpccr/215960

Abstract

Introduction. Stroke is a rare condition in children, affecting 1–2 per 100 paediatric patients annually. Despite the low incidence, it is the leading cause of neurological disorders in this age group.

Case Report. An 8-year-old girl was admitted to the emergency department with reduced muscle strength, drooping of the left corner of the mouth, and sensory disturbances. Imaging studies revealed intracerebral haemorrhagic foci surrounded by oedema in the right frontal lobe, subarachnoid haemorrhagic foci, as well as ischemic changes in the left frontal lobe. Empiric pharmacotherapy with anti-coagulants, anti-oedematous agents and antibiotics was applied. After treatment and rehabilitation, substantial improvement was observed.

Conclusions. Management of strokes in paediatric patients poses significant challenges. Absence of well-established guidelines and randomized clinical trials in this age group often necessitates empiric therapy, which proved to be highly effective in the presented case.

Key words

pharmacotherapy, paediatric neurology, paediatric stroke, haemorrhagic stroke

INTRODUCTION

Paediatric strokes represent a significant cause of acquired neurological morbidity in the paediatric population. [1]. The most common cause of occurrence is an ischemic event or bleeding from cerebral vessels. Haemorrhagic strokes constitute about half of the cases, they are usually spontaneous intra-cerebral haemorrhages and non-traumatic subarachnoid haemorrhages [2]. Despite being rare conditions, it is reported that yearly 1–2,000 in 100,000 children experience some kind of a stroke [3], which are a leading cause of disability and mortality among children.

Stroke diagnosis is often delayed and can have dramatic consequences [4]. The post-stroke mortality rate is recorded at 3.1 in 100,000 children aged under one year, 0.4 in 100,000 children aged 1–4 and 0.2 in 100,000 children aged 5–14 [5]. The pathophysiological mechanisms of paediatric strokes are more extensive not yet fully understood, unlike adults, in whom strokes are often the result of cardiovascular diseases.

Symptoms indicating a stroke are similar to those in adults, the most of common them being hemiparesis (70–90% of cases), speech disorders (20–50%) and vision disorders (10–15%). Most often, the first imaging used for a probable stroke is computed tomography (CT scan) however, this is defective method, as it often does not reveal changes in the first 6 hours in arterial ischemic stroke. The most sensitive imaging method is magnetic resonance imaging (MRI) which is recommended when ischemic stroke is suspected. Nevertheless, this is not an ideal method, as it often requires

general anaesthesia of the child [6]. The guidelines for the most adequate therapy for paediatric strokes are still underdeveloped and are mainly based on the guidelines for the treatment of strokes in adults.

CASE REPORT

During the evening, an 8-year-old girl was reported to University Children's Hospital in Lublin, eastern Poland, from a local hospital due to numbness and muscle weakness in the lower extremities, the left upper extremity and sensory disturbances in the face, and drooping of the left corner of the mouth. A few hours earlier she had fallen to the floor while getting out of bed and reported the symptoms to her mother. Throughout the morning she had been irritable, anxious, crying, and in need of constant contact (more than usual) with her mother. On admission to hospital, the patient had limited verbal and logical contact, presented negative meningeal symptoms on neurological examination, and reduced muscle strength of the lower and left upper limbs which rendered the Romberg test impossible to perform.

In the previous year, the patient had frequently experienced various infections, and three weeks previously had suffered from sinusitis (clarithromycin and mometasone were included in the treatment). The girl no chronic diseases, had not been on permanent medication, and had not been previously hospitalised. The mother denied the occurrence of similar episodes in the past, declared vaccination according to the vaccination calendar, but not vaccinated against SARS-CoV-2. Due to a suspected vascular malformation or brain tumour, a head scan was ordered – computer tomography (CT).

✉ Address for correspondence: Alicja Szklarska, Student Scientific Society at the Department of Paediatric Neurology, Medical University, Lublin, Poland
E-mail: ala.szklarska@gmail.com

Received: 07.12.2025; accepted: 22.12.2025; first published: 31.12.2025

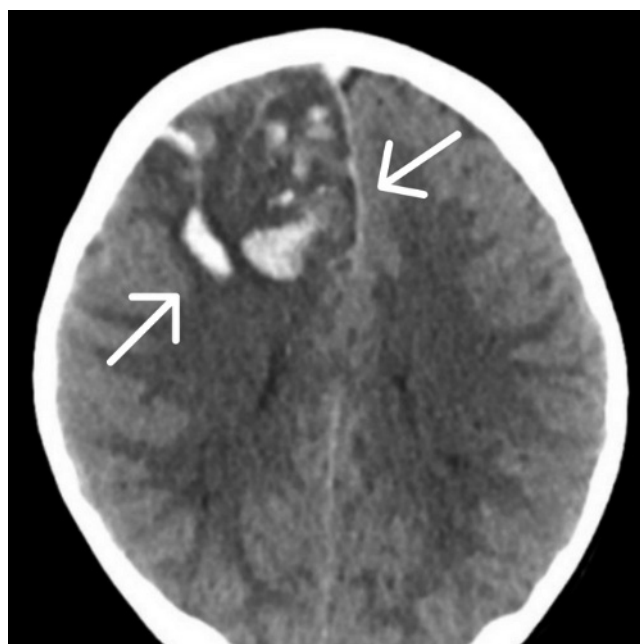


Figure 1. Head CT without contrast from first day of hospitalization showing foci of intracerebral haemorrhage and surrounding oedema ($54 \times 48 \times 40$ mm) in the right frontal lobe. Along the cerebral falx, features of subarachnoid haemorrhage and thrombosis of the superior sagittal sinus are visualised. There was a mass effect – the median line shifted by 6mm to the left side

The imaging test showed foci of intracerebral haemorrhage and surrounding oedema ($54 \times 48 \times 40$ mm) in the right frontal lobe [Fig. 1]. Along the cerebral falx, features of subarachnoid haemorrhage and thrombosis of the superior sagittal sinus were visualised. There was a mass effect – the median line shifted by 6mm to the left side. The differential diagnosis included stroke (ischemic, haemorrhagic, venous), intracerebral haemorrhage, brain tumour, vascular malformation and neuroinfections.

A few hours later, the girl's condition worsened and she was admitted to the Department of Surgery and Traumatology for suspected bleeding into a vascular malformation or brain tumour. A neurological consultation was ordered, which showed flaccid paresis of the left limbs. Central paralysis of the facial nerve on the left side was also observed, as well as limited abduction of the left eyeball.

On the same day, an MRI scan of the head with contrast was performed [Fig. 2,3], which also showed thrombosis of the sagittal sinus, as well as partial thrombosis of the left transverse sinus and features of extensive ischemic stroke of the left frontal lobe with progression of haemorrhagic lesions. Within the right frontal lobe, an extensive and heterogeneous area with various temporal foci of intracerebral haemorrhage and a surrounding zone of oedema (measuring $95 \times 60 \times 52$ mm – larger than in the CT scan taken previously – was visualized. These lesions protruded into the periphery of the corpus callosum, occupying the brain stem and causing its distortion, and produced a mass effect with a displacement of the median line by about 10mm to the left. There were no pathological areas of contrast enhancement inside the skull after contrast administration, nor pathology of the major cerebral arteries (aneurysm, haemangioma, arteriovenous malformation), but there were vascular signal defects in the peripheral arteries of the right hemisphere. During an urgent neurosurgical consultation, conservative treatment was recommended due to the remarkably substantial risk

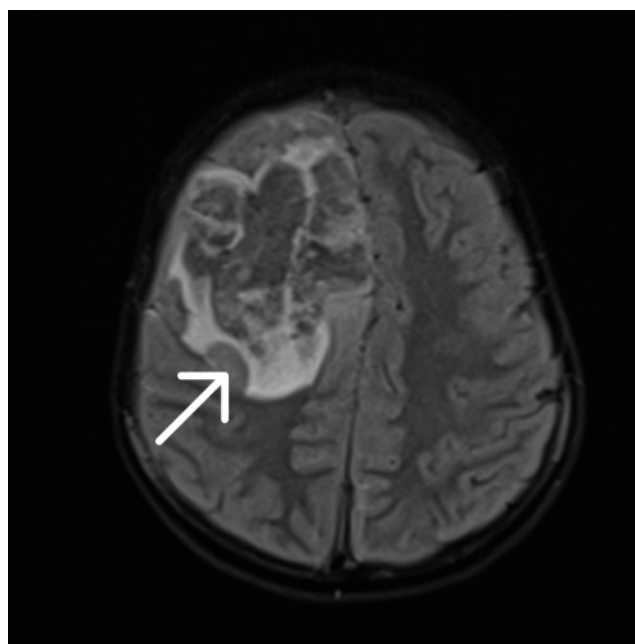


Figure 2. Head MRI with contrast from second day of hospitalization – an extensive and heterogeneous area with various temporal foci of intracerebral haemorrhage and a surrounding zone of oedema measuring $95 \times 60 \times 52$ mm

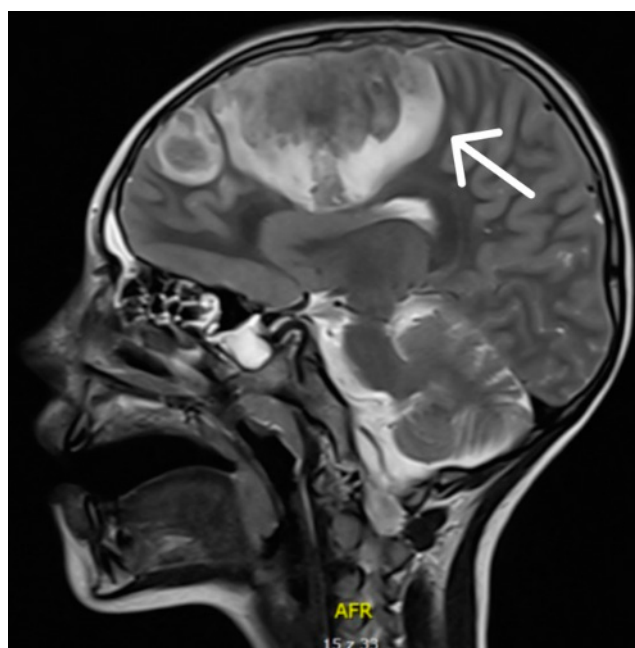


Figure 3. Head MRI with contrast from the second day of hospitalization, sagittal view

of massive intraoperative cerebral oedema during potential decompression treatment.

Imaging studies performed [Fig. 4] showed features of a left frontal lobe ischaemic stroke with progression of haemorrhagic lesions, mass effect and thrombosis of the superior sagittal sinus. Operative decompression surgery was considered to be associated with too high a risk of complications. Treatment was continued in the Department of Paediatric Neurology. It was decided to implement compulsory anti-coagulant treatment with low-molecular-weight heparin (neoparin 4000 IU heparin \times 10 pre-filled syringes), acetosalicylic acid, cyclonamine

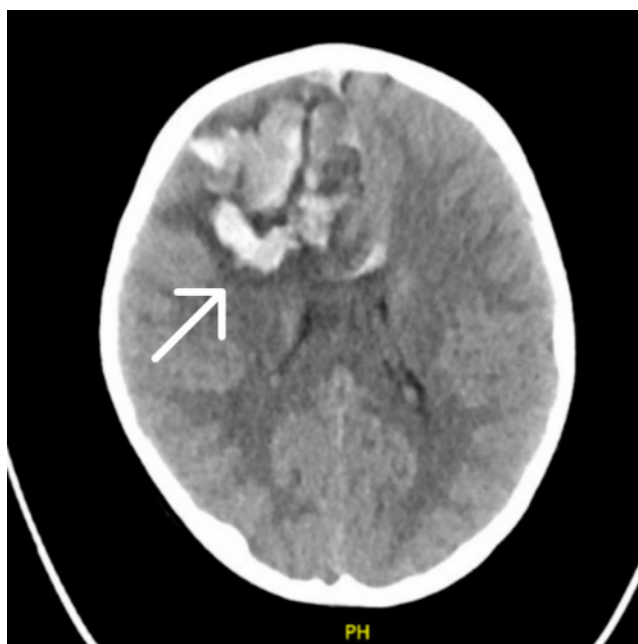


Figure 4. Head CT without contrast showing progression of haemorrhagic lesions

and anti-oedematous mannitol. In addition, antibiotic therapy was carried out in view of a positive test for Lyme disease confirmed by Western Blot with cefotaxime and dexamethasone administered, and analgesic treatment with paracetamol also administered.

In the blood count performed, only a reduced platelet count (75000/ μ l) was observed. The patient was transfused with 1 unit of platelet cell concentrate. In addition, inflammatory and coagulation markers were present in the laboratory tests. On admission to the the Neurology Clinic, C-reactive protein (CRP) was 10.11 mg/dl, D-dimers – 24,898 ng/ml (with a normal of <500) which decreased after two days (CRP- 3.62 mg/dl, D-dimers – 6,555 ng/ml). Prothrombin time (PT) and international normalised ratio (INR) were also elevated.

During the second night, the patient's general condition again deteriorated – she reported headaches and hemiparesis of limbs. An urgent non-contrast CT scan of the head showed a re-expansion of the area with foci of intracerebral haemorrhage and a surrounding zone of oedema in the right cerebral hemisphere (103x69x64mm) and the appearance of new haemorrhagic foci – along the trunk of the corpus callosum passing into the left cerebral hemisphere.

On the third day of hospitalisation, a re-MRI scan with contrast was performed. Compared with the previous examination, an additional thrombosis of the left internal jugular vein and ischaemic lesions in the left parietal lobe (17x15mm) and posterior part of the corpus callosum were visualised.

The patient remained in logical contact with the environment throughout, but was transferred to the intensive care unit for possible induction into a pharmacological coma. A retrospective reconstruction of the Paediatric National Institutes of Health Stroke Scale (PedNIHSS) based on medical records was performed. The estimated score was approximately 6–7 points on admission to the Paediatric Neurology Department, which increased to 9–10 points at clinical deterioration, and on admission to the Intensive Care Unit decreased to 5–6 points after one week of treatment,

and at the time of discharge from hospital – 0–1 point. Anti-coagulant treatment with neoparin, treatment of cerebral oedema with mannitol and furosemide, antibiotic therapy with ceftriaxone and vancomycin and antifungal prophylaxis with fluconazole were continued. Anti-SARS-CoV-2 antibodies in IgG class were detected. On admission to the Intensive Care Unit, D-Dimers were 4221ng/ml, and decreased to 3855ng/ml after one week – on the day of discharge. During the patient's stay on the ward, a cardiology consultation was ordered, which confirmed bradycardia of central origin due to CNS bleeding. In the following days, the girl's condition steadily improved – limb movements, return of speech and recollection of events prior to the stroke were observed.

The final contrast-enhanced brain MRI [Fig.u5: Comparison of MRI scans upon admission and discharge] performed during hospitalization demonstrated further evolution of the hemorrhagic lesions (103x50x53 mm) and a marked regression of thrombotic changes, with near-complete recanalization of the superior sagittal sinus and significant resolution of thrombosis of the left transverse and sigmoid sinuses. No new haemorrhagic foci were identified. The ventricular system was not dilated, and cerebral oedema was less pronounced compared with the previous examination.

At the time of discharge, following 45 days of hospitalization, the patient was in good general condition, haemodynamically and respiratory stable. She was alert, cooperative, and fully oriented, with preserved higher cortical functions. No disturbances of consciousness or clinical signs of raised intracranial pressure were observed. The patient denied headache or other pain symptoms. Neurological examination demonstrated significant clinical improvement compared to admission. The patient ambulated independently with a physiological gait pattern, without evidence of ataxia or postural instability. She was able to perform heel-and-toe walking, as well as squatting without external support. A mild residual left-sided hemiparesis persisted, involving both the upper and lower extremities, with muscle strength graded at approximately 4/5 on the Medical Research Council (MRC/Lovett) scale, while strength on the contralateral side was preserved – 5/5. Muscle tone was normotonic, and deep tendon reflexes were symmetric, with no pathological reflexes elicited. Sensory examination revealed intact superficial and deep sensation. Cranial nerve examination was unremarkable. No cerebellar signs, coordination deficits, or meningeal signs were present. Overall, the neurological status at discharge was stable, with ongoing functional recovery and only minimal residual motor deficits, warranting continuation of structured outpatient neurorehabilitation.

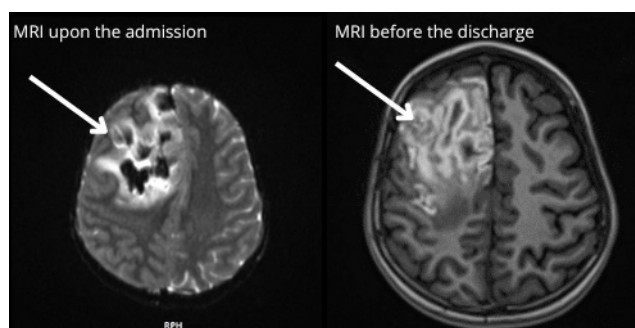


Figure 5. Comparison of the MRI scans upon the admission and a week before discharge from hospital

In the final phase of hospitalization, laboratory investigations demonstrated a progressive normalization of abnormalities. Initially markedly elevated D-dimer concentrations showed a gradual decline under anti-coagulant therapy. Fibrinogen levels and global coagulation parameters (activated partial thromboplastin time [APTT], prothrombin time [PT], and international normalized ratio [INR]) remained stable within therapeutic or reference ranges. Inflammatory markers, including C-reactive protein, remained low, with no laboratory evidence of ongoing systemic inflammation or infection. Haematological parameters were largely within reference limits. Biochemical analyses revealed transient elevations in hepatic transaminases as well as amylase and lipase activity, without clinical or imaging evidence of hepatic or pancreatic pathology, and with a clear downward trend toward normalization. Renal function indices and serum electrolyte concentrations remained within normal ranges throughout the observation period.

The patient was advised to take enoxaparin twice daily at a dose of 30 milligrams subcutaneously for two months. She currently remains under neurological follow-up.

The patient was consulted in a rehabilitation Outpatient Clinic, where therapeutic exercises were recommended; hospital admission, however, was not required. Furthermore, follow-up assessments were scheduled at the Paediatric Neurology Department under a one-day admission protocol. A follow-up contrast-enhanced magnetic resonance imaging of the brain was scheduled for one month and two months after hospital discharge. The examinations [Fig. 6: Follow-up head MRI] showed further regression of the lesions, with complete recanalization of the left transverse sinus and left sigmoid sinus, as well as near-complete recanalization of the left internal jugular vein.

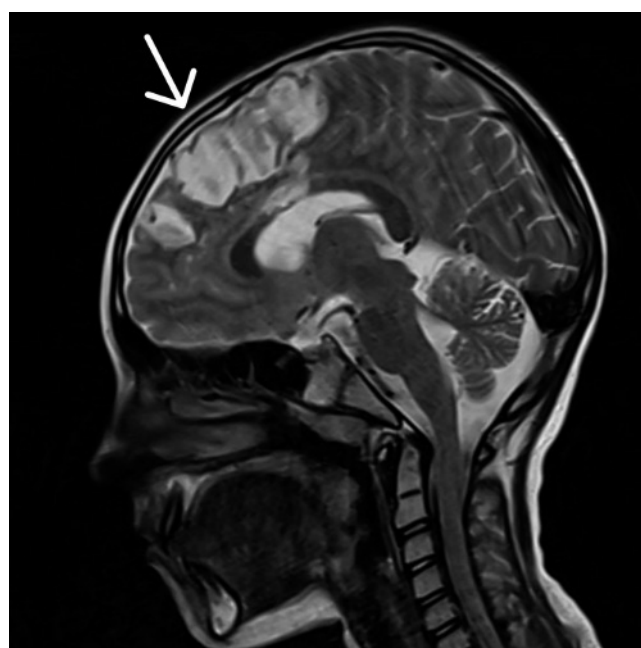


Figure 6. Follow-up head MRI showing regression of the haemorrhagic and thrombotic changes

DISCUSSION

Paediatric strokes remain both a diagnostic and therapeutic challenge. Their diagnosis is often delayed since the symptoms may differ in comparison to the ones in adults. The risk factors also vary in these age groups, in adults the most common risk factor is atherosclerosis, whereas in children both the risk factors and the pathophysiology of the strokes' occurrence are not yet fully understood. Moreover, their treatment procedures are highly variable, depending on the case, its symptoms and causes. Studies conducted throughout the years indicate a morbidity rate of about 60% and a considerable risk of neurocognitive deficits after the incident.

The choices of interventions are based on the opinions of experts due to the absence of clear guidelines and protocols for their therapy [7]. Decompressive craniotomy, although successfully performed in adults with strokes affecting the cerebral hemispheres, is a questionable choice for paediatric patients due to the lack of randomized clinical trials in children [8]. This procedure often leads to several complications, including neurological deficits; however, it has not yet been proved whether they are a result of a stroke or of the craniotomy itself [9]. Nevertheless, patients who do not require neurosurgical operations are a rarity in this age group. In the presented case, the risk of a massive intra-operative cerebral oedema was too high to decide to perform decompressive craniotomy. Instead, the patient was treated pharmacologically only, thus avoiding any neurosurgical interventions. A combination of drugs used, including anti-coagulants, anti-oedema drugs, antibiotics and antifungal prophylaxis, allowed the treatment to act on several levels, thus not only substituting, but also surpassing the possible outcome of a surgical treatment. The treatment lasting for over a month, accompanied with rehabilitation resulted in a spectacular improvement of the patient's condition. This treatment was highly empiric, monitored over the time to modify the drug choice and doses, adjusting to the pace of the haemorrhagic and oedemic changes. The brief time between the appearance of symptoms and the beginning of treatment was also crucial, since children have a higher rate of surviving a stroke without serious complications compared to adults with similar lesions, if the diagnosis is made quickly enough [10].

The lack of thrombolytic treatment is another advantage of the therapy used. The treatment used for adult strokes might be unsuitable for children, making the intravenous thrombolysis a questionable choice for this age group [11]. The most recent guidelines allow the usage of rTPA in children from two years of age, although the benefits of this therapy remain uncertain since children have a higher level of tissue plasminogen inhibitor than adults, and may not benefit from this therapy to the same extent as the older age groups [12]. Avoiding the thrombolysis additionally diminished the risk of further complications.

The presented case shows an example of a phenomenally successful treatment for a complicated case of paediatric stroke, in which the patient survived without any neurological deficiencies and without the need for neurosurgical treatment, thus indicating a lot of potential in this type of therapy. The eligibility criteria for this treatment are uneven and might not lead to success in every case, nevertheless, their effectiveness can provide the cessation of both the symptoms and their further complications.

CONCLUSIONS

Although paediatric strokes occur rarely, their treatment is a challenge on various levels. The lack of randomized controlled trials and guidelines in treatment in this age group results in many approaches in empiric therapy. The combined therapy used in the presented case enabled the patient not only to avoid a neurosurgical operation, but also to fully recover from a massive vascular incident.

REFERENCES

1. Sporns P, Fullerton H, Lee S, et al. Childhood stroke. *Nat Rev Dis Primers*. 2022;8(1):12.
2. Mirsky DM, Beslow LA, Amlie-Lefond C, et al. Pathways for neuroimaging of childhood stroke. *Pediatr Neurol*. 2017;69:11–23.
3. Ferriero DM, Fullerton HJ, Higashida RT, et al. Management of stroke in neonates and children: a scientific statement from the American Heart Association/American Stroke Association. *Stroke*. 2019;50(3):e51–e96.
4. Buckowski A, Rose E. Paediatric stroke: diagnosis and management in the emergency department. *Pediatr Emerg Med Pract*. 2019;16(11):1–20.
5. Krishnamurthi RV, deVeber G, Feigin VL, et al. Stroke prevalence, mortality and disability-adjusted life years in children and youth aged 0–19 years: data from the global and regional burden of stroke 2013. *Neuroepidemiology*. 2015;45(3):177–89.
6. Oborska Z, Urban P, Wychowaniec K, Józwiak S. Paediatric stroke – a review of current guidelines for diagnosis and treatment. *Neurol Neurochir Pol*. 2020;54(2):116–24.
7. Buckowski A, Rose E. Paediatric stroke: diagnosis and management in the emergency department. *Pediatr Emerg Med Pract*. 2019;16(11):1–20.
8. Omay SB, Carrión-Nessi F, Nacar A, et al. Decompressive hemicraniectomy for ischemic stroke in the paediatric population. *Neurosurg Rev*. 2013;36(1):21–4.
9. Lehman LL, Khoury JC, Taylor JM, et al. Characteristics and outcome in children with craniectomy following acute ischemic stroke in the International Paediatric Stroke Study. *J Child Neurol*. 2019;34(12):765–9.
10. Sporns PB, Fullerton HJ, Lee MJ, et al. Impact of edema formation on functional outcome in paediatric stroke patients. *Eur J Neurol*. 2023;30(1):150–4.
11. Sun LR, Lynch JK. Advances in the diagnosis and treatment of paediatric arterial ischemic stroke. *Neurotherapeutics*. 2023;20(3):633–54.
12. Mastrangelo M, Giordo L, Ricciardi G, et al. Acute ischemic stroke in childhood: a comprehensive review. *Eur J Pediatr*. 2022;181(1):45–58.