



Cryoapplication and laser treatment in oral precancerous lesions – case report and literature review

Wojciech Świątkowski^{1,A-C,E}, Kamila Smala^{2,A-D}, Emanuela Bis^{2,A-D},
Mansur Rahnama-Hezavah^{2,E-F}

¹ Department and Clinic of Maxillofacial Surgery, Medical University, Lublin, Poland

² Department of Dental Surgery, Medical University, Lublin, Poland / Student Research Group at the Department of Dental Surgery, Medical University, Lublin, Poland

A – Research concept and design, B – Collection and/or assembly of data, C – Data analysis and interpretation, D – Writing the article, E – Critical revision of the article, F – Final approval of the article

Świątkowski W, Smala K, Bis E, Rahnama-Hezavah M. Cryoapplication and laser treatment in oral precancerous lesions – case report and literature review. J Pre Clin-Clin Res. doi: 10.26444/jpccr/195944

Abstract

Cryoapplication, a rarely used dental technique, freezes lesional tissues to disrupt them at the cellular level. The technique is minimally invasive and suitable for specific mucosal lesions, offering a conservative option for oral pre-cancers. Studies show that cryotherapy is promising for managing pre-cancerous lesions with few complications. Cryogun and cotton-swab cryotherapy effectively regress oral leukoplakia lesions. Cryotherapy advantages include bloodless application and less scarring potential, making it suitable for mucosal alterations. More research is needed to define indications, optimize use in oral pre-cancers, and address limitations to enhance outcomes compared to alternatives. This paper presents a case of treating white rough lesions on a 59-year-old female's oral mucosa using cryoapplication and laser, and reviews their efficacy in managing oral leukoplakia and pre-cancerous conditions.

Key words

cryotherapy, laser treatment, leukoplakia, pre-cancerous, cryoapplication, oral pre-malignant

INTRODUCTION

Cryoapplication, a method rarely used in dental practice, involves the local destruction of lesional tissues by freezing *in situ*. This technique can be implemented using either an 'open' or a 'closed' system, causing disruption at the cellular level. Lesional tissues undergo destruction primarily through mechanisms such as disruption of the cell membrane, cellular dehydration, enzyme and protein damage, cell swelling and rupture, thermal shock injury to cells, vasculature damage, and immune-mediated cytotoxicity [1]. Cryotherapy represents a minimally invasive technique with moderate complications, suitable for treating specific mucosal lesions of the buccal cavity [2]. Through careful patient selection, cryotherapy emerges as a simple, safe, easy, conservative, and acceptable treatment option for certain benign oral lesions and oral pre-cancers [1].

Cryotherapy finds application in addressing various oral pre-cancerous conditions, including oral leukoplakia (OL), oral verrucous hyperplasia (OVH), oral verrucous carcinoma (OVC), and oral squamous cell carcinoma (OSCC) [1]. Oral leukoplakia is among the most prevalent oral pre-cancerous changes, potentially undergoing malignant transformation in certain cases [3]. Since many leukoplakias are asymptomatic, treatment decisions are primarily based on the precancerous nature of the lesion [3]. Indications for this treatment modality also include pain management [2].

There are multiple methods of cryoapplication. The study by Liu highlights cryogun cryotherapy as effective for oral leukoplakia [4], while Chuan-Hang Yu explores the use of cotton-swab cryotherapy (CSC), more commonly used in OL treatment for skin lesions [5]. Beyond cryotherapy, alternative non-surgical approaches to OL treatment include vitamin A and retinoids, bleomycin, mixed tea and beta carotene [3]. Surgical excision, cryotherapy, electrosurgery, and laser treatment represent common modalities for the management of pre-malignant lesions [6].

When treating precancerous lesions in the oral cavity, the choice between cryotherapy and laser therapy depends on several factors, including the lesion's characteristics (as well as intra-oral localization) and treatment goals. Cryotherapy is often recommended for smaller, superficial lesions such as homogeneous leukoplakia. This method is minimally invasive, cost-effective, and typically results in reduced post-operative pain and scarring, making it suitable for patients concerned about recovery. In contrast, laser therapy, particularly using CO₂ lasers, is more appropriate for larger or dysplastic lesions. It offers enhanced precision and better control over bleeding, which is crucial when dealing with high-risk areas. Additionally, laser therapy can effectively minimize recurrence rates in such complex lesions as erythroplakia. Thus, the decision to use either cryotherapy or laser treatment should be guided by the specific clinical scenario and the desired outcomes [3, 7, 8].

The aim of this study is to conduct a literature review focusing on cryoapplication and laser as a treatment modality for pre-cancerous alterations in the area of the oral cavity.

✉ Address for correspondence: Kamila Smala, Student Research Group at the Department of Dental Surgery, Medical University, Chodźki, 20-093 Lublin, Poland
E-mail: kama363669@gmail.com

CASE REPORT

A 56-year-old female patient presented to the oral health specialist due to lesions on her tongue, which had appeared approximately three months earlier, and persistent dry mouth symptoms for the past ten months. Clinical examination revealed wart-like lesions on her tongue and desquamative inflammation of the oral mucosa. One and a half months prior, she had visited her family doctor, where a swab for fungal infection returned negative. The patient has a medical history of hypertension, type 2 diabetes, and underwent stent placement for angina ten months ago. She takes medications such as Acard, Areplex, Metformin, insulin preparation, Dilzem, Diver, Toluca, Heparegen, Linefor, Kalipoz, Molsidomine, Agen, and Torvacard, and is currently participating in a double-blind study in which she is treated with Siofor and insulin under the supervision of the Cardiology Clinic. The patient does not smoke or drink alcohol. At the time of the visit, mouth rinsing with evening primrose and black cumin oil was recommended, along with the removal of tongue lesions by a specialist ENT physician.

About one and a half years later, the patient returned to the Department of Oral Medicine with lesions on the right maxillary tuberosity. She reported that previous tongue foci were removed using laser therapy in a private clinic. Oral examination revealed diffuse white leukoplakia-like lesions in the right maxillary tuberosity extending to the cheek mucosa [Fig. 1]. Small and painless foci were also visible on the mucosa of the left cheek and tongue. A biopsy was ordered by a specialist in dental surgery, and the patient was advised to use vitamin mouthwash and oil treatment. One month later, the patient returned to the Department of Oral Surgery for a biopsy of exophytic lesions on both sides of the cheek, and on the right side of the mandibular region. Following extended diagnostics and cardiology consultation, a VelScope examination revealed fluorescence [Fig. 2]. A 10×7 mm mass was detected on the dorsal surface of the tongue. Six months earlier, the patient underwent a biopsy elsewhere for viral papilloma-like lesions that confirmed histopathologically. The histopathological analysis of the recent tongue lesion biopsy was non-diagnostic. A local anaesthetic procedure using articaine with adrenaline was performed for diagnostic excision of the tongue lesion and mucosal biopsy of the right maxillary. The wound was sutured in layers and Myzotec applied. After about a month,

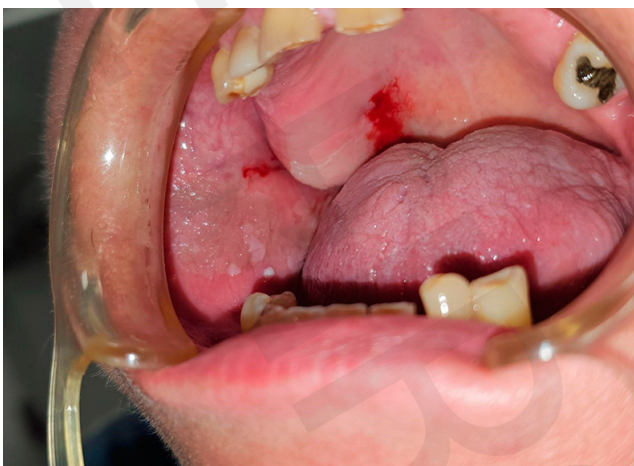

Figure 1. Leukoplakia-like foci on the right cheek and right maxillary tuberosity

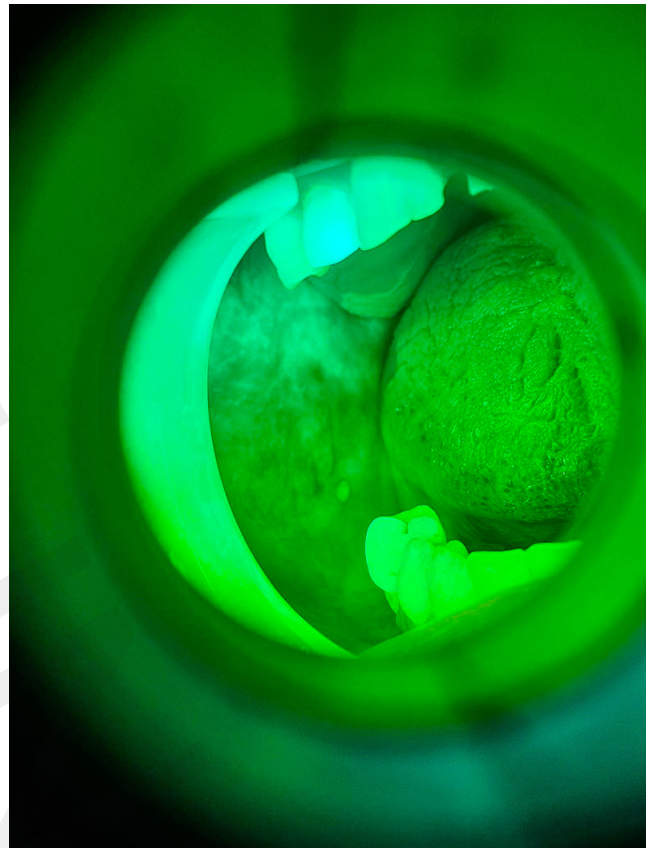


Figure 2. Fluorescence in VelScope examination

the follow-up visit confirmed proper healing of the excision site, and the histopathological result showed features of excessive keratinization and parakeratosis. Due to the extent of the lesions, laser treatment was recommended but declined by the patient.

After discussing alternative treatments, it was agreed that if cryotherapy proved ineffective, laser therapy would be administered at a later stage. The patient consented to this treatment plan, which allowed for cryotherapy to be the primary intervention, with laser therapy reserved as a secondary option in the event of inadequate response. This approach ensured that patient preferences were respected while maintaining a flexible treatment strategy to address potential recurrences.

During the same month, the patient underwent cryotherapy for leukoplakia-like foci on the right cheek and right maxillary tuberosity and left cheek under local anesthesia with lignocaine and noradrenaline [Fig.1]. In each of the three sessions of cryotherapy application, a spray probe was used to deliver precisely applications, each lasting 15 seconds. Between each application, a pause was observed to allow for complete thawing of the treated area before proceeding with the next cycle. After the procedure, Glimbax rinses and a follow-up appointment were advised after four days. After one week, necrotic epithelium characteristics were observed, followed by healing after seven days and significant healing after four weeks, reducing epithelial opacity. It was decided to continue treating the previously untreated areas with cryotherapy, repeated under local anaesthetic on the soft and hard palate on the right, the maxillary mass, the buccal fold, and the toothless mandibular area on the right [Fig. 3 and 4].

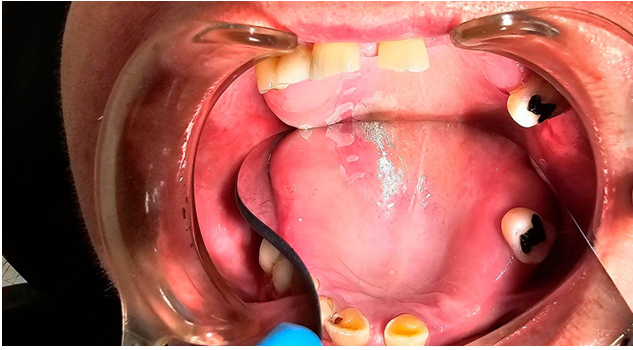

Figure 3. Status post-cryotherapy treatment after approximately one year after the first visit applied to leukoplakia-like spots

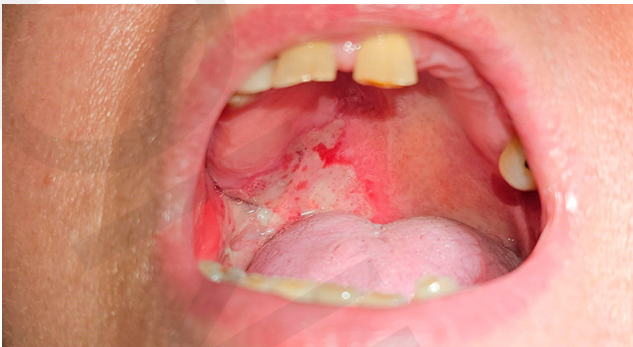

Figure 4. Status post-cryotherapy treatment after approximately one year since the first visit applying to leukoplakia-like spots

One week later, necrotic epithelium was evident at the freezing site, with mild pain and recession tendencies. At one month of follow-up, reduced epithelial opacity and scattered areas of mottled epithelium were observed, requiring adjunct laser diode treatment on the interdental papillae of teeth 43, 44, and 45, performed two months later. The ellexion claros laser was configured with specific operational parameters to optimize efficacy in clinical applications. The laser was set with a pulse output of 30W, a frequency of 20,000 Hz, and a pulse duration of 10 μ s. This combination achieves a peak power output of 6.15 W.

The following month, the patient, once more, underwent the aforementioned procedures due to recurrence of lesions on the mucous membrane of the cheek and the lower lingual alveolar. [Fig. 5] The removal of the lesion with a laser resulted

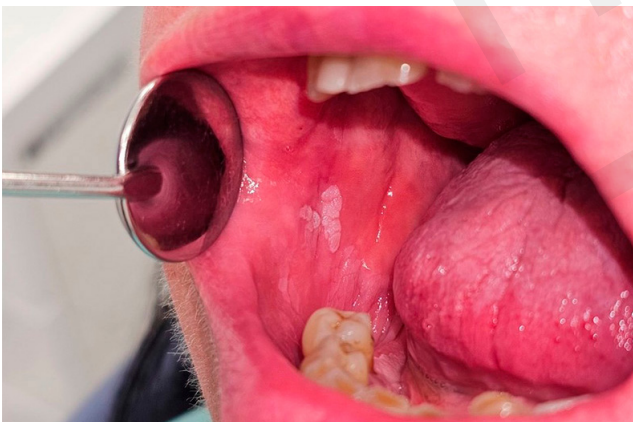

Figure 5. Recurrence of leukoplakia-like changes one month after the last appointment. Visible changes on the mucous membrane of the cheek and the mandibular alveolar process from the lingual side

in charring of the mucous membrane of the cheek and the mandibular alveolar process. The treatment approach was modified from cryotherapy to laser therapy due to issues with recurrency. Simultaneously, at the time of the patient's initial consultation, oral lesions presented with WHO grade 2 leukoplakia and following several cryotherapy applications to treat recurrences, the lesions displayed a regression to grade 1 leukoplakia. This progressive reduction in leukoplakia grading suggests that cryoapplication effectively reduced the severity of the lesions. The lesion remains under healing treatment and requires further observation [Fig. 6 and 7].

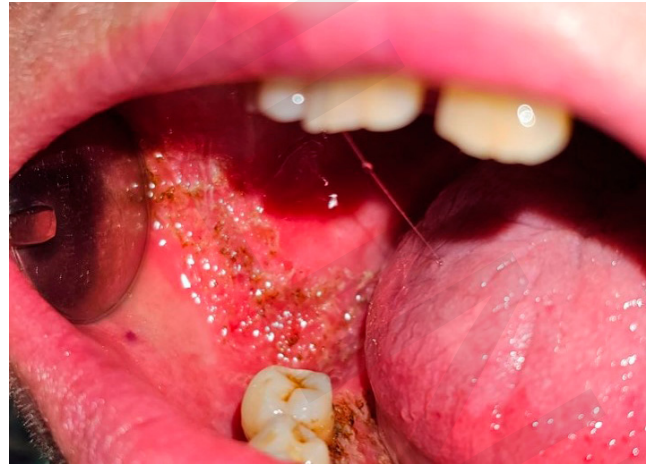

Figure 6. Status post-laser treatment of the latest lesions in the oral cavity

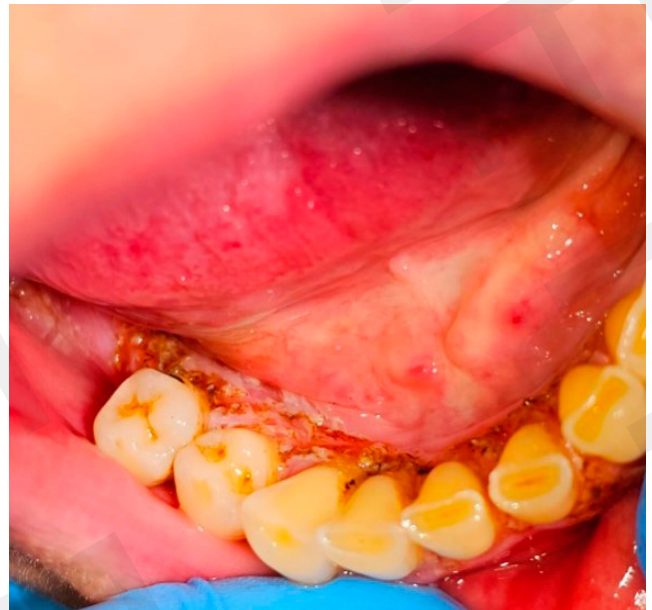

Figure 7. Status post-laser treatment of the latest lesions in the oral cavity

DISCUSSION AND LITERATURE REVIEW

The patient is taking a range of medications, the side-effects of which may manifest in the oral cavity with varying frequencies. For instance, Clopidogrel, found in the medication Areplex, may cause stomatitis and lichen planus with very low or unknown frequency. The active ingredient diltiazem, present in Dilzem, is very rarely associated with gingival overgrowth after the completion

of therapy. Regarding active substances such as torasemide in Diuver, telmisartan in Tolura, and pregabalin in Linefor, dry mouth is observed infrequently. Amlodipine, in the drug Agen, infrequently causes dry mouth and very rarely leads to gingival overgrowth. Atorvastatin in Torvacard, on the other hand, often causes inflammation of the nasal and pharyngeal mucosa. The remaining medications taken by the patient do not have significant side-effects that are documented in the oral cavity.

It was suspected that exogenous factors, particularly medications, may contribute to the unusually high recurrence rate of the lesions. To ensure timely detection and management of any re-emergence of symptoms, it is essential that the patient be monitored with follow-up appointments at least every three months. This monitoring plan allows for early intervention if recurrence is observed, helping to tailor treatment adjustments based on lesion behaviour and potential exogenous influences.

The application of cryotherapy emerges as a promising approach in treating precancerous lesions within the oral cavity, serving as an alternative treatment modality. Several authors emphasize that cryotherapy is a simple, safe, conservative, and effective method in treating lichenoid changes of the oral mucosa [4, 5, 9]. Kawczyk-Krupka et al. compared photodynamic therapy and cryotherapy, underscoring their potential as alternative methods for the traditional surgical treatment of oral leukoplakia. Furthermore, the study indicated that cryotherapy is slightly more effective than photodynamic therapy [10]. The main advantages of cryotherapy are its bloodless application, ability to alleviate pain, and the potential for gentle scar formation in mucosal changes [11].

Chen Q et al. refer to a comparative study which suggests that cryotherapy with a cryogun requires fewer mean treatments than cotton-swab cryotherapy to achieve complete regression of oral leukoplakia lesions. Complete regression was achieved in all 60 oral leukoplakia lesions after cryotherapy using a cryogun, with a significantly lower mean number of treatments (3.1 ± 1.3) compared to cotton-swab cryotherapy (mean number of treatments, 6.3 ± 3.8) [12]. Furthermore, Chen et al. showed the findings from a retrospective study on cryosurgery which encompassed 72 cases of oral leukoplakia and adjacent smoking-induced melanosis lesions located on the buccal mucosa. Over a mean follow-up period of 18 months (ranging from 3 – 41 months), no instances were observed of malignant transformation in the treated lesions. Notably, the study included eight cases (11.1%) with high-grade dysplasia (seven moderate, one severe), suggesting the need for cautious interpretation due to the relatively short follow-up period and the absence of final clinical endpoints in a subset of lesions [4].

Ashutosh et al. studied 60 patients with oral potentially malignant disorders, such as oral lichen planus, homogeneous leukoplakia, non-homogenous leukoplakia and erythroplakia, in which four different surgical approaches were employed: cryosurgery, conventional scalpel procedures, diode laser surgery, and CO₂ laser surgery. In summary, the study findings suggested that cryotherapy may yield more favourable clinically significant outcomes compared to laser therapy [11]. However, following cryosurgery for lesion removal, recurrence can also be quite frequently observed [13].

Observations from a study by Natekar et al. indicate the effectiveness of all three surgical modalities, including

cryotherapy, in treating oral leukoplakia lesions. However, laser therapy (CO₂ and diode) appeared to offer better clinically significant results than cryotherapy [10].

Based on the case of the 56-year-old female patient, it is also worth considering the effectiveness of cryotherapy and laser use, although challenging to compare clinically due to the patient having undergone both methods.

CONCLUSIONS

Cryotherapy, although rarely used in dental practice, emerges as a viable option to treat specific mucosal lesions and pre-cancers of the buccal cavity, and shows similar efficacy relative to other modalities such as photodynamic therapy and laser therapy. Despite some limitations and disappointing outcomes in certain cases, cryotherapy offers such advantages as bloodless application and the potential for scar formation, making it a valuable tool in managing mucosal changes, especially superficial ones.

Through various studies, cryogun cryotherapy and cotton-swab cryotherapy have demonstrated effectiveness in achieving complete regression of oral leukoplakia lesions, with cryogun cryotherapy showing particular promise in requiring fewer treatments for regression. Additionally, cryotherapy has shown positive outcomes in treating pre-cancerous lesions without malignant transformations or severe complications, thus providing an alternative to traditional surgical methods. Both modalities, cryoapplication and laser, are valuable tools in treating oral pre-cancers, and their complementary use can optimize outcomes. Further research and clinical trials are necessary to establish precise indications and optimize the use of these methods in the treatment of oral pre-cancerous conditions.

REFERENCES

1. Yu CH, Lin HP, Cheng SJ, Sun A, Chen HM. Cryotherapy for oral precancers and cancers. *J Formos Med Assoc.* 2014 May;113(5):272–277. doi:10.1016/j.jfma.2014.01.014. PMID:24560447
2. Trichard S, Dantony E, Maucourt-Boulch D, Gueugniaud P, Piriou V, Ecohard R, Busseuil C. Essai randomisé évaluant l'utilisation de la cryothérapie seule ou en association avec des antalgiques dans la prise en charge de la douleur en traumatologie d'urgence. *Ann Anat.* 2016;6:1–8. doi:10.1007/s13341-016-0692-2
3. Lodi G, Franchini R, Warnakulasuriya S, Varoni EM, Sardella A, Kerr AR, Carrassi A, MacDonald LCI, Worthington HV. Interventions for treating oral leukoplakia to prevent oral cancer. *Cochrane Database Syst Rev.* 2016;(7). doi:10.1002/14651858.CD001829.pub4
4. Liu W, Zhang X, Shi L, Shen X. Whether cryosurgery for oral premalignant lesions influences the outcome of malignant transformation. *Int J Surg.* 2023 Oct;109(10):3219–3221. doi:10.1097/JS9.0000000000000549
5. Yu CH, Chen HM, Chang CC, Hung HY, Hsiao CK, Chiang CP. Cotton-swab cryotherapy for oral leukoplakia. *Head Neck.* 2009 Aug;31(8):983–988. doi:10.1002/hed.21055. PMID:19283844
6. Arora KS, Bansal R, Mohapatra S, et al. Prevention of malignant transformation of oral leukoplakia and oral lichen planus using laser: an observational study. *Asian Pac J Cancer Prev.* 2018 Dec;19(12):3635–3641. doi:10.31557/apjcp.2018.19.12.3635. PMID:30583693; PMCID:PMC6428544
7. Condor D, Culciçchi C, Blum R, Baru O, Buduru S, Kui A, Tığ I. A Review of CO₂ Laser-Mediated Therapy for Oral Mucosal Lesions. *Applied Sciences.* 2021;11(16):7744. https://doi.org/10.3390/app11167744
8. Natekar M, Raghuvver HP, Rayapati DK, Shobha ES, Prashanth NT, Rangan V, Panicker AG. A comparative evaluation: oral leukoplakia surgical management using diode laser, CO₂ laser, and cryosurgery. *J Clin Exp Dent.* 2017 Jun;9(6). doi:10.4317/jced.53602. PMID:28638555; PMCID:PMC5474334

9. Pandey A. Cryotherapy for oral potentially malignant disorders. *Bioinformation*. 2023;19:1377–1382. doi:10.6026/973206300191377
10. Kawczyk-Krupka A, Waśkowska J, Raczkowska-Siostrzonek A, Kościarz-Grzesiok A, Kwiatek S, Straszak D, Latos W, Koszowski R, Sieroń A. Comparison of cryotherapy and photodynamic therapy in treatment of oral leukoplakia. *Photodiagnosis Photodyn Ther*. 2012 Jun;9(2):148–155. doi:10.1016/j.pdpdt.2011.12.007. PMID:22594985
11. Aggarwal N, Ahuja K, Pal N, Pannu R, Berwal V, Neeraj. Cryosurgery: a therapeutic modality for oro-facial lesions. *Int J Community Health Med Res*. 2017;3(3):66. Available at: <http://www.ijchmr.com/index.php/ijchmr/article/view/236>. Accessed June 23, 2024.
12. Chen Q, Dan H, Pan W, et al. Management of oral leukoplakia: a position paper of the Society of Oral Medicine, Chinese Stomatological Association. *Oral Surg Oral Med Oral Pathol Oral Radiol*. 2021 Jul;132(1):32–43. doi:10.1016/j.oooo.2021.03.009. PMID:34006487
13. Andabak-Rogulj A, Vindiš E, Aleksijević LH, Škrinjar I, Juras DV, Aščić A, Brzak BL. Different treatment modalities of oral lichen planus—a narrative review. *Dent J*. 2023;11:26. doi:10.3390/dj11010026