



Salmonella sepsis in a patient after infection of the aorto-biiliac stent graft implanted due to a ruptured aneurysm of the right common iliac artery – case report and literature review

Julia Siek^{1,A-D} , Justyna Sysiak-Sławecka^{2,E-F} 

¹ Student Research Group/Second Department of Anaesthesiology and Intensive Therapy, Medical University, Lublin, Poland

² Second Department of Anaesthesiology and Intensive Therapy, Medical University, Lublin, Poland

A – Research concept and design, B – Collection and/or assembly of data, C – Data analysis and interpretation, D – Writing the article, E – Critical revision of the article, F – Final approval of the article

Siek J, Sysiak-Sławecka J. Salmonella sepsis in a patient after infection of the aorto-biiliac stent graft implanted due to a ruptured aneurysm of the right common iliac artery – case report and literature review. J Pre-Clin Clin Res. 2024; 18(3): 190–194. doi: 10.26444/jpccr/190745

Abstract

Stent grafts are the most popular method of treating aneurysms. The incidence of vascular graft infection is 0.5% to 5%. In turn, the incidence of infection after percutaneous insertion of intravascular stent grafts is much lower and reaches approximately 1%, or less. The infection may be local, develop into acute sepsis, or develop into a chronic infection with septic flares. Stent graft infection in peripheral arteries is rare and dangerous. A foreign body, such as a stent graft, usually does not cause a reaction in body. However, cases of colonization with bacteria resulting in local or generalized infection have been described. Two types of body reactions to graft can be distinguished: an acute inflammatory response leading to the formation of an abscess, and a chronic inflammatory process with fibrosis. The case is presented of a patient with sepsis lasting several weeks, the result of infection of the aorto-biiliac stent graft. A review of the literature on the subject is also presented.

Key words

sepsis, aneurysm, stent graft, Salmonella

INTRODUCTION

According to the latest data, sepsis is a life-threatening organ dysfunction caused by impaired regulation of the body's response to infection [1]. According to 2017 data from the WHO, the annual number of cases worldwide is estimated at approximately 50 million, with death affecting approximately 11 million patients [1]. Depending on the country, the mortality rate ranges from 15% to over 50% [1]. In Poland, there are at least 50,000 cases of sepsis every year, and every second patient dies [2]. The death rate is estimated at 65 per 100,000 inhabitants [2].

Salmonella sepsis is very rare. In 2012–2013, approximately 80 cases of sepsis caused by Salmonella were reported annually in Poland [3]. Infection may occur intra-hospital. There is also a possibility that the patient may become a carrier of Salmonella bacilli in the gastrointestinal tract, which may then lead to blood infection. Diagnosing sepsis is difficult because it is accompanied by very non-specific symptoms [4]. Despite continuous progress in rapid diagnosis and resuscitation, sepsis remains an important cause of morbidity and mortality worldwide [4]. To improve the care of patients with sepsis and septic shock, the Surviving Sepsis Campaign (SSC) guidelines have been developed and are successively supplemented and updated [4].

✉ Address for correspondence: Julia Siek, Student Research Group of The Second Department of Anaesthesiology and Intensive Therapy, Medical University, Staszica 16, 20-081 Lublin, Poland
E-mail: siekjj@gmail.com

Received: 07.03.2024; accepted: 02.07.2024; first published: 05.08.2024

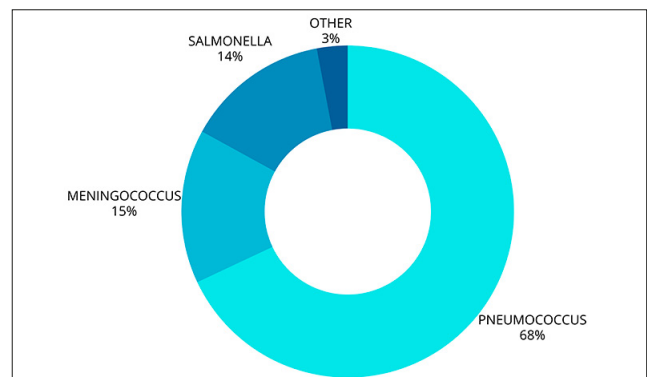


Figure 1. Etiology of sepsis in the out-of-hospital environment

CASE REPORT

A 56-year-old patient was admitted on 06.11.2023 to the ICU under general anaesthesia immediately after surgery due to retroperitoneal phlegmon and infection of the biiliac aorto-iliac stent graft. The stent graft was removed and a biological prosthesis implanted. The comorbidities included rheumatoid arthritis, previous meningitis, and the condition after embolization of an anterior communicating artery aneurysm.

The primary operation to implant a bi-iliac aortic stent graft due to a ruptured aneurysm of the common iliac artery, took place in January 2023. Three weeks after the initial surgery, the patient developed a fever and was admitted to the general surgery ward where he was treated with antibiotics. After the inflammation parameters decreased, he was discharged home.

He was subsequently hospitalized several more times due to signs of infection of the vascular bed, deterioration of his general condition, progressive weight loss, and severe abdominal pain.

At the time of admission, the patient was in a very serious condition, cachectic (BMI 18 kg/m²) with massive peripheral oedema. The patient was mechanically ventilated under analgo-sedation with propofol and fentanyl with RASS-3 (Richmond Sedated Agitated Scale). The circulatory system was ineffective and required large doses of norepinephrine. Haemodynamic monitoring using transpulmonary thermodilution was started, which showed the signs of hypovolaemia. On ultrasound examination, the diameter of the inferior vena cava was 0.8 cm, and respiratory variability – >60%. To stabilize the circulatory system, eight units of packed red blood cells, four units of plasma, and crystalloids were transfused. Active heating began due to the core temperature of 34.7°C. A blood culture was taken and piperacillin with tazobactam was administered as empirical antibiotic therapy.

In the following days, peripheral perfusion disturbances, marbled skin, and cyanosis of the feet and distal parts of the limbs were observed. Due to anuria and increasing acidosis-pH 7.06, continuous renal replacement therapy was started in the mode of haemodialysis with citrate anticoagulation. Nutrition intervention via the gastrointestinal tract and parenteral was also initiated. After receiving the blood culture, the result showing the growth of *Salmonella Enterica serovar Enteritidis*, antibiotic therapy was modified. Trimethoprim / sulfamethoxazole was included.

On the third day of hospital stay, after achieving logical contact, the patient was extubated, but on the next day he was reintubated due to tachypnea and abnormal breathing mechanics. On 12 November, another attempt was made to extubate the trachea. Unfortunately, due to increasing respiratory failure, the patient had to be intubated again. A percutaneous tracheostomy and bronchofiberscopy with toileting of the bronchial tree and collection of cultures were performed. The patient remained mechanically ventilated until the end of his stay. During this time, the patient required multiple transfusions of blood products and correction of electrolyte disorders. Due to the signs of post-operative wound infection, the patient was consulted many times by a vascular surgeon, and the wound treated with a vacuum dressing.

Despite intensive treatment, multi-organ failure increased. Ultimately, the patient died on the twenty-second day of hospitalization, i.e. 14 days after the diagnosis of infection of the implanted prosthesis with *Salmonella Enterica serovar Enteritidis* bacteria. The direct cause of the patient's death was sepsis caused by the previously mentioned pathogen.

Table 1. Acid-base balance results

	pO ₂ [mmHg]	pH	pCO ₂ [mmHg]	HCO ₃ ⁻ [mmol/l]	Current base deficit [mmol/l]	Lactate concentration [mmol/L]
06.11.2023	194	7.1	46.5	13.1	-14.6	7.5
08.11.2023	117	7.33	42.4	22.3	-3.6	2.3
09.11.2023	75.9	7.31	48.3	24.5	-1.7	2.1
10.11.2023	64.4	7.38	39.6	23.4	-1.7	1.6
12.11.2023	47.8	7.45	33.5	23.5	-0.4	2.1
13.11.2023	67	7.46	33.6	24	0.3	1.8
14.11.2023	85.5	7.49	31.3	23.8	0.4	1.1
22.11.2023	57.8	7.2	45.1	16.2	-10.2	5.9

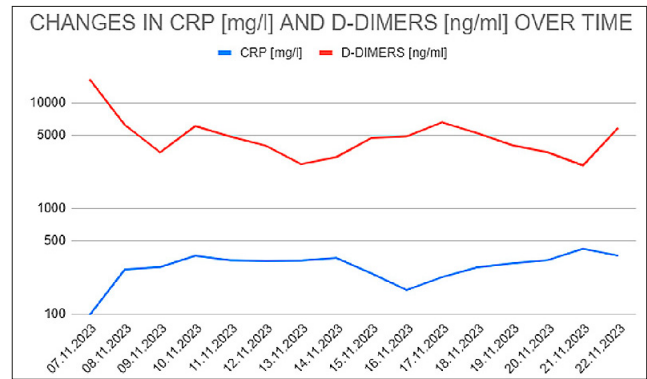


Figure 2. Changes in CRP and D-Dimers over time. CRP is expressed in mg/l. D-Dimers are expressed in ng/ml

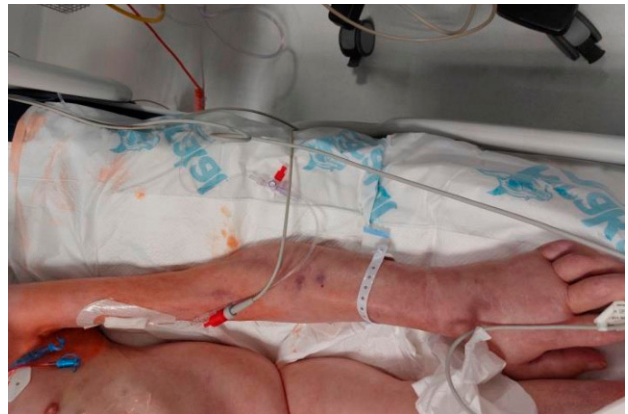

Figure 3. The arm is narrower than the shoulder

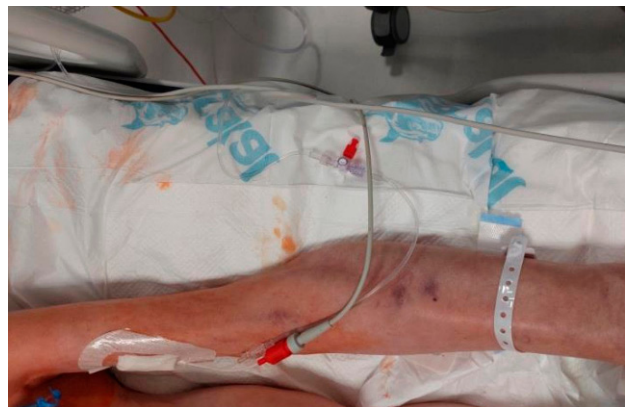

Figure 4. The arm is narrower than the shoulder

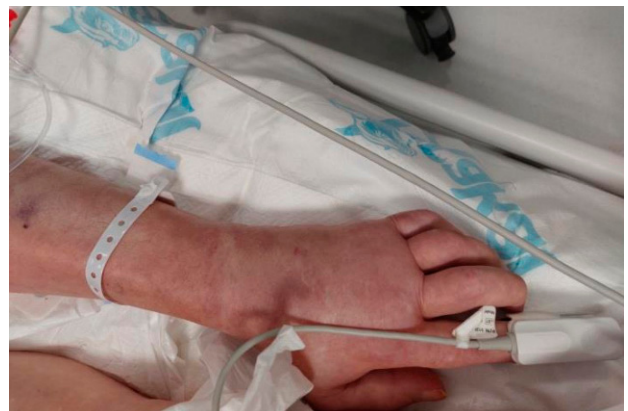

Figure 5. Pitting edema of the hand

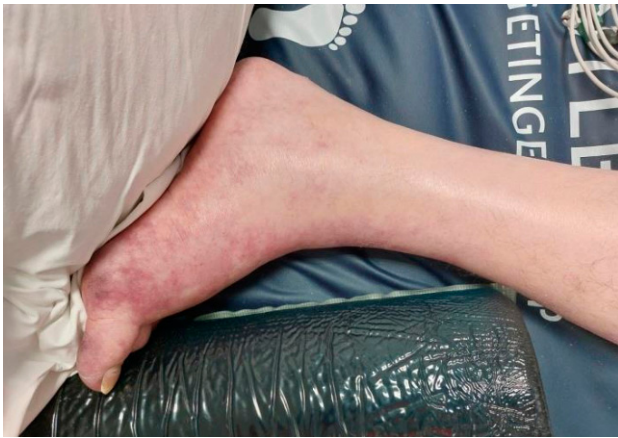

Figure 6. The photo shows pitting edema of the lower limb and slight cyanosis

DISCUSSION

Stent graft infection after endovascular surgery for aortic aneurysm is rare, with a frequency of only 0.4–1.0% [5]. However, infection of the aorto-iliac graft is more common and occurs in 2–6% of patients [5]. Mortality can reach up to 48% [5]. The high mortality rate may probably be related to late diagnosis of the infection due to non-specific initial symptoms of the infection. Infection of vascular stents is rare, but it is a very serious condition. The symptoms of the infection are non-specific and may resemble other diseases, such as flu. These include headache, weakness, fatigue, decreased well-being, joint and muscle pain, and fever. Sometimes septic shock may also occur. In most cases it is difficult to determine what caused the infection. However, it is assumed that issues related to violation of sterility during the procedure or repeated use of the same place for catheter insertion and repeated manipulation of the guidewire, may have a role [5,6]. In addition, the risk of stent graft infection is increased if the patient has diabetes or smokes. The most common bacterium, responsible for almost 77% of all stent infections, is *Staphylococcus aureus* [6] – an extremely virulent organism which is an opportunistic and versatile pathogen [7, 8]. It can cause many diseases, from acute and debilitating to chronic and difficult-to-treat infections [8].

However, it turns out that not only *Staphylococcus aureus* can lead to infection of the stent graft [8]. In the presented case, the infection was caused *Salmonella Enterica serovar Enteritidis*. In mid-January, the patient had a bifurcated stent graft implanted due to a ruptured right iliac artery aneurysm. Less than three weeks after the procedure, the patient was referred by a general practitioner (GP) due to abnormal laboratory test results: CRP 162 mg/l Hb 9.6. In the interview, the patient also reported a fever that appeared two weeks after the procedure. The infection could probably have already developed by then. The patient with an infected stent graft, for a long time sought specialist help in various centres. In November, the patient was admitted to the Vascular Surgery Department, where he was operated on due to retroperitoneal phlegmon and infection of the biiliac aorto-iliac stent graft. This was replaced with a biological prosthesis. The patient's condition probably would not have been so serious if appropriate actions had been taken earlier, but he had been walking around with an infected stent graft for several months, which significantly weakened his body. During that

time, bacteria – in this case *Salmonella Enterica serovar Enteritidis* – were able to multiply freely to huge amounts in the patient's body; and finally penetrated the blood and caused sepsis. The bacteria slowly destroyed subsequent organs and systems. The operation was performed to save the patient's life, but it was carried out too late. Three days after the procedure, culture from the biological prosthesis also showed the growth of *Salmonella Enterica serovar Enteritidis*. The patient's body was so devastated by prolonged infection that he died a month after surgery.

The authors report similar clinical cases in their research. Muhammad A. et al. report a series of clinical cases regarding the diagnosis and treatment of stent graft infection after endovascular repair of an aneurysm [9]. Two of five patients were given antibiotics and improved after a few months. In two other patients, the infected stent graft was removed and antibiotics administered, resulting in improvement. However, in one of the patients, no action could be taken because the patient's condition immediately deteriorated dramatically and he, too, died. Therefore, the patient in the presented case was not an isolated incident [9].

A group of researchers from the University of Münster in Germany researched the comparison between mortality and complications of endoprosthesis and abdominal aortic prostheses and an explanation for infection [10]. This study included 26 patients [10] and is the only published work to compare endovascular aneurysm repair (EVAR) with an explant of open aortic repair (OAR) in a consecutive series by the same surgical team [10]. All series depicted a long latency period between the first operation and infection – 60 months in the Münster series (OAR eight years vs. two years for EVAR) [10].

The pathogenesis of sepsis is very complex. It includes not only processes of systemic inflammatory response; and immunological disorders, but also changes in the functioning of many organs in the body [9, 11]. Infections of the respiratory system, gastrointestinal tract, urogenital tract, skin or soft tissue, are the most common sources of sepsis, and account for over 80% of all sepsis cases [11, 12]. Some sources state that gram-negative bacteria are responsible for most cases of sepsis, as much as 62% of all cases [13]. There are cases where patients are infected with multiple microorganisms. There are rare situations where the source of infection is fungal, viral or parasitic infections. In approximately 50% of patients treated for sepsis, known as culture-negative sepsis, the source cannot be determined [14]. A characteristic feature of sepsis is its variable course, depending on the source of infection, and it may not be visible until the late stage of the disease. The differential diagnosis of sepsis should include acute pulmonary embolism, acute myocardial infarction, acute pancreatitis, adrenal crisis and thyrotoxicosis [15]. The most common symptom of sepsis is fever. However, its absence does not exclude sepsis. Hypothermia caused by sepsis and lack of fever are more common in the elderly, in people who abuse alcohol, or in people with weakened immunity. Arterial hypertension occurs in approximately 40% of patients with sepsis [16]. In older people, sepsis may only be expressed by generalized weakness, agitation, irritability, or altered mental status [16, 17].

If sepsis is suspected, a complete blood count with a smear, a basic blood count panel, and measurement of lactates, procalcitonin, and liver enzymes should be performed, as well as coagulation tests and urine tests. Arterial or venous blood

results can help assess the degree of acid-base disturbances which are common in sepsis, and are likely a condition secondary to tissue hypoperfusion and renal dysfunction. Additionally, two blood cultures may be taken, including one from the central venous catheter if one is present. In addition to the previously mentioned symptoms, urine and stool cultures should also be collected in the case of diarrhoea or previous antibiotic therapy; sputum if the patient presents respiratory symptoms, as well as skin and soft tissue cultures in the presence of ulcers, abscess or skin drainage [17]. Others, such as cultures of cerebrospinal fluid, joint fluid, pleural fluid, and peritoneal fluid, are collected according to clinical indications [17].

Due to the non-specificity of the accompanying symptoms, it is difficult to diagnose sepsis, therefore the initiation of treatment is delayed accordingly [17]. The SSC guidelines for the management of adults with sepsis and septic shock are helpful [17]. The 2021 editions are the latest update and place greater emphasis on a diverse global perspective and the long-term effects of sepsis on patients and their families [17]. The guidelines are divided into six sections [17] which include screening and early treatment, infections, haemodynamic management, respiratory support, adjuvant therapies, goals of care, and long-term outcomes [17]. The screening guidelines include a recommendation to use the qSOFA (quick Sequential Organ Failure Assessment score) scale and the measurement of serum lactate concentration [17]. The qSOFA score should not be used as the sole screening tool [17]. Also, the measurement of lactate concentration has a low predictive value [17]; however, its increased concentration should prompt further diagnostics [17]. SSC data recommends debridement of the site of infection, and in the presented case the patient had been wearing an infected stent graft for about 10 months and receiving antibiotics, which led to its destruction.

An aneurysm occurs due to the thinning and stretching of the aorta walls. When the aneurysm wall is too thin and cannot stretch any further, it may rupture and haemorrhage. The rupture of an aneurysm is its greatest threat [18]. Most often, an aneurysm is asymptomatic and is detected during ultrasound examinations performed for other reasons [18]. An aneurysm cannot be fully cured and its growth cannot be blocked [18]. It is only possible to slow down its development. Treatment of an aneurysm depends on its size and rate of growth. In the case of aneurysms with a diameter over 5 cm and rapidly growing, which are at risk of rupture, surgical treatment is recommended [18]. In other cases, such as minimal growth of the aneurysm, it is important to change lifestyle, such as normalizing blood pressure, quitting smoking, limiting salt intake, avoiding excessive exercise and regularly monitoring the size of the aneurysm [19]. This increases the chance of survival and postpones surgery even for many years. Currently, there are two main types of aneurysm treatment: classic surgery and endovascular method [19]. The first involves cutting out the aneurysm sac and implanting a vascular prosthesis in its place. This is the recommended method when operating on an infected aneurysm [19]. The second option is the endovascular method which, due to its high safety, is most often used in older people or people with other diseases [19]. This treatment causes less discomfort, shortens hospitalization time, and guarantees faster recovery. The endovascular procedure is performed through a small incision in the groin area, without the need

to open the abdominal cavity. In vascular surgery, stent graft infection is one of the most serious complications with a very uncertain prognosis. This is a very rare complication.

The incidence of aortic endograft infection is low – 0.2–0.7% [20]. Ducasse et al. in their meta-analysis, included data from 65 clinical cases of stent graft infection [21]. The infection rate in the study was approximately 0.43% [21]. Although most authors recommend the removal of the implant and various methods of aortic reconstruction, the surgery carries high risks; therefore, antibiotic therapy is sometimes attempted. So far, antibiotics from the glycopeptide group – vancomycin and teicoplanin – have been used, but they have often shown low effectiveness in the treatment of infected dentures. In a clinical case report of a patient with an infected stent graft, Miszczuk et al. used dalbavancin, which in their case turned out to be effective [19]. The patient was disqualified from graft explantation due to the extensive scope of the potential procedure, because the stent graft covered the area from the left subclavian artery to the division of the common iliac arteries [19]. An unfavourable factor is the high price of dalbavancin [19] and its use has not yet been supported in subsequent cases, and is not a valuable alternative to surgical treatment [19, 20]. Hai Lei Li et al. in a meta-analysis showed that current evidence indicates that surgical treatment is a better option than conservative management in selected patients with aortic endograft infection [21].

SUMMARY

Aortic stent graft infection is rare. At the same time, it is one of the most difficult and life-threatening complications for the patient. Surgical treatment is a better option compared to conservative treatment in selected patients with aortic endograft infection. However, supportive care without surgical intervention is associated with significant mortality.

REFERENCES

1. Bauer M, Gerlach H, Vogelmann T, Preissing F, Stiefel J, Adam D. Mortality in sepsis and septic shock in Europe, North America and Australia between 2009 and 2019 – results from a systematic review and meta-analysis. *CritCare*. 2020;19;24(1):239. doi:10.1186/s13054-020-02950-2
2. Global report on the epidemiology and burden of sepsis: current evidence, identifying gaps and future directions. Geneva: World Health Organization; 2020. Licence: CC BY-NC-SA 3.0 IGO.
3. Kuchar E. Sepsa i wstrząs septyczny. <https://www.mp.pl/pacjent/choroby-zakazne/choroby/zakazenia-bakteryjne/160129,sepsa-i-wstrzas-septyczny> (access: 05.06.2017).
4. Rhee C, Dantes R, Epstein L, Murphy DJ, Seymour CW, Iwashyna TJ, et al. Incidence and trends of sepsis in US hospitals using clinical vs claims data, 2009–2014. *JAMA*. 2017;318:1241. doi:10.1001/jama.2017.13836
5. Löffler B, Tuchscher L. Staphylococcus aureus Toxins: Promoter or Handicap during Infection? *Toxins (Basel)*. 2021 Apr 19;13(4):287. doi:10.3390/toxins13040287
6. Linares-Palomino JP, Lopez-Espada C. Infectious Complications of EVAR are Deadlier than Those of Conventional Surgery. *Eur J VascEndovascSurg*. 2019 Jan;57(1):137. doi:10.1016/j.ejvs.2018.08.036.
7. Salomão R, Ferreira BL, Salomão MC, Santos SS, Azevedo LCP, Brunialti MKC. Sepsis: evolving concepts and challenges. *Braz J Med Biol Res*. 2019;52(4):e8595. doi:10.1590/1414-431X20198595
8. Lühr R, Cao Y, Söderquist B, Cajander S. Trends in sepsis mortality over time in randomized sepsis trials: a systematic literature review and meta-analysis of mortality in the control arm, 2002–2016. *CritCare*. 2019;23:1.

9. Huang M, Cai S, Su J. The Pathogenesis of Sepsis and Potential Therapeutic Targets. *Int J Mol Sci.* 2019 Oct 29;20(21):5376. doi:10.3390/ijms20215376
10. Gauer R, Forbes D, Boyer N. Sepsis: Diagnosis and Management. *Am Fam Physician.* 2020 Apr 1;101(7):409–418.
11. Gupta S, Sakhuja A, Kumar G, et al. Culture-negative severe sepsis: nationwide trends and outcomes. *Chest.* 2016;150(6):1251–1259.
12. Nannan Panday RS, Lammers EMJ, Alam N, et al. An overview of positive cultures and clinical outcomes in septic patients. *CritCare.* 2019;23(1):182.
13. White HD, Vazquez-Sandoval A, Quiroga PF, et al. Utility of venous blood gases in severe sepsis and septic shock. *Proc (BaylUnivMed Cent).* 2018;31(3):269–275.
14. Rhodes A, Evans LE, Alhazzani W, et al. Surviving Sepsis Campaign: international guidelines for management of sepsis and septic shock: 2016. *CritCare Med.* 2017;45(3):486–552.
15. McIntyre L, Rowe BH, Walsh TS, et al.; Canadian Critical Care Trials Group. Multicountry survey of emergency and critical care medicine physicians' fluid resuscitation practices for adult patients with early septic shock. *BMJ Open.* 2016;6(7):e010041.
16. Sakr Y, Rubatto Birri PN, Kotfis K, et al.; Intensive Care Over Nations Investigators. Higher fluid balance increases the risk of death from sepsis: results from a large international audit. *CritCare Med.* 2017;45(3):386–394.
17. Oczkowski S, Alshamsi F, Belley-Cote E, Centofanti JE, Moller MH, Nunnally ME, Alhazzani W. Postępowanie w sepsie i wstrząsie septycznym. Praktyczne wskazówki z wytycznych Surviving Sepsis Campaign 2021. *Med Prakt.* 2022;10:31–42.
18. Seymour CW, Kennedy JN, Wang S, et al. Derivation, validation, and potential treatment implications of novel clinical phenotypes for sepsis. *JAMA.* 2019;321(20):2003–2017.
19. Miszczuk M, Rylski R, Hołody Ł, Tarnawska-Pierścińska M. Stent graft infection treated with dalbavancin in patient after endovascular repair of thoracic and abdominal aortic dissection—case report. *Forum zakażeń.* 2018;9(1):45–48. doi:dx.doi.org/10.15374/FZ2018013
20. Carrel T, Englberger L, Schmidli J. How to treat aortic graft infection? With a special emphasis on xeno-pericardial aortic tube grafts. *Gen Thorac Cardiovasc Surg.* 2019 Jan;67(1):44–52. doi:10.1007/s11748-017-0839-0
21. Li HL, Chan YC, Cheng SW. Current Evidence on Management of Aortic Stent-graft Infection: A Systematic Review and Meta-Analysis. *Ann VascSurg.* 2018 Aug;51:306–313. doi:10.1016/j.avsg.2018.02.038