



Superior thyroid artery – variations of origin and clinical significance

Michał Bednarz^{1,B-D}, Miłosz Gromaszek^{1,B-D}, Aleksander Daniluk^{1,A-B,D}, Kaja Iwaniuk^{1,A,E-F}, Maciej Samczuk^{2,1,E-F}, Zuzanna Białkowska^{1,3,B,E}, Jakub Buczek^{1,C,E}, Hubert Stachowicz^{1,B,D}, Łukasz Gawłowicz^{4,C,E}, Jan Ostański^{1,3,B-C}

¹ Human Anatomy Research Group, Medical University, Lublin, Poland

² Department of Correct, Clinical and Imaging Anatomy, Medical University, Lublin, Poland

³ 1st Military Clinical Hospital with the Outpatient Clinic, Lublin, Poland

⁴ 'MEDYK' Family Medicine Clinic – Non-public Healthcare Facility, Biata Podlaska, Poland

A – Research concept and design, B – Collection and/or assembly of data, C – Data analysis and interpretation, D – Writing the article, E – Critical revision of the article, F – Final approval of the article

Bednarz M, Gromaszek M, Daniluk A, Iwaniuk K, Samczuk M, Białkowska Z, Buczek J, Stachowicz H, Gawłowicz Ł, Ostański J. Superior thyroid artery – variations of origin and clinical significance. J Pre Clin-Clin Res. doi: 10.26444/jpccr/188620

Abstract

Introduction and Objective. The superior thyroid artery (STA) is one of the two paired arteries that constitute the arterial supply to the thyroid. In the traditional approach, it is described as a branch of the external carotid artery, originating directly above the bifurcation of the common carotid artery. Knowledge of its point of origin, course, and anatomical variations is essential for surgeons performing neck operations. The aim of this review is to provide information on anatomical differences in the origin and course of the superior thyroid artery, based on a review of current literature.

Review Methods. The review is based on 28 articles obtained from PubMed and ResearchGate databases using the key words 'superior thyroid artery', 'superior thyroid artery anatomical variations', 'superior thyroid artery anatomy', 'superior thyroid artery variations', 'superior thyroid artery haemorrhage, published between 1928–2023.

Brief description of the state of knowledge. The analysis of current literature revealed significant discrepancies in the points of origin of the STA. Depending on the studied population, the most common point of STA origin varied, and could be the branch from the external carotid artery (ECA), common carotid artery (CCA), or the bifurcation of the common carotid artery (CCB).

Conclusions. The varying proportions of the STA origins highlight the particular importance of understanding anatomical variations in its origin, especially for surgeons involved in neck surgery to minimize complications after operations in this region. Differences in the proportions of specific origins among the described papers indicate the need for conducting more extensive studies on larger groups to better understand the variability of STA origins in a specific population.

Key words

thyroid, anatomic variations, thyroidectomy, arteries, hemorrhage

INTRODUCTION

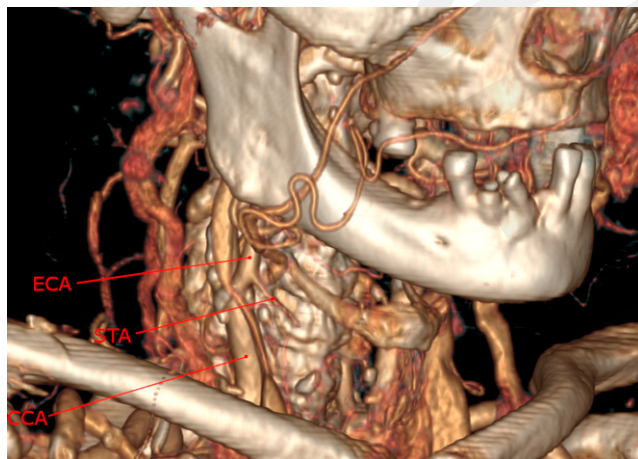

Figure 1. Superior thyroid artery (STA) arising from external carotid artery (ECA), just above bifurcation of common carotid artery (CCA) on the CT-angiography. From the collection of the Department of Medical Radiology I, Medical University of Lublin

✉ Address for correspondence: Aleksander Daniluk, Human Anatomy Research Group, Medical University, Lublin, Poland
E-mail: aleksanderdaniluk5@wp.pl

Received: 18.04.2024; accepted: 13.05.2024; first published: 04.06.2024

The origin and course of the superior thyroid artery (STA) are typically presented in anatomy textbooks as relatively constant. The most common anatomical variation of STA is described as a direct branch of the external carotid artery just above the bifurcation of the common carotid artery [1,2] (Fig. 1). The superior thyroid artery, at its origin, is covered by the sternocleidomastoid muscle, then ascends anteriorly within the carotid triangle, covered by skin, the platysma, and the superficial layer of the cervical fascia[3]. Further along its course, it descends laterally to the external branch of superior laryngeal nerve (eSLN) and the inferior pharyngeal constrictor muscle, passing beneath the omohyoid, sternohyoid and sternothyroid muscles, where its terminal branches immerse into the thyroid parenchyma [3]. Along its length, the superior thyroid artery gives off four branches: the infrahyoid branch (also known as the hyoid artery), which runs along the lower border of the hyoid bone beneath the thyrohyoid muscle; the sternocleidomastoid branch, which descends laterally along the common carotid artery, supplying the sternocleidomastoid muscle; the superior laryngeal artery, which arises from the STA near its origin or shares a common trunk with it, then travels with the internal branch of the superior laryngeal nerve, piercing the lateral thyroid membrane and supplying the mucosa and muscles

of the pharynx; and the cricothyroid branch – courses either above or below the thyrohyoid muscle (with a highly variable course) [4,5]. STA gives off glandular branches to the thyroid gland, usually including the anterior, lateral, and posterior glandular branches (Fig. 2).

In reality, the origin of the STA is characterized by significant variability, as evidenced by various classifications of anatomical variants, such as those proposed by Vazquez [6] or Natsis [7]. Vazquez's classification divides the origin of the STA into four types: type I – origin at the bifurcation of the common carotid artery (CCB); type II – origin from the common carotid artery (CCA); type III – origin from the external carotid artery (ECA); type IV – origin as a common trunk with the lingual artery (type IVa) or with the lingual and facial arteries (type IVb) (Fig. 3) [6]. This classification used in this review.

MATERIALS AND METHOD

Information from 28 scientific papers (summarizing articles on anatomical variations and those with clinical aspects, from PubMed and ResearchGate databases) was used to collect the data for this review. At the beginning of the literature review, using key words 'superior thyroid artery anatomical variations', 'superior thyroid artery anatomy', 'superior thyroid artery' and 'superior thyroid artery haemorrhage', approximately 80 studies were considered. Ultimately, 12 studies were selected which illustrated the cross-section of anatomical variations of described artery in different populations, with a particular focus on articles from the last 15 years. Selected papers range from 1928 – 2023 and contained cadaveric studies, CT-angiography studies, available literature reviews, and one digital subtraction angiography (DSA) study. Some studies combined several of the methods mentioned.

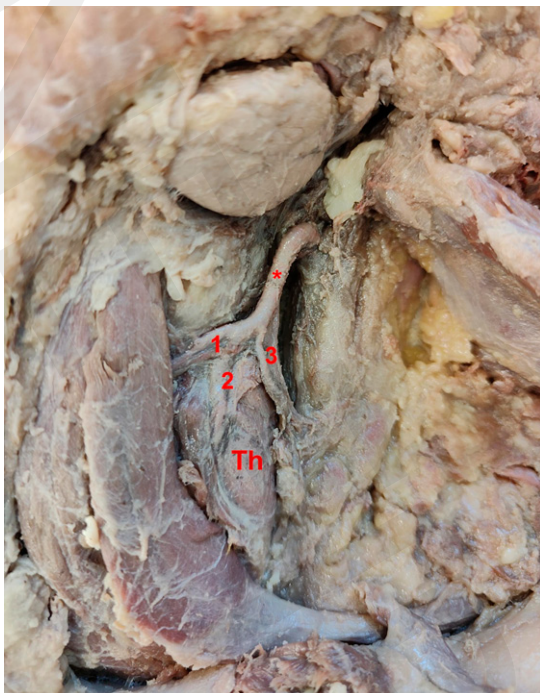


Figure 2. Superior thyroid artery (*) and its branches: anterior (1), lateral (2) and posterior (3), thyroid gland marked as Th. From the collection of the Department of Correct, Clinical, and Imaging Anatomy at the Medical University of Lublin

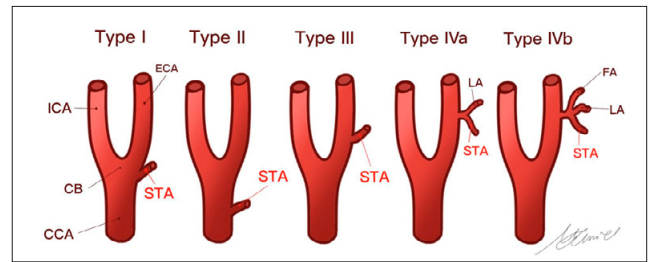


Figure 3. Classification of the origins of the superior thyroid artery according to Vazquez. The illustration was created by lek. Magdalena Chmiel

Origin from the external carotid artery. Natsis, studying the cadavers of Caucasian Greeks, demonstrated the origin of STA from ECA in 39 out of 100 specimens (right side 22, left side 17) [7]. Shivealeela performed dissections on 84 heminecks, demonstrating the origin of the superior thyroid artery from the external carotid artery in 64 cases (right side 33, left side 31), constituting 76.19% of all examined samples [8]. Sreedharan examined 60 heminecks, illustrating the origin of STA from ECA in 53 specimens (88.33%) (right side 27, left side 26) [9]. Munjakmar examined 100 cases, with 71 featuring the observed origin of STA (right side 31, left side 40) [10]. Manjappa, studying 40 anterior neck triangles, revealed 11 discussed origins (27.5%) (right side 6, left side 5) [11]. A similar trend was observed by Vazquez, where among 207 examined specimens, 48 indicated the origin of STA from ECA (23.2%); the study did not provide the frequency of occurrences on each side) [6]. Adachi,* studying the cadavers of the Japanese population, showed 177 origins of STA at this level in a study of 300 body sides, accounting for 59 percent of all cases [12].

* The Adachi study was carried out in 1928, whereas the remaining studies were conducted between 2009 – 2023. Surely Adachi should be first and the rest in chronological order.

Gupta's angiographic study examined 25 cases (right side 14, left side 11), revealing 18 origins of STA from ECA (72%; right side 10, left side 8) [13]. Herrera-Núñez, in a study of 152 subjects using CT angiography, illustrated 77 origins of STA from ECA (50.7%; right side 43, left side 34) [14]. The study with the largest number of samples was Esen's study based on CT-angiography, involving 1,280 carotid arteries, where the described origin occurred in 667 cases (52.1%; right side 431, left side 256) [15]. In the study of 40 cadavers (80 heminecks), which were of Indian origin, Anand observed the origin of STA from ECA in 40% cases (right side 15, left side 17) [16]. CT-angiographic studies conducted by Bhardwaj on 210 samples showed the origin of STA from ECA in 162 cases (77.1%): right side 90; left side 70 [17].

Origin from common carotid artery. Munjamkar, in a sample of 100 carotid arteries, found 24 cases of origin from the CCA (right side 14, left side 10) [10], while Natsis, in a similarly sized sample, demonstrated this variation in only 12 cases (right side 5, left side 7) [7]. In a study of 84 samples, Shivaleela demonstrated the occurrence of the superior thyroid artery originating from the common carotid artery in 2 cases (2.38%) (one on each side) [8]. Sreedharan, in sections of 60 cases, showed the described origin only twice (3.33%) (left side only) [9]. Manjappa observed this variation in 25 out of 40 examined carotid arteries (62.5%; right side 11; left side 14) [11]. Vazquez, in a study of 207 carotid arteries, identified

Table 1. Origin of superior thyroid artery from external carotid artery

Study (year)	Study type (diagnostic tool)	No. of subjects	Origin STA from ECA (%)	Right side	Left side
Adachi (1928)	Cadaveric	300	177 (59.0%)	-	-
Vazquez (2009)	Cadaveric	207	48 (23.2%)	-	-
Natsis (2011)	Cadaveric	100	39 (39.0%)*	22/39*	17/39
Gupta (2014)	DSA	25	18 (71.5%)	10/18	8/18
Shivaleela (2016)	Cadaveric	84	64 (76.2%)	33/64	31/64
Esen (2018)	CT-angiography	1280	667 (52.1%)	413/667	254/667
Sreedharan (2018)	Cadaveric	60	53 (88.3%)	27/53	26/53
Herrera-Núñez (2020)	CT-angiography	152	77 (50.7%)	43/77	34/77
Munjamkar (2020)	Cadaveric	100	71 (71.0%)	31/71	40/71
Anand (2021)	Cadaveric	80	32 (40.0%)	15/32	17/32
Manjappa (2021)	Cadaveric	40	11 (27.5%)	6/11	5/11
Bhardwaj (2023)	CT-angiography	210	162 (77.1%)	90/162	72/162

*Includes one origin of the thyrolingual trunk at a given level.

55 described variations, accounting for 26.57% of all cases [6]. In 2021 study by Anand of 40 cadavers, STA originated from the CCA in 20% of cases (right side 9, left side 7) [16]. Adachi, in a study of 300 body sides? showed 39 cases of the described origin, constituting 13% of all cases [12]. Gupta, examining angiographically 25 carotid arteries (right side 14; left side 11), showed the origin of STA from CCA in one case (4%) (right side) [13]. Herrera-Núñez, analyzing CT-angiography results for 152 carotid arteries, found 26 cases of the described origin (17.1%; right side 7; left side 19) [14], while Esen, in a study of 1,280 carotid arteries, demonstrated this anatomical variant in 316 cases (24.6%; right side 90; left side 226) [15]. A CT-angiographic study by Bhardwaj in 2023 showed the origin of STA from CCA in 18/210 cases (8.6%; right side 8; left side 10) [17].

Origin from common carotid artery bifurcation. In a 1928 study, Adachi performed a detailed study of the arterial system in 150 Japanese cadavers. As a result of the performed dissections, it was determined that the superior thyroid artery originated from the common carotid artery bifurcation in 27% of cases (81 arteries out of 300 samples) [12].

In a 2009 study by Vazquez on 207 heminecks, the origins and courses of the superior thyroid artery were determined. In 102 cases (49.3%), the STA was found to originate from the bifurcation of the common carotid artery (CCB), classified as type I [6]. In a 2011 study by Natsis, 50 human cadavers (44 males and 6 females) were examined, with the STA observed to originate from the CCB in 49 cases out of 100 (right side 23; left side 26) [7].

In 2014, a study with a similar focus was conducted by Gupta. The course of the superior thyroid artery was determined

Table 2. The origin of superior thyroid artery from common carotid artery

Study (year)	Study type (diagnostic tool)	No. of subjects	Origin STA from CCA (%)	Right side	Left side
Adachi (1928)	Cadaveric	300	39 (13.0%)	-	-
Vazquez (2009)	Cadaveric	207	55 (26.6%)	-	-
Natsis (2011)	Cadaveric	100	12 (12.0%)*	5/12*	7/12
Gupta (2014)	DSA	25	1 (4.0%)	1/1	0/1
Shivaleela (2016)	Cadaveric	84	2 (2.4%)	1/2	1/2
Esen (2018)	CT-angiography	1280	316 (24.7%)	90/316	226/316
Sreedharan (2018)	Cadaveric	60	2 (3.3%)	0/2	2/2
Herrera-Núñez (2020)	CT-angiography	152	26 (17.1%)	7/26	19/26
Munjamkar (2020)	Cadaveric	100	24 (24.0%)	14/24	10/24
Anand (2021)	Cadaveric	80	16 (20.0%)	9/16	7/16
Manjappa (2021)	Cadaveric	40	25 (62.5%)	11/25	14/25
Bhardwaj (2023)	CT-angiography	210	18 (8.6%)	8/18	10/18

*Includes one origin of thyrolingual trunk at the given level

based on 25 angiograms, with 14 angiograms for the right side and 11 for the left side. On the right side, the superior thyroid artery originated from the CCB in 3 cases, and on the left side in 2 cases. The results of this study were in line with previous findings, indicating that the origin and course of the superior thyroid artery could be somewhat predicted [13].

A study in 2016 by Shivaleela, involving 42 cadavers (84 heminecks) of various genders and ages, found that the superior thyroid artery originated from the CCB in 18 cases (21.43%). The study concluded that determining the origin and course of the superior thyroid artery is essential for planning surgical procedures in the neck region [8].

In 2018, Sreedharan and Esen conducted studies on the superior thyroid artery. In Sreedharan's study, 60 heminecks were examined over a 5-year period, revealing the origin of the superior thyroid artery from the CCB in 5 cases (8.33%). Three cases (60%) were on the right side, and 2 cases (40%) were on the left side. The study emphasized the importance of determining the position of the superior thyroid artery, especially if it is not in its customary location. In such cases, it is necessary to assess the relationship of the artery to the external branch of superior laryngeal nerve (ebSLN) or the thyroid cartilage [9]. In the Esen study involving 640 patients (1,280 cases of superior thyroid artery origins), 2 experienced radiologists conducted the examination using frontal and sagittal CT-angiography. The researchers identified 279 cases where the STA originated from the bifurcation of the common carotid artery, with 131 cases on the right side and 148 cases on the left side. The study highlighted the significant utility of CT angiography in determining the origin and course of the superior thyroid artery in a non-invasive manner, reducing incidents and complications in head and neck surgical procedures [15].

In 2020, Herrera-Nunez conducted a study to determine the origin and course of the superior thyroid artery using CT-angiography. Among 152 cases, 31 showed the STA originating from the CCB (similar occurrences on both sides; 15 on the right side and 16 on the left side)[14]. In the same year, Munjamkar selected cadavers without damage to the superior thyroid artery for a study, regardless of age and gender. The study involved a midline incision from the chin to the sternum, with a second incision from the chin through the base of the mandible to the mastoid process. The course of the superior thyroid artery was examined, and it was demonstrated that the artery originated from the common carotid artery bifurcation in only 5 cases out of 100. The researchers also noted that in each of the 5 cases, the right STA began from the bifurcation, while it was not proven that the left STA started in the same way[10].

In 2021, Manjappa conducted a study on the origin of the superior thyroid artery, selecting 20 human cadavers, for a total of 40 superior thyroid arteries. The anterior neck triangle was visualized bilaterally, observing the relationship between STA and the external laryngeal nerve. The study revealed that superior thyroid artery arose from the bifurcation of the common carotid artery in 2 out of 40 cases (5%). The most common site of origin was the common carotid artery (62.5%). The results indicated that variability in the pattern of origin of the superior thyroid artery and its relationship with the external laryngeal nerve is a relatively common phenomenon. Surgeons performing procedures in the head and neck area must consider all possibilities regarding the origin of the STA to avoid later complications [11].

In 2021, Anand observed the origin of STA on 40 cadavers. The cadavers had no prior history of trauma or surgical interventions involving the cervical region. A midline incision was made from the mentum to the manubrium to access the subplatysmal plane for further dissection of anatomical structures around the STA. Once the CCA was identified, the origin of the STA in relation to it and the thyroid lamina was determined. Through meticulous dissection, the STA's relationship to surrounding anatomical landmarks and their respective distances were measured using a digital caliper sensitive to 0.01 mm. The study showed the origin STA from CCB in 40% of samples (right side 16; left side 16). In this study, no uncommon origins of STA were discovered, such as origin from the thyrolingual trunk[16].

In 2023, Bhardwaj et. al. conducted a CT-angiographic study on 210 samples aimed at assessing the extent of variability in the origin of thyroid arteries on an Indian population. Patients aged 18 and above who underwent CT angiography were enrolled in the study. Those with prior common carotid occlusions or known vascular abnormalities, such as carotid hypoplasia, plaque in the carotid bifurcation, or aneurysms, were excluded. The study demonstrated that STA originates from CCB in 14.3%: 7 arteries on the right side and 23 arteries on the left side [17].

Origin from common trunk with another artery and other uncommon origins. In a 2009 study by Vazquez, the origin of superior thyroid artery as a common trunk with another artery was identified in one or more instances. This is a type IV origin, further divided into type IVa and type IVb. In type IVa, the STA forms a common trunk with the lingual artery, creating the thyrolingual trunk. This was observed

Table 3. Origin of superior thyroid artery from common carotid artery bifurcation

Study (year)	Study type (diagnostic tool)	No. of subjects	Origin STA from CCB (%)	Right side	Left side
Adachi (1928)	Cadaveric	300	81 (27.0%)	-	-
Vazquez (2009)	Cadaveric	207	102 (49.3%)	-	-
Natsis (2011)	Cadaveric	100	49* (49.0%)	23/49	26/49*
Gupta (2014)	DSA	25	5 (20.0%)	3/5	2/5
Shivaleela (2016)	Cadaveric	84	18/84 (21.4%)	8/18	10/18
Esen (2018)	CT-angiography	1280	279 (21.8%)	131/1280	148/1280
Sreedharan (2018)	Cadaveric	60	5 (8.3%)	3/5	2/5
Herrera-Núñez (2020)	CT-angiography	152	31 (20.4%)	15/31	16/31
Munjamkar (2020)	Cadaveric	100	5 (5.0%)	5/5	0/5
Anand (2021)	Cadaveric	80	32 (40.0%)	16/32	16/32
Manjappa (2021)	Cadaveric	40	2 (5%)	1/2	1/2
Bhardwaj (2023)	CT-angiography	210	30 (14.3%)	7/30	23/30

*Includes one origin of thyrolingual trunk at the given level

as a very rare phenomenon, occurring in only 2 out of 330 cases (prevalence 0.6%). In one of these cases, the trunk originated from the external carotid artery, on the left side, while on the right side it originated from the common carotid artery. In type IVb, a common origin was noted with the facial artery and the lingual artery, resulting in a common thyrolinguofacial trunk in one out of 330 cases (prevalence 0.3%) [6].

In a similar study by Natsis in 2011, 44 male and 6 female cadavers were selected, with an age range of 10–90 years. The neck area was exposed to assess neck vessels, and the cadavers were categorized by 2 independent physicians, an anatomist and a pathologist. The study revealed that the STA does not always begin as a separate branch, but may start as a common trunk with the lingual artery. Three thyrolingual trunks were found, one branching from the ECA, another from the common carotid artery bifurcation, and the third from the CCA. Furthermore, it was noted that trunks branching from the CCA and ECA started on the right side, while the trunk branching from the CCB started on the left side. In some cases, the facial and lingual arteries began together, forming a linguofacial trunk, each time originating from the ECA. No thyrolinguofacial trunks were found in the examined cadavers [7].

The precise examination of the arterial system conducted in by Adachi in 1928 on 300 heminecks revealed type IVa origin in 6 cases (2%). No IVb origin was observed [12]. Type IVa was also demonstrated in a study by Manjappa. In 5% of the samples (2/80), both cases on the right side, thyrolingual trunk occurred [11].

A study conducted by Gupta in 2014 (only DSA study involved in this review) reported one origin of STA from

internal carotid artery (ICA) on the left side [13]. This is a very untypical origin of the superior thyroid artery, and not included in both Vazquez and Natsis classifications.

Esen's study demonstrated that in rare cases, the superior thyroid artery may be absent altogether. The absence of this artery was shown in 6 specimens on the right side and in 12 on the left side, amounting to a total of 18 cases out of 1,280 examined specimens (1.4%). STA was bilaterally absent in 2 patients [15].

The study conducted by Herrera-Nunez in 2020 stood out among the other studies included in this review due to the relatively common origin of STA in the common trunk with the lingual artery (type IVa according to Vazquez), which occurred in 16 out of 152 cases (10.5%). In 8 cases, the thyrolingual originated from the ECA (right side 5; left side 3), 6 times from the CCB (3 times each on the right and left), and twice from the CCA (once on the right and once on the left). Additionally, in 2 cases, the STA was absent from the right side on both occasions (1.3%) [14].

The origins of STA presented above are uncommon, but practicing head and neck surgeons must be aware of such anatomical variations to avoid bleeding during procedures and post-operative complications.

DISCUSSION

The superior thyroid artery is generally characterized by a variable, individual course. Numerous studies conducted over the past years have confirmed this. These studies were primarily based on cadaver dissections, where the neck area was exposed to visualize the origin and course of the discussed artery. Angiographic and CT-angiographic methods were also used in these studies. The authors of the current review aimed to include a large number of cadavers or images in their cataloged studies, as such studies provide robust statistical data for drawing accurate conclusions. In the majority of selected studies, the most common site of STA origin was the external carotid artery (ECA). In a 2014 study by Gupta, the frequency of this origin site was 71.5% [13], in a study by Shivaleela in 2016 – 76.19% [8], in a study by Sreedharan – 88.33% [9], in a study by Munjamkar in 2020 – 71% [10], in a study by Herrera-Nunez in 2020 – 50.7% [14], in a study by Esen in 2018 – 52.1% [15], in a study by Bhardwaj in 2023 – 77.1% [17], and in a study by Adachi in 1928, the frequency was 59% [12].

Only a few studies have indicated a different site of origin as the most common. In a 2011 study by Natsis, the most common site of origin was the common carotid artery bifurcation, at a rate of 49% [7], and in a 2009 study by Vazquez, the frequency was also 49% [6]. On the other hand, Manjappa observed in his study that the most common site of origin of STA was the common carotid artery in 62.5% of cases [11]. In addition, rare cases involved the origin of STA from the CCA, and even rarer cases involved a common trunk with at least one other artery. A study by Anand in 2021 showed the origin of the STA from ECA and CCB with equal frequency (40%) [16].

Considering the above data, the most common site of origin of STA is the ECA. However, it is essential to remember that the site of origin may vary, affecting approximately one-fourth of the population. Surgeons performing neck surgeries must be aware of this. The largely overlapping results of

these studies allow for predicting the origin and course of STA. Recently, the CT-angiographic method has also proven useful, allowing for precise identification of the variables mentioned above. This method is particularly valuable as it is non-invasive and helps avoid bleeding during thyroidectomy due to STA transection. Cases have been reported of severe haemorrhage or haematoma occurring after thyroidectomy [18–20], as well as after blunt neck trauma [21], which may be linked to variations of the STA. Haematomas and bleeding from this vessel could also be associated with procedures such as fine-needle aspiration of thyroid nodules [22, 23], carotid artery stenting [24], and internal jugular vein catheterization [25]. Physicians performing these procedures should therefore be very familiar with the course of the STA, and possible variations in its origin.

The accurate identification of the STA is also very important during the assessment of peak systolic velocity using Doppler ultrasound (STA-PSV). Elevated STA-PSV values are characteristic of Graves' disease, and this examination is one of the components in differentiating this disease from destructive thyroiditis (including amiodarone-induced thyrotoxicosis, painless thyroiditis, subacute thyroiditis and postpartum thyroiditis), where STA-PSV values are significantly lower. Knowledge of variations in the origin of STA is crucial for the accurate identification of this vessel during Doppler ultrasound and obtaining reliable examination results [26, 27].

Additionally, the external branch of superior laryngeal nerve (ebSLN) runs in the vicinity of this artery. Literature states that damage to the ebSLN affects up to 58% of patients undergoing thyroid surgery, which is why the course of this nerve should be routinely identified before thyroid surgeries [28]. By delineating the course of STA, the course of ebSLN can be ascertained, thus minimizing the risk of irritation or damage to the nerve. Such undesirable effects would be associated with hoarseness shortly after the procedure or generalized speech problems.

The results of this review are summarized in Table 4.

CONCLUSIONS

Analysis of the current literature revealed significant discrepancies in the sites of origin of the superior thyroid artery (STA). In the studies by Gupta, Shivaleela, Shredharan, Munjakmar, Herrera-Núñez, Esen, Bhardwaj and Adachi, the most common site of origin of the STA was the external carotid artery (type III). In Manjappa's study, the majority of variants originated from the common carotid artery (type II). In the studies by Vazquez and Natsis, the largest proportion of results showed the STA originating from the common bifurcation (type I). Interestingly, only one study demonstrated a single case of the STA originating as a common trunk with the lingual artery and facial artery (type IVb) (Vazquez [6]). This was the only instance of such an origin among all the studies described.

The diverse proportions of STA origins in the mentioned studies emphasize the particular importance of understanding anatomical variations in the origin of the STA, especially for surgeons involved in neck surgery, to minimize complications following procedures in this region, such as thyroidectomies or neck tumour resections. The differences in the proportions of specific sites of origin between the

Table 4. Frequency of origin of the superior thyroid artery (STA)

Study (year)	Study type (diagnostic tool)	No. of subjects	Type I	Type II	Type III	Type IVa	Type IVb
Adachi (1928)	Cadaveric	300	81 (27.0%)	39 (13.0%)	177 (59.0%)	6 (2.0%)	0 (0%)
Vazquez (2009)	Cadaveric	207	102 (49.3%)	55 (26.6%)	48 (23.2%)	2 (0.6%)	1 (0.3%)
Natsis (2011)	Cadaveric	100	49* (49.0%)	12* (12.0%)	39* (39.0%)	3 (3.0%)	0 (0%)
Gupta (2014)	DSA	25**	5 (20.0%)	1 (4.0%)	18 (72.0%)	0 (0%)	0 (0%)
Shivaleela (2016)	Cadaveric	84	18 (21.4%)	2 (2.4%)	64 (76.2%)	0 (0%)	0 (0%)
Esen*** (2018)	CT-angiography	1280	279 (21.8%)	316 (24.7%)	667 (52.1%)	0 (0%)	0 (0%)
Sreedharan (2018)	Cadaveric	60	5 (8.3%)	2 (3.3%)	53 (88.3%)	0 (0%)	0 (0%)
Herrera-Núñez**** (2020)	CT-angiography	152	31 (20.4%)	26 (17.1%)	77 (50.7%)	16 (10.5%)	0 (0%)
Munjamkar (2020)	Cadaveric	100	5 (5.0%)	24 (24.0%)	71 (71.0%)	0 (0%)	0 (0%)
Anand (2021)	Cadaveric	80	32 (40.0%)	16 (20.0%)	32 (40.0%)	0 (0%)	0 (0%)
Manjappa (2021)	Cadaveric	40	2 (5.0%)	25 (62.5%)	11 (27.5%)	2 (5.0%)	0 (0%)
Bhardwaj (2023)	CT-angiography	210	30 (14.3%)	18 (8.6%)	162 (77.1%)	0 (0%)	0 (0%)

*Includes one origin of the thyrolingual trunk at the given level; **Includes one origin of STA from the internal carotid artery (ICA); *** Of the remaining 1.4%, STA was found to be missing; **** Of the remaining 1.3%, STA was found to be missing

described studies underscore the need for conducting more extensive research on large cadaveric samples, and studies collecting results from angiographic investigations, to better comprehend the variability in the origin of the superior thyroid artery in different populations.

Acknowledgement

The authors extended their gratitude to Magdalena Chmiel, MD, for creating the illustration for the review.

Disclosures

All authors have read and agreed with the published version of the manuscript.

Conflict of interest: The authors declare no conflict of interest.

Funding statement: No external funding was received to perform this review.

Statement of data availability: not applicable

Statement of institutional review committee: not applicable

Statement of informed consent: Permission was obtained to use images from the computer tomography study (Fig. 1) conducted at the Department of Medical Radiology I, Medical University of Lublin, and to use photographic of anatomical material (Fig. 2.) from the Department of Correct, Clinical, and Imaging Anatomy at the Medical University of Lublin. Figure 3 is published with the author's informed consent.

REFERENCES

- Bochenek A, Reicher M. Anatomia człowieka. Vol 3. 9th ed. PZWL; 2012.
- Sharma N, Pandit R, Neupane B, Sah RP, Bhattarai L, Yadav PK. Right External Carotid Artery Originated Right Superior Thyroid Artery in Cadavers of a Medical College in Nepal: A Descriptive Cross-sectional Study. *JNMA J Nepal Med Assoc.* 2021;59(241):906–909. doi:10.31729/jnma.6419
- Williams L, Warwick R, Dyson M, Bannister LH. Gray's anatomy. 37th ed. Churchill Livingstone, 1989.
- Ganorkar YS, Ramteke M, Radke A, Gandhi Govt I. Anatomical Variation of Left Superior Thyroid Artery: A Case Report. *IOSR Journal of Dental and Medical Sciences (IOSR-JDMS) e-ISSN.* 2016;15(2):69–70. doi:10.9790/0853-15276970
- Branca JJV, Lascialfari Bruschi A, Pilia AM, et al. The Thyroid Gland: A Revision Study on Its Vascularization and Surgical Implications. *Medicina (Kaunas).* 2022;58(1):137. doi:10.3390/medicina58010137
- Vázquez T, Cobiella R, Marañillo E, et al. Anatomical variations of the superior thyroid and superior laryngeal arteries. *Head Neck.* 2009;31(8):1078–1085. doi:10.1002/HED.21077
- Natsis K, Raikos A, Foundos I, Noutsios G, Lazaridis N, Njau SN. Superior thyroid artery origin in Caucasian Greeks: A new classification proposal and review of the literature. *Clin Anat.* 2011;24(6):699–705. doi:10.1002/CA.21181
- Shivaleela C, Anupama D, Subhash RLP. STUDY OF ANATOMICAL VARIATIONS IN THE ORIGIN OF SUPERIOR THYROID ARTERY. *Int J Anat Res* 2016;4(1):1765–1768. DOI: 10.16965/ijar.2015.327
- Sreedharan R, Krishna L, Shetty A. Origin of superior thyroid artery: under the surgeon's knife. *J Vasc Bras.* 2018;17(4):290–295. doi:10.1590/1677-5449.004218
- Munjamkar, Prashant et al. ANATOMICAL STUDY OF VARIATIONS IN THE ORIGIN OF SUPERIOR THYROID ARTERY. *International Journal of Approximate Reasoning* (2020): 1–3. doi:10.36106/ijar
- T M, Pandit R. Anatomical Variations in the Origin of Superior Thyroid Artery and its Relation with External Laryngeal Nerve and their Clinical Importance-A Cadaveric Study. *Journal of Universal College of Medical Sciences.* 2021;9(01):33–37. doi:10.3126/JUCMS.V9I01.37964
- Adachi B. Das Arteriensystem der Japaner. Verlag der Kaiserlich-Japanischen Universität zu Kyoto, 1928.

13. Gupta P, Bhalla AS, Thulker S, et al. Variations in superior thyroid artery: A selective angiographic study. *Indian J Radiol Imaging*. 2014;24(1):66. doi:10.4103/0971-3026.130701
14. Herrera-Núñez M, Menchaca-Gutiérrez JL, Pinales-Razo R, et al. Origin variations of the superior thyroid, lingual, and facial arteries: a computed tomography angiography study. *Surg Radiol Anat*. 2020;42(9):1085–1093. doi:10.1007/S00276-020-02507-6
15. Esen K, Ozgur A, Balci Y, Tok S, Kara E. Variations in the origins of the thyroid arteries on CT angiography. *Jpn J Radiol*. 2018;36(2):96–102. doi:10.1007/S11604-017-0710-3
16. Anand A, Metgudmath RB, Belaldavar BP. Topographic Evaluation of Superior Thyroid Artery-A Terrain to be Well Versed for Surgeon's Knife. *Indian Journal of Otolaryngology and Head & Neck Surgery*. 2022;74(Suppl 3):5994. doi:10.1007/S12070-021-02643-4
17. Bhardwaj Y, Singh B, Bhadoria P, Malhotra R, Tarafdar S, Bisht K. Computed tomography angiographic study of surgical anatomy of thyroid arteries: Clinical implications in neck dissection. *World J Radiol*. 2023;15(6):182. doi:10.4329/WJRV15.16.182
18. Liu J, Sun W, Dong W, et al. Risk factors for post-thyroidectomy haemorrhage: A meta-analysis. *Eur J Endocrinol*. 2017;176(5):591–602. doi:10.1530/EJE-16-075
19. Wojtczak B, Aporowicz M, Kaliszewski K, Bolanowski M. Consequences of bleeding after thyroid surgery – analysis of 7805 operations performed in a single center. *Arch Med Sci*. 2018;14(2):329. doi:10.5114/AOMS.2016.63004
20. Frank ED, Park JS, Watson W, Chong E, Yang S, Simental AA. Total thyroidectomy: Safe and curative treatment option for hyperthyroidism. *Head Neck*. 2020;42(8):2123–2128. doi:10.1002/hed.26148
21. Lemke J, Schreiber MN, Henne-Bruns D, Cammerer G, Hillenbrand A. Thyroid gland hemorrhage after blunt neck trauma: case report and review of the literature. *BMC Surg*. 2017;17(1). doi:10.1186/S12893-017-0322-Y
22. Gates C, Newby M, Stokes W, Boo S, Carr M. Embolization of a Superior Thyroid Artery Hemorrhage after Fine-Needle Aspiration Biopsy of a Thyroid Nodule. *Case Rep Otolaryngol*. 2020;2020:1–4. doi:10.1155/2020/3727696
23. Correia S, Ramalho D, Rocha G, Oliveira MJ. Extracapsular Cervical Hematoma After Thyroid Fine-Needle Aspiration Cytology. *Cureus*. 2022;14(9):e29710. doi:10.7759/cureus.29710
24. Dimic A, Davidovic L. Superior Thyroid Artery Perforation During Carotid Artery Stenting. *Eur J Vasc Endovasc Surg*. 2020;59(2):294. doi:10.1016/j.ejvs.2019.11.013
25. Hao S, Quan Z, Wang Y, Wang C. Cervical hematoma caused by accidental injury of superior thyroid artery: A rare complication of internal jugular vein catheterization. *Asian J Surg*. 2023;46(3):1321–1322. doi:10.1016/j.asjsur.2022.08.094
26. Peng X, Wu S, Bie C, Tang H, Xiong Z, Tang S. Mean peak systolic velocity of superior thyroid artery for the differential diagnosis of thyrotoxicosis: a diagnostic meta-analysis. *BMC Endocr Disord*. 2019;19(1):56. doi:10.1186/s12902-019-0388-x
27. Wang C, Zhu Y, Zhou L, Zhao Y, Han X, Ji L. [Application of the superior thyroid artery peak systolic velocity in differentiating Graves' disease from autoimmune thyroiditis]. *Zhonghua nei ke za zhi*. 2020;59(3):207–212. doi:10.3760/CMA.J.ISSN.0578-1426.2020.03.007
28. Cha YH, Moon SY, Jehoon O, Tansatit T, Yang HM. Anatomy of the external branch of the superior laryngeal nerve in Asian population. *Sci Rep*. 2017;7(1):14952. doi:10.1038/s41598-017-15070-9