



# A 9-year-old patient with severe haemophilia A complicated by factor VIII inhibitor treated with emicizumab – case report and literature review

Justyna Małgorzata Tomasik<sup>1,2,A-F</sup>✉, Joanna Szuba<sup>1,2,A-D</sup>, Kacper Chrostowski<sup>1,B-D</sup>,  
Irena Woźnica-Karczmarz<sup>3,1,A,E-F</sup>

<sup>1</sup> Medical University, Lublin, Poland

<sup>2</sup> Student Research Group at the Department of Hematology, Oncology and Children's Transplantology, Medical University, Lublin, Poland

<sup>3</sup> Department of Transfusion Medicine, Children's University Hospital, Lublin, Poland

A – Research concept and design, B – Collection and/or assembly of data, C – Data analysis and interpretation, D – Writing the article, E – Critical revision of the article, F – Final approval of the article

Tomasik JM, Szuba J, Chrostowski K, Woźnica-Karczmarz I. A 9-year-old patient with severe haemophilia A complicated by factor VIII inhibitor treated with emicizumab – case report and literature review. *J Pre-Clin Clin Res.* 2024; 18(2): 128–134. doi: 10.26444/jpccr/187549

## Abstract

**Introduction.** The case is presented of a 10-year-old boy with severe Haemophilia A, in whom standard therapy led to the development of an inhibitor to factor VIII. Immunological tolerance induction (ITI) did not yield the expected result, and inhibitor titers were not reduced. Due to numerous recurrent bleeds, prophylaxis with activated prothrombin complex concentrate (aPCC) was initiated, with recombinant factor VIIa administered in the case of bleeding episodes. Despite second and third-line ITI treatments, desired outcomes were not achieved, leading to therapy discontinuation and initiation of emicizumab treatment. The new therapy significantly reduced bleeding occurrences.

**Results.** This case clearly illustrates the greater efficacy of emicizumab compared to other drugs, confirming its application in patients with developed factor VIII inhibitors where ITI therapy was ineffective. Prophylaxis with this antibody significantly reduces bleeding frequency and improves the patient's quality of life.

## Key words

inhibitor, haemophilia A, emicizumab.

## INTRODUCTION

Haemophilia A is a rare genetic bleeding disorder. According to the Guidelines for the Management of Uncomplicated Haemophilia A and B with Inhibitors, haemophilia occurs with a frequency of 1:10,000 births. It is estimated that approximately 80–85% of all haemophilia patients have haemophilia A, while only 15–20% have haemophilia B. According to data from the World Federation of Haemophilia (WFH) published in 2010, the number of people worldwide with the disorder is approximately 400,000. The prevalence of the disorder haemophilia A and B in Poland has been estimated at 1:12,300 inhabitants. Spontaneous mutations occur in about 30–50% of Polish patients, with a negative family history. About 2,200 patients have been entered in Polish registries; however, the data is incomplete and does not cover all patients [1–4].

Haemophilia A is characterized by a complete lack or deficiency of factor VIII clotting factor. Symptoms include spontaneous and traumatic bleeding into joints and muscles, soft tissues, internal organs, and bleeding from the oral and nasal mucosa [5]. Diagnosis is established based on laboratory test results and collected medical history. Therapy is based on administering factor VIII concentrate to patients. The most serious complication of treating haemophilia A is the development of inhibitors to factor VIII, which renders factor

VIII substitution therapy ineffective [6, 7]. A new possibility has emerged with the approval of emicizumab worldwide – a monoclonal, bispecific antibody that bridges active factor IX with factor X, mimicking the activity of active factor VIII, thus enabling effective haemostasis [8–10].

## CASE REPORT

A 7-year-old boy was diagnosed with severe haemophilia A shortly after birth. On the second day of life, he experienced gastrointestinal bleeding. Prior to receiving fresh frozen plasma, haemostatic system tests were conducted, revealing prolonged activated partial thromboplastin time (APTT) and factor VIII activity of 0.6%. Genetic testing revealed an intron 22 inversion mutation. At 9 months of age, the patient was enrolled in an early prophylactic bleeding programme with low doses of recombinant factor VIII. Before this, the child experienced a haematoma on the thigh after vaccination and bleeding from the gums, which was not treated with factor VIII. Due to the child's high activity level, early acquisition of walking skills, and high risk of injury, therapy was initially administered once a week. Despite proper treatment, the boy experienced muscle bleeding in the buttocks after trauma, bleeding into the wrist after blood sampling, and spontaneous bleeding into the right ankle joint, necessitating additional doses of factor VIII. Further treatment proved ineffective, and joint bleeding was halted by using recombinant factor VIIa (rVIIa). After 12 days of exposure, the factor VIII inhibitor titer was measured at 15.8 Bethesda units per milliliter (BU/

✉ Address for correspondence; Justyna Małgorzata Tomasik, Medical University, Aleje Raclawickie 1, 20-059 Lublin, Poland  
E-mail: j.tomasik1995@gmail.com

ml), leading to the decision to discontinue coagulation factor therapy.

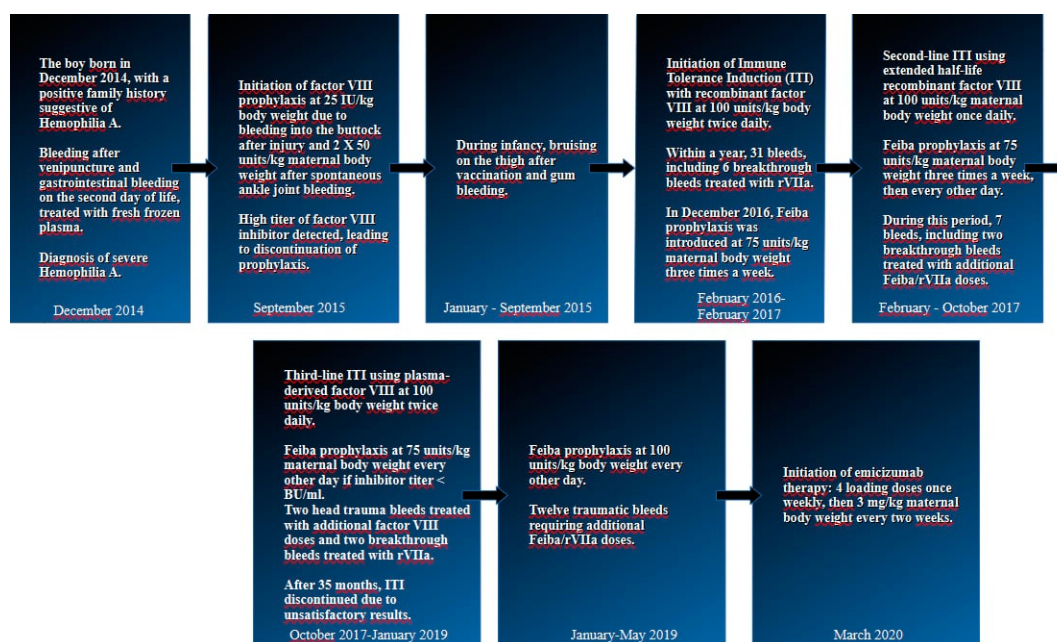From February 2016, the boy underwent immune tolerance induction (ITI) therapy, receiving recombinant factor VIII twice daily. The inhibitor titer, which was 6.0 BU/ml before treatment, increased to 18.0 BU/ml during therapy, then decreased to 3.9 BU/ml after 2 months. After fluctuating inhibitor levels, the highest titer of 43.7 BU/ml was reached in January 2017. Despite 12 months of therapy, a 20% reduction in inhibitor titer was not achieved, leading to the patient's exclusion from the clinical trial. Due to recurrent bleeding episodes, prophylactic bleeding treatment with activated prothrombin complex concentrate (aPCC) was initiated in December 2016, initially administered 3 times a week, then every other day. Recombinant factor VIIa was used for bleeding episodes, with dosing adjusted based on the type of bleeding. From February 2017 – October 2017, the patient received a second-line ITI using extended half-life recombinant factor VIII (efmoroctocog alfa). The regimen involved daily morning dosing. During therapy, 7 bleeding episodes occurred, including 2 joint bleeds treated with higher doses of aPCC or rVIIa. From October 2017 – January 2019, a third-line ITI using plasma-derived factor VIII was administered twice daily. However, during this period, the patient experienced bleeding after head trauma and into the right ankle and elbow joints. After 35 months of continuous therapy, ITI was discontinued in January 2019 due to lack of expected results.

Following ITI cessation, the patient received aPCC daily and rVIIa every other day for prophylaxis and bleeding treatment. In November 2019, the factor VIII inhibitor titer was 1.74 BU/ml. Despite appropriately managed prophylaxis, the patient continued to experience numerous post-traumatic bleeds. In January 2020, the patient remained on prophylactic treatment with a coagulation factor complex against factor VIII inhibitors daily and recombinant factor VIIa every other day. Due to unsatisfactory treatment outcomes, efforts were made to enroll the patient in emicizumab therapy. In February

2020, the patient continued to experience numerous bruising on both lower limbs and bruises on both forearms. In March 2020, the patient was enrolled in emicizumab therapy under the National Haemophilia Treatment Programme. Before starting therapy, the inhibitor titer was measured at 1.29 BU/ml. The dosing regimen, adjusted to the child's weight (18 kg), included a loading dose of 3 mg/kg body weight once a week for 4 weeks, followed by maintenance doses of 3 mg/kg body weight every 2 weeks. The patient received 54 mg of emicizumab subcutaneously during the loading doses. No adverse effects were observed after administration.

The patient's condition improved immediately after starting emicizumab therapy – subsequent visits showed no bruises, and bleeding did not occur. A one-stage haemostasis assay was performed after the first loading dose. All parameters were normal, but the result was unreliable due to the drug's mechanism of action. Periodic APTT testing was recommended to monitor the drug's effect, as prolongation of shortened APTT would indicate the development of drug antibodies. In April 2020, the first maintenance dose of the drug was administered subcutaneously. Subsequently, the therapy was continued by the trained mother administering 54 mg of emicizumab every 2 weeks at home. In the 14th week of therapy, the child weighed 19 kg, necessitating an increase in the maintenance dose to 57 mg. Upon physical examination after a strong hit to the right tibia, the child exhibited scraped skin and slight bruising, similar to that of a healthy child. No increase in haematoma was observed. The factor VIII inhibitor titer measured by chromogenic method in April 2020 was 1.65 BU/ml. The patient gradually gained weight, and by the 23rd week of therapy, the maintenance dose was increased to 60 mg. The patient weighed 19.6 kg and measured 116.5 cm in height. Figure 1. summarizes the treatment methods used for the child until initiation of emicizumab therapy.

In November 2020, the boy sustained a significant cheek injury after hitting a chair. Cold compresses were applied. The patient did not require any haemostatic



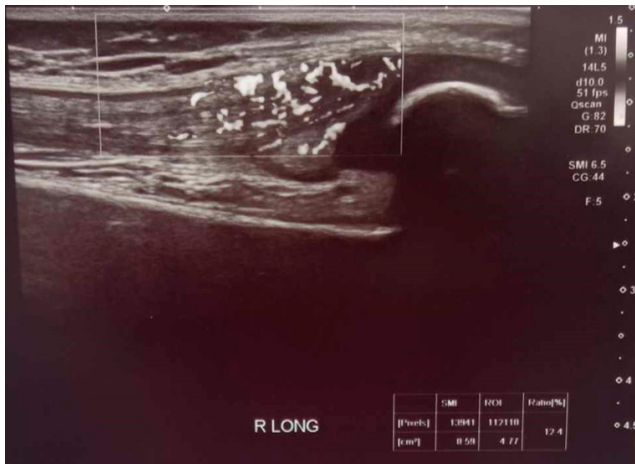
**Figure 1.** Timeline illustrating the patient's therapeutic process from birth to initiation of emicizumab treatment.

Source: Own work based on patient documentation

medications. The next day after the injury, there was no evidence of haematoma formation.

In March 2021, ultrasound evaluation of the joints was performed. No pathological changes or significant synovial hypertrophy were observed. Minor injuries in March and April 2021 did not require treatment. In May 2021, a non-displaced supracondylar fracture of the right humerus occurred. Prophylactically, 1 mg of recombinant factor VIIa was administered before applying the cast. In case of signs of bleeding into the joint, re-administration of recombinant factor VIIa was recommended, but was not necessary.

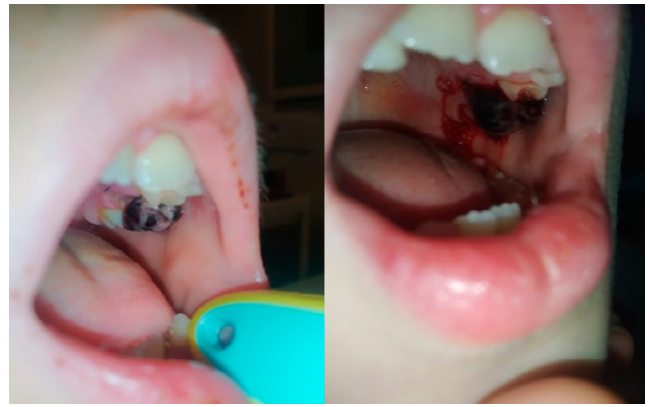In August 2021, the boy reported morning pain in the right knee joint, making it difficult to descend stairs. In ultrasound, inflammatory changes in the right knee joint were detected. In September 2021, the patient was hospitalized in the Rheumatology Department for diagnostic purposes. The boy required observation for juvenile idiopathic arthritis with accompanying enthesitis. Treatment with sulfasalazine and local procedures was initiated.



**Figure 2.** Inflammatory changes in the knee joint visualized in September 2021

During a follow-up visit in November 2021, the boy reported poor tolerance to treatment – weight loss, abdominal pain, and decreased appetite occurred. Additionally, the patient complained of left knee and right hip joint pain in July 2022. Ultrasound of the joints and rheumatological consultation were recommended. No inflammatory changes were found in the hip joints or the right knee joint, while discrete swelling of the iliotibial tract was detected in the left knee joint. In September 2022, the patient sustained an injury while jumping, resulting in swelling around the right ankle joint. At the Emergency Department, the patient received 2 doses of Novoseven, and when the swelling did not subside, it was decided to administer another 2 doses of Novoseven the next day. In February 2023, the patient underwent removal of a deciduous tooth root, but recombinant factor VIIa was not administered post-procedure, and tranexamic acid was given with delay. Three days later, a haemorrhagic cyst appeared, and subsequently, the boy was readmitted to the Maxillofacial Surgery Department. The cyst was removed, recombinant factor VIIa was administered 3 times, and the patient was discharged home after 2 days. In December 2023, no excessive bleeding was observed after the patient's deciduous teeth fell out.

Since the initiation of emicizumab treatment, episodes of right humeral bone fracture and the occurrence of a



**Figure 3.** Haemorrhagic cyst formed after removal of the deciduous tooth root

haemorrhagic cyst after removal of the deciduous tooth root were the only situations requiring administration of bypassing agents to the patient. Despite a reduction in bleeding incidents, the patient still experiences pain in the right knee joint. He was referred to the Psychological-Pedagogical Clinic for individualized educational support. Observations during medical visits indicate attention deficit in the boy, sometimes accompanied by lack of behavioural control and excessive emotional response to stressful situations. This may be related, among other factors, to the severity of the underlying disease and the necessity of permanent medication intake according to a specific schedule. Currently, the boy feels well and is developing normally. He does not experience any joint bleeds. Range of motion in the ankle, knee, and elbow joints is within normal limits. The patient attends prophylactic visits once every 2 months, and regular laboratory tests are performed. The inhibitor titer, measured by chromogenic method since the initiation of emicizumab treatment, has decreased to 0 BU/ml. Additionally, APTT values remain within the normal range. Table 1 presents the results of laboratory tests before and during emicizumab therapy. The patient's blood morphology and iron metabolism parameters have also improved.

## DISCUSSION

Haemophilia is a rare inherited disorder and the most common cause of serious coagulation abnormalities, occurring from birth and lasting throughout life. It is characterized by a deficiency or absence of one of the clotting factors due to damage to the gene responsible for its production: haemophilia A – factor VIII, haemophilia B – factor IX, haemophilia C – factor XI. Haemophilias A and B are inherited in an X-linked recessive manner, resulting in a much higher prevalence among males, while females are carriers. Haemophilia C may occur regardless of gender and is inherited in an autosomal recessive pattern. In approximately 1/3 of cases, haemophilia may result from a new genetic mutation in the FVIII gene located on the X chromosome. The most common genetic defect is intron 22 inversion, which occurs in about 45% of patients with severe haemophilia A (HA) [11 – 13]. One of the most serious complications of haemophilia treatment is the development of inhibitors to factor VIII by the body. These are polyclonal IgG alloantibodies directed against exogenous factor VIII protein, which block its function in activating factor X, making bleeding control difficult. The

**Table 1.** Comparison of test results before the use of emicizumab and during the therapy [Self-prepared based on patient documentation]

Selected blood laboratory tests	Results before emicizumab therapy – March 2020	Results 1 week after emicizumab administration	Results 4 weeks after emicizumab administration	Results 32 weeks after starting therapy	Results 1 year after starting emicizumab therapy	Results 67 weeks after starting therapy	Results 2 years after starting emicizumab therapy	Results 3 years after starting therapy	Results 3 years and 9 months into treatment (December 2023)
Leukocytes [thousands/ $\mu$ l] normal range: 3.4-9.5	7.39	Not tested	5.28	13.50	5.79	6.92	9.30	7.43	4.56
Erythrocytes [millions/ $\mu$ l] normal range: 4.2-5.1	4.40	Not tested	4.31	4.51	4.91	4.57	4.65	4.65	4.52
Haemoglobin [g/dl] normal range: 12-14	11.4	Not tested	10.9	12.1	13	12.4	12.3	12.1	12.30
Haematocrit [%] normal range: 35-42.4	34.2%	Not tested	33.4%	35.6	39.1%	37.0%	37.6%	37.0%	37.60
Platelets [thousands/ $\mu$ l] normal range: 140-420	377	Not tested	316	267	337	309	323	308	351
Iron [ $\mu$ g/dl] normal range: 25-115	52.0	Not tested	42	19.0	91	101.0	Not tested	51	64
Ferritin [ng/ml] normal range: 4-67	13.80	Not tested	7	26.40	10.30	9.10	Not tested	17.60	26
Transferrin [mg/dl] normal range: 215-365	322.00	Not tested	364	317.00	319	326.00	Not tested	312	292
Transferrin saturation index [%] Normal range: 20-50	11.5 %	Not tested	8.2%	4.3%	20.2%	22%	Not tested	11.6%	16%
Factor VIII [%] Normal range: 50-150	0 %**	Not tested	484% *	361% * i 0% **	Not tested	0% **	Not tested	Not tested	Not tested
Inhibitor titer to factor VIII [BU]	1.35 **	1.29 **	Not tested	1.3 **	0.62 **	0 **	0.4 **	Not tested	0 ** – absent
APTT-time [s] Normal range: 25.4-36.9	120	31.2	26.7	26.0	25.0	24.5	26.7	26.2	26.6
PT-time [s] Normal range: 10.6-14.2	Not tested	13.0	13.5	Not tested	Not tested	13.2	13.5	13.0	13.2
PT-INR Normal range: 0.90-1.20	Not tested	1.10	1.14	Not tested	Not tested	1.12	1.14	1.10	1.12
Fibrinogen [g/l] Normal range: 2.00-4.00	Not tested	1.99	2.22	Not tested	Not tested	4.21	3.08	2.88	3.12

\* Test performed using a single-stage method; \*\* Test performed using a chromogenic method

complication of substitution therapy in the form of inhibitor development to factor VIII occurs in 15 – 35% of individuals with severe forms of the disease and in 3 – 13% of patients with moderate and mild variants. The development of inhibitors is influenced by many factors, including individual patient characteristics (genetic factors, immune response, ethnic origin), as well as treatment-related factors (duration and intensity of treatment, age at first exposure, and types of products) [14]. In some cases, inhibitors may spontaneously disappear, and then factor replacement therapy becomes fully effective [12].

In severe haemophilia A, most inhibitors appear in early childhood. It is estimated that the risk of inhibitor development is highest by the fifth year of life and during the first 50 days of exposure to clotting factor [2, 12, 14]. The first symptoms of haemophilia mainly appear in the second half of infancy when the child becomes more physically active, begins to crawl and walk. Among them, joint bleeds are most common (most commonly in the knee, elbow, and ankle joints) – typically from the age of 2 – 3 years, as well as bleeds into soft tissues and muscles (e.g., thigh muscles after vitamin K administration or HBV vaccination or into the buttocks). Additionally, bleeding from the oral cavity due to injury, during tooth eruption, or biting the tongue is observed, along with increased bruising and bleeding

into the central nervous system, abdominal cavity, pleural or peritoneal cavity, nose, or genital organs following even minor trauma [14, 15].

The diagnosis of haemophilia is established based on laboratory test results, clinical features, and a carefully collected medical history, considering bleeding disorders present in the family. Prenatal genetic testing is proposed to families burdened with this disease, involving sampling of chorionic villi or amniocentesis. Testing for haemophilia can also be performed from the umbilical cord blood of a newborn immediately after birth in patients with a high suspicion of haemophilia or a positive family history. After the prenatal period, tests include blood morphology, prothrombin time (PT), and activated partial thromboplastin time (APTT), among others. Diagnosis of haemophilia is expedited by a positive family history. In both haemophilia A and B, APTT will be prolonged (indicating an intrinsic pathway disorder), while PT will remain normal. APTT may be prolonged up to 2 – 3 times the upper limit of the normal range. The next step should be determination of the activity of factors VIII and IX. Haemophilia is usually diagnosed if factor activity is less than 40% of normal activity. Subsequently, molecular genotyping should be proposed to confirm the diagnosis and aid in predicting disease severity. Genetic assessment is important for determining the disease biology,

establishing a diagnosis in difficult cases, predicting the risk of developing inhibitors, and providing prenatal diagnosis [3, 14, 16]. Table 2 presents the classification of haemophilia based on coagulation factor activity [15].

**Table 2.** Classification of disease severity based on coagulation factor levels [15]

Classification of severity of haemophilia A	Mild	Moderate	Severe
Level of clotting factor in the blood, expressed as a percentage	5-40 %	1-5 %	Less than 1%

Treatment of haemophilia type A has both prophylactic and symptomatic dimensions, based on intravenous administration of plasma-derived or recombinant factor VIII concentrates to patients. Prophylactic treatment aims to prevent bleeding episodes, while symptomatic treatment, also known as 'on-demand' treatment, is administered immediately after a bleeding episode occurs. Typically, patients with severe haemophilia regularly use factor VIII several times a week to reduce the frequency of bleeds [1, 17–19]. Home therapy provides patients with access to coagulation factor concentrates and other haemostatic agents, reducing the number of hospitalizations and bleeding complications. Implementation of home therapy should follow prior education and training of the patient and parents/guardians. The medical team must monitor home treatment [4, 20]. Another medication is desmopressin, which is used in cases of mild, less frequently moderate haemophilia. According to the World Federation of Haemophilia, children should receive desmopressin no more than once daily for 3 consecutive days [4].

Treatment for patients who develop inhibitors aims to permanently eliminate the inhibitor and inhibit bleeding episodes. Elimination of the inhibitor is possible in some cases through the introduction of immune tolerance induction (ITI). This involves the intravenous administration of large doses of factor VIII. In practice, a high-dose regimen (factor VIII concentrate 100–200 IU/kg/day) is more commonly used than a low-dose regimen (factor VIII concentrate 50 IU/kg 3 times per week) [2, 4]. If ITI fails to achieve immunotolerance after 33 months of therapy, it should be discontinued [21]. Treatment of active bleeding and its prophylaxis in inhibitor-complicated haemophilia involves the administration of large doses of human factor VIII concentrates (only with a low inhibitor titer) and bypassing agents – activated prothrombin complex concentrates (aPCC) and recombinant activated factor VII (rFVIIa) [22].

The introduction of emicizumab has brought new possibilities in therapy. Emicizumab is a humanized, recombinant, bispecific monoclonal antibody. It has been shown to bridge active factor IX with factor X and mimic the function of active factor VIII. However, it does not have a similar structure to factor VIII, so antibodies neutralizing factor VIII do not affect emicizumab. In Poland, it is indicated for prophylactic use in patients with severe haemophilia A complicated by a high-titer inhibitor. It is administered subcutaneously, in a loading dose of 3 mg/kg body weight once a week for the first 4 weeks. Then, from the 5th week onwards, the maintenance dose is 1.5 mg/kg body weight once a week, 3 mg/kg body weight once every 2 weeks, or 6 mg/kg body weight once every 4 weeks. Laboratory tests using a one-stage method show a shortened APTT and falsely elevated factor VIII activity.

In the case of acute bleeding during emicizumab treatment, rFVIIa is administered [23–27]. Data from clinical trials HAVEN 1–7 indicate the high effectiveness of emicizumab in preventing bleeding episodes in both children and adults with haemophilia A, regardless of the presence of factor VIII inhibitors. The latest HAVEN 7 study provides safety profile data and high efficacy of emicizumab use in infants (below 12 months of age) with severe haemophilia A without inhibitors. The available safety data of emicizumab use in real-world clinical practice are promising for patients and suggest that the indications for using this drug will continue to expand [28]. The latest meta-analysis showed that using emicizumab for haemophilia prophylaxis allows for a greater reduction in bleeding episodes than prophylaxis with factor VIII concentrates or bypassing agents, both in patients with and without factor inhibitors. The most common adverse reaction was injection site reaction [29]. Laboratory studies in patients receiving emicizumab show a decrease in factor VIII inhibitor titer [23]. An additional advantage of emicizumab therapy is the convenient route of administration in the form of subcutaneous injections once a week, once every 2 weeks, or once a month. This suggests that patient adherence to recommendations will be satisfactory [28, 29].

After the introduction of prophylaxis with emicizumab, many researchers have focused on comparing bleeding frequencies before and after the introduction of this antibody. Glonnegger H. et al. presented the results of emicizumab treatment in a group of 13 paediatric patients with haemophilia A. They assessed parameters such as annualized bleeding rate (ABR), annualized joint bleeding rate (AJBR) and annualized spontaneous bleeding rate (ASBR) before and after emicizumab treatment. Moreover, the annual bleeding rate (ABR) was calculated to take into account the different duration of therapy with prophylactic FVIII and emicizumab. A significant decrease in rates such as median total ABR (0.25 vs. 0), median spontaneous ABR (0.05 vs. 0), median traumatic ABR (0.23 vs. 0), and median joint ABR (0.06 vs. 0) was observed. Only one patient experienced traumatic bleeding. A significant difference was noted in spontaneous ABR, which significantly decreased after emicizumab therapy in patients under 6 years of age compared to patients over 6 years of age ( $p=0.016$ ) [30].

On the other hand, Liu G. et al. described another group of paediatric patients from the Beijing Children's Hospital in China treated with emicizumab, consisting of 11 patients with severe haemophilia A and 2 with moderate forms. The percentage of patients without bleeding increased from 7% to 46%. Compared to patients without inhibitors, patients with FVIII inhibitors showed greater improvement in ABR (7.5 vs. 2.0;  $p=0.01$ ) compared to patients without inhibitors. In 5 patients with positive test results, the inhibitor titer was reduced [31]. Long-term assessment of the course and effects of treatment with the modern antibody is crucial. Hassan E. et al. described the course of emicizumab treatment in 52 paediatric patients from the Children's Hospital in Birmingham, UK, between 2018 – 2021. Three patients discontinued emicizumab therapy due to adverse events, and 4 patients experienced serious side-effects, such as severe headaches, serious bleeding, development of anti-drug antibodies (ADAs), and recurrence of inhibitors, while mild side-effects of treatment were reported by 4 patients [32]. The clinical case of Ahn J.H. et al. presents a 35-month-old Korean boy with severe haemophilia A and a high titer of

inhibitors. Since the age of 23 months, the patient has been eligible for emicizumab treatment. Initially, an induction dose of 3 mg/kg emicizumab was injected every week for 4 weeks, followed by a maintenance dose of 1.5 mg/kg emicizumab every week for 10 weeks, and then emicizumab was administered at a dose of 3 mg/kg every 2 weeks. After 6 months of therapy, the chemoport was removed without the use of other haemostatic agents, and no complications were observed. During emicizumab prophylaxis, no bleeding was observed compared to treatment with bypassing agents (BPA) – 46 bleeding episodes occurred in the previous year before emicizumab was initiated [33].

## CONCLUSIONS

Emicizumab therapy may yield satisfactory results in patients with severe haemophilia A complicated by factor VIII inhibitor development, in whom immune tolerance induction (ITI) therapy did not produce the expected effects. Emicizumab prophylaxis eventually led to a decrease in factor VIII inhibitor titer, reduction in the frequency and severity of haemophilia A symptoms, and the need for frequent hospital visits, thereby improving the boy's quality of life. The reduction in bleeding episodes in the patient resulted in improvements in his blood morphology and effective treatment of anaemia: haematocrit, haemoglobin, and iron levels increased, and APTT shortened. Thus far, the medication has also proven to be safe, with no reported adverse events during therapy. However, the occurrence of a haematoma after a dental procedure and the need for hospitalization remind the patient of the risks associated with his condition despite the therapy's effectiveness, necessitating regular follow-up visits. Additionally, the use of emicizumab for prophylaxis is associated with benefits that can significantly ease the patient's burden. In the presented case, the maintenance dosing schedule was favourable because the medication was administered subcutaneously only once every 2 weeks, while other drugs require frequent intravenous administration. Moreover, the subcutaneous route of administration allows for caregiver administration after appropriate training, not just by a physician. Emicizumab should be prescribed early in children with haemophilia type A, especially those who have failed ITI therapy, due to the reduction in bleeding frequency and improvement in patient's quality of life.

Considering the high costs of previous bypassing agent prophylaxis and the high efficacy combined with the lack of adverse effects of emicizumab, this medication has proven to be a good choice for further therapy of haemophilia A in the boy.

## REFERENCES

- Windygą J, Chojnowski K, Klukowska A, et al. Part I: Guidelines for the management of uncomplicated haemophilia A and B with inhibitors to factor VIII and IX (updated edition). *Acta Haematol Pol.* 2016;47(2):86–114. doi:10.1016/J.ACHAEM.2016.04.009
- Windygą J, Chojnowski K, Klukowska A, et al. Part II: Guidelines for the management of complicated haemophilia A and B with inhibitors to factor VIII and IX (2nd edition). *Acta Haematol Pol.* 2017;48(3):137–159. doi:10.1016/J.ACHAEM.2017.08.001
- Srivastava A, Brewer AK, Mauser-Bunschoten EP, et al. Guidelines for the management of haemophilia. *Haemophilia.* 2013;19(1):e1–e47. doi:10.1111/J.1365-2516.2012.02909.X
- Makris M, Kasper C. The World Federation of Haemophilia guideline on management of haemophilia. *Haemophilia.* 2013;19(1):1–1. doi:10.1111/HAE.12074
- García J, Hammer MR, Zia A. Serious bleeds in pediatric persons with haemophilia A on emicizumab prophylaxis. *Res Pract Thromb Haemost.* 2023;7(8):102238. doi:10.1016/J.RPTH.2023.102238
- Levy-Mendelovich S, Atia N, Budnik I, et al. Factor VIII inhibitors in haemophilia A treated with emicizumab: longitudinal follow-up of outcomes. *Res Pract Thromb Haemost.* 2023;7(4). doi:10.1016/J.RPTH.2023.100278
- Lillicrap D, Fijnvandraat K, Young G, Mancuso ME. Patients with haemophilia A and inhibitors: prevention and evolving treatment paradigms. *Expert Rev Hematol.* 2020;13(4):313–321. doi:10.1080/17474086.2020.1739518
- Callaghan MU, Negrier C, Paz-Priel I, et al. Long-term outcomes with emicizumab prophylaxis for haemophilia A with or without FVIII inhibitors from the HAVEN 1–4 studies. *Blood.* 2021;137(16):2231. doi:10.1182/BLOOD.202009217
- Mahlangu JN. Bispecific Antibody Emicizumab for Haemophilia A: A Breakthrough for Patients with Inhibitors. *BioDrugs.* 2018;32(6):561–570. doi:10.1007/S40259-018-0315-0/METRICS
- Yoneyama K, Schmitt C, Portron A, et al. Clinical pharmacology of emicizumab for the treatment of haemophilia A. *Expert Rev Clin Pharmacol.* 2023;16(9):775–790. doi:10.1080/17512433.2023.2243213
- Franchini M, Mannucci PM. Past, present and future of haemophilia: a narrative review. *Orphanet J Rare Dis.* 2012;7(1):24. doi:10.1186/1750-1172-7-24
- Oudat R, Al-Maharmeh M, Al-Ghrayeb R, Ogeilat T, Mustafa MK. Prevalence of FVIII Inhibitors Among Children with Haemophilia A: Experience at the Jordanian Royal Medical Services. *Medical Archives.* 2020;74(3):187. doi:10.5455/MEDARH.2020.74.187-190
- Odnoczek E, Windygą J. Genetic testing in the diagnosis of haemophilia A. Published online 2014.
- Pediatrics after Graduation – Haemophilia in children. Accessed March 11, 2024. <https://podyplomie.pl/pediatrya/12198,hemofilia-u-dzieci>
- Berntorp E, Fischer K, Hart DP, et al. Haemophilia. *Nature Reviews Disease Primers* 2021;7(1):1–19. doi:10.1038/s41572-021-00278-x
- Peyvandi F, Garagiola I, Young G. The past and future of haemophilia: diagnosis, treatments, and its complications. *The Lancet.* 2016;388(10040):187–197. doi:10.1016/S0140-6736(15)01123-X
- Nugent D, O'Mahony B, Dolan G. Value of prophylaxis vs on-demand treatment: Application of a value framework in haemophilia. *Haemophilia.* 2018;24(5):755–765. doi:10.1111/HAE.13589
- Haemophilia in children yesterday and today | Health Service. Accessed March 11, 2024. <https://zdrowie.pap.pl/wywiady/rodzice/hemofilia-u-dzieci-wczoraj-i-dzis>
- Haemophilia in questions and answers. Guide for patients and their families. | Pediatric Oncology.pl. Accessed March 11, 2024. <https://onkologia-dziecieca.pl/zycie-z-choroba/hemofilia-w-pytaniach-i-odpowiedziach>
- Samelson-Jones BJ, George LA. Haemophilia care: the only constant is change. *Br J Haematol.* 2021;194(5):805–807. doi:10.1111/BJH.17661
- Letowska MK, Zawilska K, Klukowska A, et al. Immune Tolerance Induction (ITI) in Paediatric and Adult Patients with Haemophilia a (HA) and High-Titre (HT) Factor VIII (FVIII) Inhibitor – Real Life Data. *Blood.* 2019;134(Supplement\_1):4942. doi:10.1182/BLOOD-2019-122422
- Fassel H, McGuinn C. Haemophilia: factoring in new therapies. *Br J Haematol.* 2021;194(5):835–850. doi:10.1111/BJH.17580
- Le Quellec S. Clinical Evidence and Safety Profile of Emicizumab for the Management of Children with Haemophilia A. *Drug Des Devel Ther.* 2020;14:469. doi:10.2147/DDDT.S167731
- Windygą J, Chojnowski K, Klukowska A, et al. Emicizumab (Hemlibra®) in haemophilia A patients with inhibitors against factor VIII — guidelines of the Group for Haemostasis of the Polish Society of Haematology and Transfusion Medicine. *J Transf Med.* 2020;13(3):165–75. doi:10.5603/JTM.2020.0006
- Hemlibra. Roche. <https://www.roche.pl/rozwiwania/farmaceutyczne/hemlibra> (accessed: 2024.11.03).
- Hemlibra® (emicizumab) summary of product characteristics. EMA. [https://www.ema.europa.eu/en/documents/overview/hemlibra-epar-medicine-overview\\_pl.pdf](https://www.ema.europa.eu/en/documents/overview/hemlibra-epar-medicine-overview_pl.pdf) (accessed: 2024.11.03).
- Young G, Liesner R, Chang T, et al. A multicenter, open-label phase 3 study of emicizumab prophylaxis in children with haemophilia A with inhibitors. *Blood.* 2019;134(24):2127–2138. doi:10.1182/BLOOD.2019001869
- Pedro Alcedo Andrade by E, Mannuccio Mannucci P, Kessler CM, et al. Emicizumab: the haemophilia A game changer.

- Haematologica. Published online November 2, 2020:0–0. doi:10.3324/HAEMATOL.2022.282099
29. Muniz RL, Camelo RM, Araújo MS, et al. Efficacy/effectiveness and safety of emicizumab prophylaxis of people with haemophilia A: a systematic review and meta-analysis. *Expert Rev Hematol.* 2023;16(12):1087–1097. doi:10.1080/17474086.2023.2293096
30. Glonnegger H, Andresen F, Kapp F, Malvestiti S, Büchsel M, Zieger B. Emicizumab in children: bleeding episodes and outcome before and after transition to Emicizumab. *BMC Pediatr.* 2022;22(1). doi:10.1186/S12887-022-03546-1
31. Liu G, Huang K, Li G, et al. Real-world experience of emicizumab prophylaxis in young children with haemophilia A: retrospective data from China. *Front Pediatr.* 2022;10. doi:10.3389/FPED.2022.992267
32. Hassan E, Jonathan L, Jayashree M. Real-world experience on the tolerability and safety of emicizumab prophylaxis in paediatric patients with severe haemophilia A with and without FVIII inhibitors. *Haemophilia.* 2021;27(6):e698-e703. doi:10.1111/HAE.14432
33. Ahn JH, Jung N, Shim YJ, Kim HS. Emicizumab prophylaxis in a Korean child with severe haemophilia A and high titer inhibitor: a case report. *Blood Res.* 2021;56(1):44. doi:10.5045/BR.2021.2020184