



Retroperitoneal space tumour misinterpreted as a renal colic attack in a patient with urolithiasis, a suspected IgG4-related disease

Łukasz Marek Gawlik^{1,A,D}✉, Marta Głuchowska^{2,A,D}, Marcin Gregorczyk^{3,B,E}, Azita Rezaei^{4,A-B}, Piotr Jagodowski^{5,B-C}, Paweł Wróbel^{6,7,E-F}

¹ Ludwik Rydygier Specialist Hospital, Kraków, Poland

² University Hospital, Kraków, Poland

³ Healthcare Complex Urology Department, Końskie, Poland

⁴ Department of Clinical Radiology, University Clinical Hospital, Poznań, Poland

⁵ South Hospital, Warsaw, Poland

⁶ Department of Internal Medicine and Family Medicine, Collegium Medicum, Jan Kochanowski University, Kielce, Poland

⁷ Clinical Department of Nephrology with Dialysis Unit, Provincial Hospital, Kielce, Poland

A – Research concept and design, B – Collection and/or assembly of data, C – Data analysis and interpretation,

D – Writing the article, E – Critical revision of the article, F – Final approval of the article

Gawlik ŁM, Głuchowska M, Gregorczyk M, Rezaei A, Jagodowski P, Wróbel P. Retroperitoneal space tumour misinterpreted as a renal colic attack in a patient with urolithiasis, a suspected IgG4-related disease. *J Pre-Clin Clin Res*. doi: 10.26444/jpccr/186476

Abstract

Idiopathic retroperitoneal fibrosis, also known as Ormond's disease, can present as an IgG4-related disease involving the deposition of fibrous tissue in the retroperitoneal space. It is caused by chronic inflammation developing around the abdominal aorta and common iliac arteries. The case report describes a patient hospitalised for complaints of low back pain with positive Goldflam's sign and hydronephrosis, whose abdominal CT scan showed a tumour in the retroperitoneal space pressing on the ureter. Based on histopathological examination and laboratory tests, the patient was diagnosed with idiopathic retroperitoneal fibrosis, most likely related to IgG4. After diagnosis, the patient was initially treated in the urology department for urinary retention and then received treatment with glucocorticosteroids, according to the treatment guidelines for IgG4-dependent disease.

Keywords

hydronephrosis, Ormond's disease, idiopathic retroperitoneal fibrosis, IgG4-related disease

INTRODUCTION

Retroperitoneal fibrosis is a rare disease that leads to the deposition of connective tissue due to chronic inflammation developing in the retroperitoneal space which leads to pressure on the ureters or other abdominal organs [1]. Fibrous tissue initially accumulates around the abdominal aorta and common iliac arteries and then spreads to the retroperitoneal space. Classification is made into a primary- idiopathic form, known as Ormond's disease, and a secondary form, usually associated with the use of drugs, malignancies or infections [1, 2]. Ormond's disease occurs with a frequency of 1.4:100,000 [3], more often in men (2:1), and is most commonly manifested between 30–60 years of age [4].

The currently leading theory for the pathogenesis of this disease is the presence of chronic peri-aortic inflammation arising from atherosclerotic lesions of the abdominal aorta. Small injuries to the aorta result in exposure of LDL cholesterol from atherosclerotic plaques through the vessel wall and subsequent presentation of LDL surface antigens to T and B lymphocytes, initiating an inflammatory process located in the aortic media and adventitia. As the disease progresses, areas of chronic inflammation become covered by a fibrous layer leading to fibrosis of the retroperitoneal space [5].

Ormond's disease is now classified as an IgG4 antibody-related disease [4]. In the early stages, it may be asymptomatic or with general symptoms associated with chronic inflammation, such as fatigue or weight loss co-existing with dull abdominal pain. As the fibrosis progresses, the proliferating fibrous tissue begins to compress adjacent structures causing symptoms similar to renal colic – if the ureter is compressed [6]. Due to the narrowing of the ureter, the disease leads to the development of hydronephrosis and chronic kidney disease. The diagnosis of Ormond's disease is based on histopathological examination of tissue taken during a thick-needle biopsy or surgical removal of the lesions [4]. A crucial element of treatment is to achieve urinary outflow. For this purpose, JJ catheters are used or a nephrostomy is created [6]. Systemic corticosteroids (CSCs) are used in the first-line treatment, but in case of resistance, immunosuppressive drugs such as mycophenolate mofetil, cyclophosphamide, or tacrolimus are used [7]. In an IgG4 antibody-associated disease, due to the presence of CD20+ lymphocytes, anti-CD20 monoclonal antibodies – rituximab – are also used in therapy [8].

CASE REPORT

A 59-year-old patient was admitted to the Department of Internal Medicine due to severe lumbar and epigastric pain with positive Goldflam's sign on the right side, without

✉ Address for correspondence: Łukasz Marek Gawlik, Ludwik Rydygier Specialist Hospital, Złotej Jesieni 1, 31-826 Kraków, Poland
E-mail: lgawlik@onet.pl

Received: 04.02.2024; accepted: 25.03.2024; first published: 15.04.2024

haematuria and fever. The patient had been treated previously for hypertension, and also hospitalised several times for kidney stones which were treated conservatively. During his stay, the patient reported severe recurrent pain and vomiting without fever. Results of laboratory tests: serum creatinine – 1.58 mg/dL, GFR – 49.8 ml/min/1.73m². Imaging investigations included abdominal ultrasound, which showed dilatation of the pyelocalyceal system of the right kidney; chest and abdominal X-ray – no pathologies. Computed tomography (CT) of the abdomen and pelvis with contrast, showed hypodense areas in the right renal cortex with a dilated pyelocalyceal system. In addition, a heterogeneous and irregular lesion measuring 8 × 6.8 × 10 cm was seen around the inferior abdominal aorta, just before the division and around the common iliac arteries, as well as along the right external and internal iliac arteries. The lesion was compressing the right ureter.

The patient received analgesic and gastroprotective treatment and discharged from hospital with the recommendation to report urgently to his GP to obtain a diagnostic and oncology treatment card (DiLO), and extend the diagnosis for cancer. On further diagnosis, he was referred for a colonoscopy, which did not show lesions suspicious for neoplastic features. From the Surgical Outpatient Clinic, the patient was referred to the Department for General Surgery and Oncology, where a diagnostic laparoscopy of the retroperitoneal space was performed with the collection of specimens for histopathological examination. Microscopic diagnosis of the collected material revealed fragments of adipose tissue covered by fibrosis, with the presence of thick vitrified collagen fibres and scattered lymph nodules with reaction centres and clusters of plasma cells. B lymphocytes (CD20+) mainly within the lobules, T lymphocytes (CD3+) within the lobules and scattered. IgG+ plasmocytes were visible in the plasmocyte clusters (Fig. 1). However, it was not possible to assess IgG4 plasmocytes and the IgG:IgG4 ratio at the time of examination. The histological findings of the biopsy specimen suggested idiopathic retroperitoneal fibrosis.

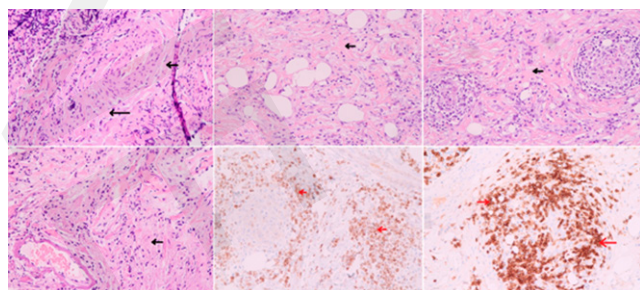


Figure 1. Histopathological examination of the tumour in the retroperitoneal space, near the aortic bifurcation. Black arrow – fibrous tissue around adipose cells and vessels with scattered inflammatory cells. Red arrows – immunohistochemically-stained IgG4 plasmocytes

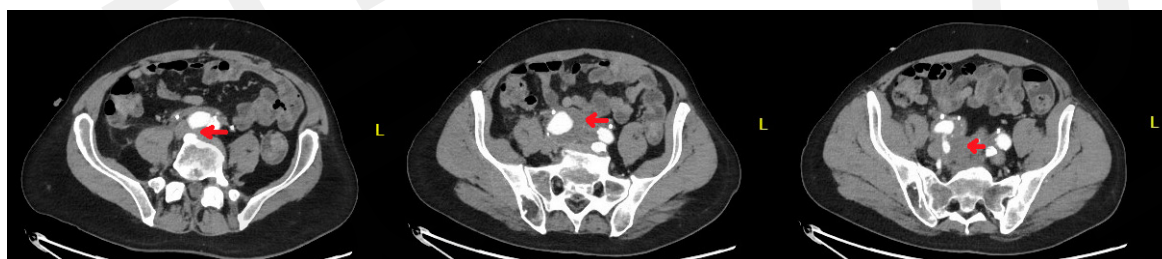

Figure 2. Image of the retroperitoneal space tumour in the described patient on abdominal and pelvic CT scan. The arterial phase. Red arrows – image of the tumor around the aortic bifurcation and iliac arteries

Table 1. Creatinine and GFR changes during hospitalisation [10]

Hospitalisation day	1	2	3	4	5
Serum creatinine level [mg/dL]	8.80	8.90	8.77	4.08	2.20
eGFR [ml/min/1.73m ²]	6.46	6.37	6.48	15.68	31.97

One month later, the patient was admitted to the Urology Department due to anuria. Laboratory tests showed significantly elevated creatinine, and abdominal ultrasound showed bilateral hydronephrosis. An emergency nephrostomy was created from a puncture on the right kidney. Once the patient was stabilised, ureterorenoscopy (URS) was performed with both ureters secured with DJ catheters. The treatment administered resulted in a decrease in serum creatinine (Tab. 1), an improvement in general condition and satisfactory diuresis.

After discharge from the urology ward, the patient was referred to the nephrology ward for further treatment of Ormond's disease, where he was qualified for treatment with intravenous pulses of methylprednisolone (3 × 1g), followed by the inclusion of oral prednisone (40mg, equivalent to 0.5 mg/kg body weight). The treatment resulted in improved renal function (decrease in serum creatinine from 2.41mg/dL to 1.38 mg/dL). The patient was tested for IgG4 levels from venous blood: 3.470 g/L (normal: 0.030–2.010 g/L) and further outpatient treatment was recommended. During the next hospitalisation, a follow-up CT scan of the abdomen and pelvis was performed (Fig. 2).

The treatment results were unsatisfactory and the decision was made to add mycophenolate mofetil 2 × 1000mg to the treatment.

DISCUSSION

Lower back pain associated with kidney disease is a common symptom reported by patients in primary care or hospital emergency departments. The most common causes of these complaints include nephrolithiasis and pyelonephritis [9]. Urolithiasis is a recurrent condition – 50% of those treated for nephrolithiasis will have a recurrence within 5 years [10]. The patient described above was admitted several times to a hospital emergency department with symptoms of renal colic, where renal stones were diagnosed and treated conservatively. These episodes recurred until a CT scan during one of them revealed the likely cause of these problems, which turned out to be an abdominal tumour pressing on the ureter, leading to urinary stasis and hydronephrosis – initially unilateral. In such a situation, the first thing to do is to rule out the presence of a malignant tumour – the patient was been referred for a chest X-ray – looking for a tumour in the lungs – and a

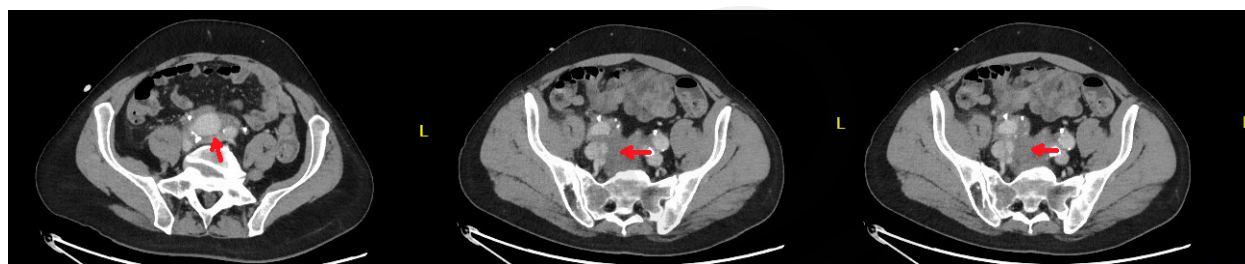

Figure 3. Image of the retroperitoneal space tumour on abdominal and pelvic CT scan. The venous phase. Red arrows – image of the tumour around the aortic bifurcation and iliac arteries.

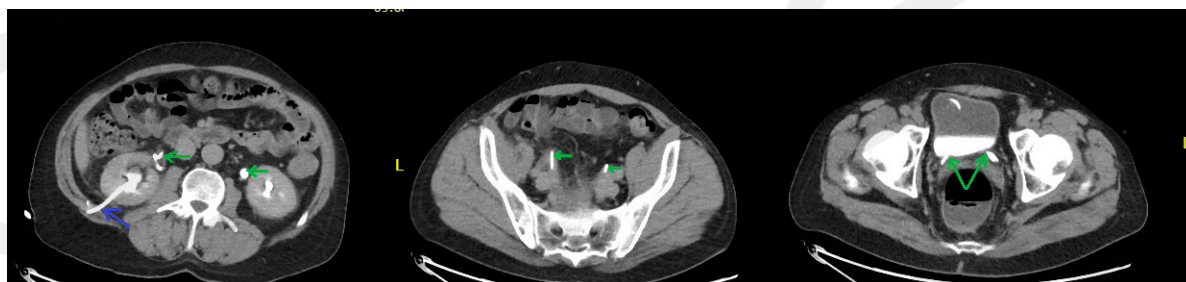

Figure 4. Image of the retroperitoneal space tumour on abdominal and pelvic CT scan – delayed phase. Blue arrow – a nephrostomy, green arrow – DJ catheters

Table 2. Inclusion criteria according to EULAR 2020 [11]

Histopathology	
– biopsy not providing relevant information	0
– dense lymphocytic infiltration	+4
– dense lymphocytic infiltration and obliterative phlebitis	+6
– dense lymphocytic infiltration and glandular fibrosis, with or without obliterative phlebitis	+13
Immunological staining (detailed below)	
	0–16
<i>Serum IgG4 concentration</i>	
– normal or indeterminate	0
– greater than normal but <2× upper limit of normal	+4
– 2× to 5× upper limit of normal	+6
– ≥5× upper limit of normal	+11
Bilateral involvement of lacrimal glands, parotid, sublingual and submandibular glands	
– no involvement	0
– involvement of 1 gland	+6
– involvement of ≥2 glands	+14
Chest	
– none present	0
– thickening of the peribronchial and septal vessels	+4
– paravertebral band-like soft tissue in the thorax	+10
Pancreas and biliary tract	
– none of the listed elements is present	0
– diffuse enlargement of the pancreas	+8
– pancreatic involvement (one of the above) and biliary involvement	+19
Kidney	
– unspecified or none of the listed elements present	0
– hypocomplementemia	+6
– thickening of the renal pelvis/soft tissue	+8
– bilateral areas of low density renal cortex	+10
Retroperitoneal space	
– unmarked or no listed element present	0
– diffuse thickening of the abdominal aortic wall	+4
– peripheral or anterolateral soft tissue around the infrarenal aorta or iliac arteries	+8

colonoscopy to rule out colorectal cancer. In both of these examinations there were no tumour that could metastasise to the retroperitoneal space. The next step was the collection of material for histopathological examination – in described patient, a diagnostic laparoscopy with section collection was performed. Only the histopathological examination revealed that the patient had the very rare Ormond's disease.

The European Alliance Of Associations For Rheumatology (EULAR) criteria can be used to diagnose IgG4-related disease. At the outset, it is necessary to assess the exclusion criteria, which are divided into clinical, serological, radiological, histopathological, and exclusion of specific diseases. In the described patient none of the exclusion criteria were present. The entry criteria to be assessed next is the clinical or radiological involvement of an organ typical of the disease. Due to the involvement of the aorta and retroperitoneal space, the entry criteria were positive in the patient. The inclusion criteria were then assessed (Tab. 2).

Due to the dense lymphocytic infiltration in the described patient, and the absence of glandular fibrosis and obliterative phlebitis, he was given 4 points from the histopathological examination. An additional 4 points due to an elevated serum IgG4 level, but no more than 2 upper limits of normal, and 8 points due to the presence of peripheral or anterolateral soft tissue around the infrarenal aorta or iliac arteries. The total score obtained by the patient was 16. In addition, the immunological staining scored (Tab. 3) was determined with

Table 3. Immuno-staining – scoring [11]

IgG4+:IgG [%]	IgG4 count	Points
0–40	0–9	0
≥41	0–9 or not specified	7
0–40 or not specified	≥10	7
41–70	≥10	14
≥71	10–50	14
≥71	≥51	16

reference to the IgG4+: IgG+ ratio which, unfortunately, could not be established during the histopathological examination.

The criteria for the classification of IgG4-dependent disease are met when the entry criteria are met, there are no exclusion criteria and the total score is ≥ 20 [11].

In the presented patient there were no exclusion criteria, the entry criteria were present, total score – 16. IgG4-dependent disease could not be definitively diagnosed, but was highly suspected, which in the clinical management resulted in the implementation of therapy. However, before the patient could receive the targeted treatment, he was admitted to the urology ward with acute renal dysfunction and anuria, where urine outflow had to be restored. After clinical improvement, the patient was qualified for treatment with steroid pulses which, according to guidelines, are the first line of treatment for the disease described. Due to the lack of satisfactory improvement after steroid treatment, mycophenolate mofetil was added to the treatment. Other diseases associated with IgG4 include autoimmune pancreatitis, Mikulicz disease or sclerosing cholangitis [12].

CONCLUSIONS

The above case demonstrates a rare cause of frequently reported symptoms. Ormond's disease may be asymptomatic for a long time and then manifest as episodes similar to renal colic which may delay a correct diagnosis. In recent studies, it may be one of the manifestations of IgG4-dependent diseases. The diagnosis is made on the basis of histopathological examination and EULAR criteria. Elevated IgG4 and their presence in tissue material lead to the diagnosis. During treatment, the urinary tract passage must be ensured as a first step followed by glucocorticosteroid (GCS) treatment.

Ormond disease usually responds well to GCS treatment. In steroid-resistant cases, the next-line therapy may be mycophenolate mofetil, tacrolimus, cyclophosphamide or monoclonal antibodies directed against B lymphocytes.

REFERENCES

- Gómez Rivas J, Quintana LM, Álvarez-Maestro M, Aguilera A, Martínez Piñero L, Sarikaya S. Retroperitoneal fibrosis: A literature review. *Fibrosis retroperitoneal. Revisión de la literatura. Arch Esp Urol.* 2020;73(1):60–67.
- Raglianti V, Rossi GM, Vaglio A. Idiopathic retroperitoneal fibrosis: an update for nephrologists. *Nephrol Dial Transplant.* 2021;36(10):1773–1781. doi:10.1093/ndt/gfaa083
- Prunoiu VM, Marincaş MA, Brătucu E, Ştefania N, Răvaş MM. Idiopathic Retroperitoneal Fibrosis. *Chirurgia (Bucur).* 2021;116(1):117–123. doi:10.21614/chirurgia.116.1.117
- Průcha M, Kolombo I, Štádl P. Ormond's Disease--IgG4-related Disease. *Prague Med Rep.* 2015;116(3):181–192. doi:10.14712/23362936.2015.57
- Vaglio A, Salvarani C, Buzio C. Retroperitoneal fibrosis. *Lancet.* 2006;367(9506):241–251. doi:10.1016/S0140-6736(06)68035-5
- Vaglio A, Maritati F. Idiopathic Retroperitoneal Fibrosis. *J Am Soc Nephrol.* 2016;27(7):1880–1889. doi:10.1681/ASN.2015101110
- Tanaka T, Masumori N. Current approach to diagnosis and management of retroperitoneal fibrosis. *Int J Urol.* 2020;27(5):387–394. doi:10.1111/iju.14218
- Angarola E, Valeo Chulvi M, Peuchot V, García Ravello H, Jauk F. Immunoglobulin G4-related retroperitoneal fibrosis. *Fibrosis retroperitoneal relacionada con IgG4. Medicina (B Aires).* 2022;82(1):91–98.
- Thia I, Saluja M. An update on management of renal colic. *Aust J Gen Pract.* 2021;50(7):445–449. doi:10.31128/AJGP-11-20-5751
- Corbo J, Wang J. Kidney and Ureteral Stones. *Emerg Med Clin North Am.* 2019;37(4):637–648. doi:10.1016/j.emc.2019.07.004
- Wallace ZS, Naden RP, Chari S, et al. The 2019 American College of Rheumatology/European League Against Rheumatism classification criteria for IgG4-related disease. *Ann Rheum Dis.* 2020;79(1):77–87. doi:10.1136/annrheumdis-2019-216561
- Al-Khalili OM, Erickson AR. IgG-4 Related Disease: An Introduction. *Mo Med.* 2018;115(3):253–256.