



# Gardner syndrome with desmoid tumors – case report

Anna Rycyk-Bojarzyńska<sup>1</sup>✉, Kinga Knop-Chodyła<sup>2</sup>, Beata Kasztelan-Szczerbińska<sup>1</sup>, Halina Cichoż-Lach<sup>1</sup>

<sup>1</sup> Department of Gastroenterology with Endoscopy Unit, Medical University, Lublin, Poland

<sup>2</sup> Independent Public Hospital Number 4, Lublin, Poland

A – Research concept and design, B – Collection and/or assembly of data, C – Data analysis and interpretation, D – Writing the article, E – Critical revision of the article, F – Final approval of the article

Rycyk-Bojarzyńska A, Knop-Chodyła K, Kasztelan-Szczerbińska B, Cichoż-Lach H. Gardner syndrome with desmoid tumors – case report. J Pre-Clin Clin Res. 2024; 18(1): 11–15. doi: 10.26444/jpccr/184176

## Abstract

**Introduction.** Gardner syndrome (GS) is characterized as a type of familial adenomatous polyposis (FAP), an autosomal dominant inherited disease which, if left untreated, with 100% risk leads to the development of colorectal cancer.

**Case Report.** The case is presented of a 40-year-old man who was diagnosed with Gardner syndrome at the age of 12. During his hospitalization, the patient underwent gastroscopy, colonoscopy, and computed tomography (CT) scans of head, neck and abdomen. The examination revealed the presence of extra-intestinal manifestations of GS: desmoid tumours, osteomas, and dental cavities. At present, the patient is scheduled for enteroscopy.

**Conclusions.** GS is a diagnosis of genetic testing, although clinicians should be aware of the fact that up to 30% of GS cases are detected as *de novo* mutations. The physical examination should always be performed with accuracy to avoid a too late diagnosis of FAP, including GS, which may result in death.

## Key words

colorectal cancer, desmoid tumor, Gardner syndrome, familial adenomatous polyposis (FAP), adenomatous polyposis syndrome.

## INTRODUCTION

The two most common inherited colorectal cancers are hereditary non-polyposis colorectal cancer (HNPCC) and familial adenomatous polyposis (FAP) [1]. Familial adenomatous polyposis is an inherited disease in an autosomal dominant manner [2]. It is essential to provide treatment as soon as possible, otherwise, according to the data, an individual with FAP will develop colorectal carcinoma (CRC) with the 100% risk around the age of 40 years [2,3]. Furthermore, prophylactic colectomy is indicated after diagnosis of FAP [2]. It is most often a familial disorder, although 20–30% of mutations arise *de novo* [2,3]. In the familial type, a germline mutation appears in the adenomatous polyposis coli (APC) gene located on chromosome 5q21–22 [2,4], which affects both men and women 1:1 [5]. Among FAP patients, Gardner syndrome (GS) is recognized in 10% of cases [6]. Although GS is characterized by the triad consisting of FAP, multiple osteomas, and soft tissue tumours, only 38% of individuals with GS show all components of the GS triad [6]. As polyposis remains asymptomatic, it is very difficult to set the proper diagnosis when no extraintestinal manifestation or family history are present [7]. In patients with APC mutation there is a high risk of CRC, gastric cancer, duodenal cancer, thyroid cancer, and malignant dental tumours [8]. Therefore, these patients require long-term follow-up [8].

## CASE REPORT

The case is presented of a 40-year-old male with Gardner syndrome who was admitted to the Department of Gastroenterology because of epigastric pain of a stabbing nature, exacerbated on the right side. The pain was not relieved by analgesics and diastolic medications. Then days before hospitalization he had been vomiting with dark clots.

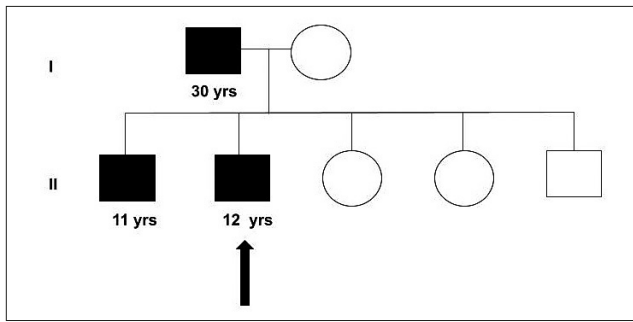
The diagnosis of Gardner syndrome had been made in the patient at the age of 12 years, based on clinical examination and genetic testing. The patient underwent multiple surgeries. At age 13, he underwent surgery of a soft tissue tumour in the thoracic region of the spine. Unfortunately, soon after the surgery, the lesion reappeared. Currently, it remains under observation and is not enlarging. At age 14, a partial bowel resection was performed, and in 2007 a definitive ileostomy was emerged carried out. Other surgeries on abdominal adhesions were performed, including a peristomal hernia operation in 2016, a partial resection of the small intestine in 2020. In 2021, he was hit in the abdomen by a cow and hospitalized. The patient has smoked a pack cigarettes a day for about 24 years.

The patient's family history was evident. His father was diagnosed at age 30 with FAP and died at age 50 from hepatocellular carcinoma. The patient's brother was diagnosed at age 11 and underwent a proctocolectomy; he died after surgery performed due to a bowel perforation. The patient's other siblings, two sisters (aged 47 and 45) and one brother (aged 32), are healthy and do not have any genetic mutation. Figure 1 presents the family pedigree.

Arrow points to the proband (the patient); Squares and circles denote males and females, respectively. Roman numerals indicate generations (I and II). Black squares

✉ Address for correspondence: Anna Rycyk, Department of Gastroenterology with Endoscopy Unit, Medical University, Lublin, Poland  
E-mail: aniryck@op.pl

Received: 10.01.2024; accepted: 16.02.2024; published online: 01.03.2024



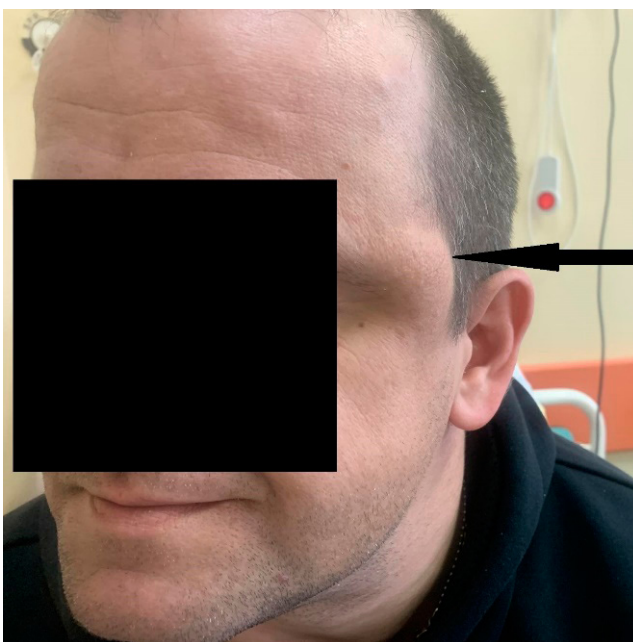**Figure 1.** Family pedigree chart

mean FAP mutation detected and the age of FAP diagnosis is written beneath the squares. White squares and circles indicate no FAP mutation.

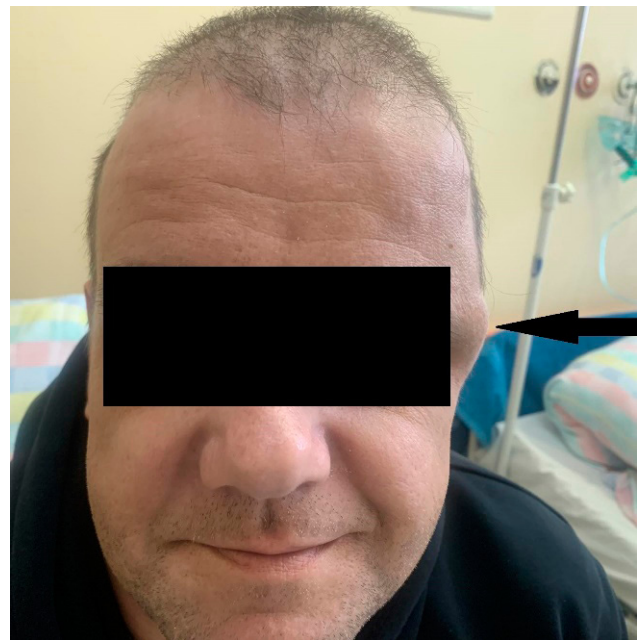Laboratory test results were within normal ranges: haemoglobin level – 16.2 g/dL, leukocytes –  $8.96 \times 10^9/L$ , thrombocytes –  $3.41 \times 10^4/\mu L$ , C-reactive protein (CRP) – 0.5 mg/L, iron – 1170  $\mu g/dL$ , lipase – 39 U/L, aspartate aminotransferase (AST) – 27 U/L, alanine aminotransferase (ALT) – 45 U/L, bilirubin – 0.71 mg/dL, alkaline phosphatase (ALP) – 91 U/L, gamma-glutamyl transferase (GGT) – 35 U/L, creatinine – 0.92 mg/dL, urea – 29 mg/dL, sodium – 142.0 mmol/L, potassium – 4.25 mmol/L, and thyroid-stimulating hormone (TSH) level – 1.326 mIU/L. Chest radiograph showed emphysema. The patient remains under pulmonology control.

Physical examination revealed features typical of extraintestinal manifestation of Gardner syndrome: presence of dental cavities, desmoid tumours, and osteomas. The patient is currently being prepared for tooth implant placements. A non-tender, hard, skin coloured, elevated and well-confined mass was also observed on the left frontal temporal area, above the left zygomatic arch, measuring  $1.5 \times 1$  cm, which was confirmed in computed tomography (CT). Fig. 2A and 2B).

A similar mass measuring  $1.6 \times 1.5$  cm. was observed on the right side of the paraspinal muscles. The whole length of the

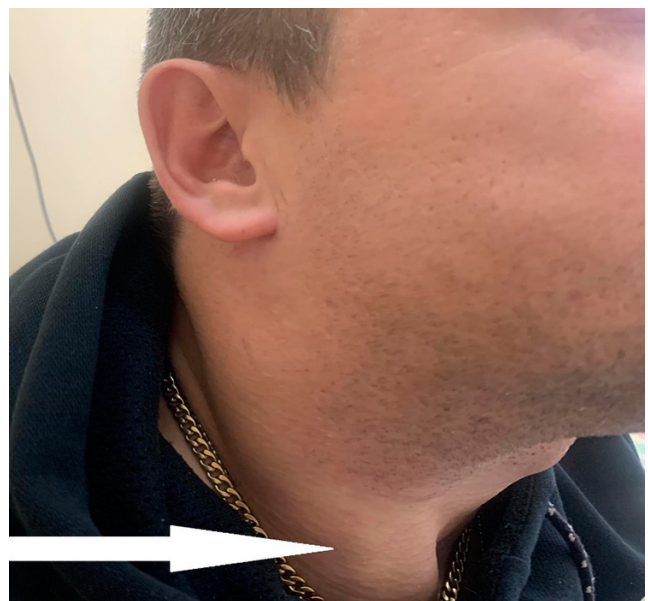

**Figure 2A.** Patient's face shows a mass on the left frontal temporal side (arrowed)



**Figure 2B.** Frontal view showing a mass on the left frontal temporal side (arrowed)

right sternocleidomastoid muscle is thickened to  $5.5 \times 3.2$  cm. A CT scan showed a  $4 \times 3.7$  cm mass surrounding the carotid arteries pressing on the right lobe of the thyroid gland, and displacing the larynx and throat to the left as shown in the photo (Figure 3).



**Figure 3.** Patient's neck showing a mass on the right side of the neck (arrowed)

In both the left and right ethmoidal cells, multiple small osteomas measuring 0.5–0.9 mm were detected. In the area of the left frontal-zygomatic suture there is a possible  $1.8 \times 1.7$  cm osteoma. Interestingly, in the abdominal CT scans a heterogeneous tissue tumour  $7.7 \times 5.7 \times 8.0$  cm of Th8-Th11 was revealed, described by the radiologist as suspicion of paraganglioma. In the authors' opinion, however, it is more likely that it is a desmoid tumour in the course of GS.

Upper gastroscopy revealed multiple tubular adenomas of the duodenum with features of metaplasia in biopsy specimens.

Colonoscopy performed through an ileostomy showed 30 cm of the small intestine with the proper mucous membrane. No biopsy was taken during colonoscopy. Performing enteroscopy is proposed in the nearest possible future.

## DISCUSSION

Gardner syndrome was first described in 1950s by Eldon J. Gardner et al. [9–12], the prevalence of which is 1 per one million people in the United States [10,13]. The incidence of FAP is estimated to be 1 in 8,000 patients [10]. One-fourth of GS patients have no family history [11]. Evaluation of APC and MYH mutation is recommended [5,11] as more than 200 mutations have been discovered which lead to GS [14]. The most commonly described feature in FAP syndrome is adenomatous polyposis [3]. However, there is also a spectrum of extraintestinal lesions, such as fundic gland polyps (FGPs), duodenal polyps and adenomas, fibromas, fibromatosis, nasal angiofibromas, hepatoblastomas, pancreatobiliary tumours, brain tumours, thyroid carcinomas, and congenital hypertrophy of retinal pigment epithelium (CHRPE) [3].

In patients with Gardner syndrome, initial gastrointestinal complaints may be non-specific [10] and mostly remain asymptomatic [10]. However, patients may also report isolated pruritus, inflammation, rupture, cramping, diarrhea, rectal bleeding, constipation, and vomiting [10]. Extra-intestinal manifestation may be present before colon manifestation [11]. Aletaha et al. described the case of a 24-year-old patient with multiple osteomas in the deep superonasal quadrant of the left orbit, and at the left and right mandibular angle, which led to endoscopy being performed and GS diagnosis [11].

**Extra-intestinal manifestation of GS.** Benign tumours that can arise from compact or cancellous bone are called osteomas [15], the majority of which are sporadic tumours [16]. However, some of them are associated with GS [16]. Osteomas appear 4–20 times more often in GS patients than in healthy population, and are most often localized in the mandible [8,11]. Therefore, they can also occur in the paranasal sinuses, the jaw, the skull, or even the long bones [11]. Only 0.1% – 1% appear in the temporal bone [17]. Treatment is not necessary as these lesions are usually not painful, and patients most often visit the doctor to improve aesthetics [8,17]. However, Angelo et al. described a patient with osteoma in the mandibular angle, condylar and coronoid regions bilaterally, who underwent osteoma removal surgery with bilateral customized alloplastic total temporomandibular joint replacement [18]. The surgery improved the patient's quality of life, and improved the maximum mouth opening from 8 mm to 34 mm [18]. Heller et al., on the other hand, presented the case of a patient who had an intracranial epidermoid osteoma localized in the fourth ventricle of the brain [19]. Given the lack of clinical symptoms, conservative treatment was used [19]. Patients with FAP are at high risk of medulloblastoma as well as adrenal adenocarcinoma [20]. Osteomas require differential diagnosis as they may simulate bone islands [21].

As many as 90% of patients with Gardner syndrome will show CHRPE and lesions [3]. In the general population, these occur in only 1.2–4.4% of individuals [3], and are recognized as at least one darkly pigmented lesion with a halo in the retina [3]. Interestingly, they have no malignant potential and

may be bilateral [3]. The presence of CHRPE may be one of the harbingers of FAP, which suggests that testing should be expanded to include genetic testing [3,22]. Ren et al. reported the case of a 20-year-old woman who presented with a 3-year history of proptosis of her right eye [23].

Dental abnormalities seen in 30% of patients with GS include: odontomas, supernumerary teeth, impacted and ectopic teeth and hypercementosis [9,24]. The bilateral occurrence of supernumerary teeth is very rare, and if they appear they may be associated with GS or cleidocranial dysostosis [25]. Seehra et al. described the case of a 12-year-old patient with GS diagnosis made after dental manifestation of this disease, which led to the proper recognition [9]. In some cases, diagnosis of GS is made after routine orthodontic assessment [9].

Among GS patients the most common soft tissue manifestations are epidermoid or sebaceous cysts and desmoid tumours [24]. According to the recent study, six or more of pilomatricomas is highly suggestive for various syndromes such as FAP syndrome, Turner syndrome, or Rubinstein-Taybi syndrome [26,27]. Desmoid tumours (fibromatoses) may be a manifestation of GS as in our patient. Although desmoid tumours are benign mesenchymal tumours with local aggressivity, they have no malignant potential [28]. These tumours in GS account for 15% of cases [29]. They can appear as sporadic tumours or be associated with FAP and GS [30,31]. Benign soft-tissue tumours associated with GS are Gardner-associated fibromas which may progress into desmoid fibromatosis or they co-occur with them [32,33]. Desmoid fibromas are formed by a myxoid stroma with elongated spindle cells [34]. They can develop anywhere in the human body, invade surrounding tissues, and they can grow rapidly [30,35]. They mostly occur in the abdominal wall, mesentery (about 8% of desmoid tumours), and extra-abdominal soft tissue as large tumours [36–38]. Extremely rare type of desmoid tumours are these localized in breasts and they account for less than 0.2% of all breast tumours [39]. Early diagnosis improves prognosis of GS [8]. Saito et al. described a case of Gardner syndrome with odontogenic sinusitis which is extremely rare [8]. Interestingly, Jin et al. reported a case of a 28-year-old pregnant woman whose pregnancy complicated with giant abdominal desmoid tumour in the course of FAP [40].

**FAP diagnosis.** The risk of polyps transformation into colon cancer in patients with FAP is 100% [11], and more than 50% of patients with FAP are found to have duodenal polyps and adenomas [3]. Duodenal polyps and malignant lesions are extremely rare, whereas benign lesions are parts of familial adenomatous polyposis, Peutz-Jeghers syndrome, and Gardner's syndrome [41]. When duodenal involvement occurs in GS, the majority will develop duodenal carcinoma [3]. Notably, FAP patients require endoscopic surveillance to avoid duodenal carcinoma [2]. After colorectal cancer, duodenal carcinoma is the second leading cause of death among FAP patients [3]. The risk of developing duodenal carcinoma is 100 – to 330-fold in FAP affected individuals [3]. Polyps of the stomach body and fundus appear in 30–88% FAP patients, and are associated with a low risk of progression to malignancy [3]. In contrast, Japanese FAP patients have 3–4 times increased gastric cancer rate [3].

Three categories of APC-associated fundic gland polyposis were distinguished:

- 1) classical FAP;
- 2) attenuated familial adenomatous polyposis (AFAP);
- 3) gastric adenocarcinoma and proximal polyposis of the stomach (GAPPS) [42].

According to American recommendations, in these patients screening for colorectal cancer should be performed by annual colonoscopy or flexible sigmoidoscopy [5]. Patients with FAP and AFAP should be evaluated by thyroid ultrasound every year [5]. Depending on the Spigelman stage of duodenal polyposis, upper endoscopy should be performed at age 25–30 years, and subsequently continued every 6 months to 4 years (Tab. 1) [5].

**Table 1.** Spigelman stage of duodenal polyposis [5]

Spigelman stage	When to perform upper endoscopy
0	in 4 years
I	in 2–3 years
II	in 1–3 years
III	in 6–12 months
IV	surgical evaluation recommended

After colectomy FAP and AFAP, patients should be monitored with endoscopy of the rectum or ileal pouch, and an ileostomy performed every 2 years [5]. The 5-year survival rates of GS, if detected early, are 100% in patients who have had a proctocolectomy [43].

**Table 2.** Indications for immediate colectomy in patients with FAP and AFAP

Absolute indications	Relative indications
– documented colorectal cancer	– presence of multiple adenomas >6 mm
– suspected colorectal cancer	– significant increase in adenoma number
– significant symptoms	– inability to adequately survey the colon because of multiple diminutive polyps

According to the Swedish data, 67% of 216 patients had CRC at diagnosis, and the mortality rate was 44% [44]. Female patients were diagnosed with CRC earlier than male patients [44]. This may indicate that the course of FAP is influenced by gender [44]. Another study performed in Finland revealed that 76 of 116 patients (65.5%) had CRC at the time of diagnosis [45], and the Danish Polyposis Register demonstrated that CRC was diagnosed in 170/252 patients (67%) [46]. Screening by colonoscopy remains crucial for patients with suspicion of AFAP, FAP and in healthy patients with no CRC family history at the age of 45 [47,48]. A study based on the Manchester Polyposis Registry revealed that survival rates increased from 57.8 years to 70.4 years by screening, and that screening reduced the incidence of CRC from 43.5%–3.8% [49]. Although it is generally believed that in FAP patients the diagnosis of CRC is mostly made at the age of 40–50, Gu et al. described the case of a 22-year-old patient diagnosed with FAP and CRC at the same time [50]. Biopsy revealed adenocarcinoma and positron emission, and tomography-computed tomography? positon emission tomography (PET-CT) revealed metastases into the liver [50]. The patient's family history showed that 4 of the 5 brothers of her grandfather died of liver, lung, and gastric cancer [50]. According to American guidelines, depending on family history, there are groups of patients in

whom the presence of colorectal adenomas and extraintestinal manifestations, who require assessment for adenomatous polyposis syndromes (Tab. 3).

**Table 3.** Indications to perform assessment for the adenomatous polyposis syndromes

Patients who should undergo assessment for adenomatous polyposis syndromes [5]
1. with >10 cumulative colorectal adenomas,
2. with a family history of one of the adenomatous polyposis syndromes,
3. with a history of adenomas and FAP-type extracolonic manifestations, such as duodenal/ampullary adenomas, desmoid tumours, papillary thyroid cancer, CHRPE, epidermal cysts, and osteomas.

## CONCLUSION

The patient in the presented case is now waiting for enteroscopy. The FAP diagnosis was not the end of his management route because regular surveillance is extremely important for the further life of patients affected with polyposis syndrome. As mentioned previously, the high risk of malignancy, including 100% risk of CRC development, necessitates fast evaluation and determination of the proper diagnosis at the earliest possible time. Family history is the aspect of clinical examination which can never be omitted.

## Declarations

### Availability of data and materials

All data generated or analyzed during this study are available from the corresponding author on reasonable request.

### Consent for publication

The patient signed an informed consent form and agreed to the presentation of his medical history.

### Competing interests

The authors declare that they have no competing interests.

### Funding

No funding was received.

## REFERENCES

1. Khattab A, Monga DK. Turcot Syndrome. In: StatPearls [Internet]. Treasure Island (FL): StatPearls Publishing; 2023 [cited 2024 Jan 3]. Available from: <http://www.ncbi.nlm.nih.gov/books/NBK534782/>
2. Aelvoet AS, Buttitta F, Ricciardiello L, Dekker E. Management of familial adenomatous polyposis and MUTYH-associated polyposis; new insights. *Best Practice & Research Clinical Gastroenterology*. 2022 Jun 1;58–59:101793.
3. Dinarvand P, Davaro EP, Doan JV, Ising ME, Evans NR, Phillips NJ, et al. Familial Adenomatous Polyposis Syndrome: An Update and Review of Extraintestinal Manifestations. *Archives of Pathology & Laboratory Medicine*. 2019 May 29;143(11):1382–98.
4. Giang H, Nguyen VT, Nguyen SD, Nguyen HP, Vo BT, Nguyen TM, et al. Detection of a heterozygous germline APC mutation in a three-generation family with familial adenomatous polyposis using targeted massive parallel sequencing in Vietnam. *BMC Med Genet*. 2018 Oct 19;19:188.
5. Syngal S, Brand RE, Church JM, Giardiello FM, Hampel HL, Burt RW. ACG Clinical Guideline: Genetic Testing and Management of Hereditary Gastrointestinal Cancer Syndromes. *Am J Gastroenterol*. 2015 Feb;110(2):223–63.

6. D'Agostino S, Dell'Olio F, Tempesta A, Cervinaro F, D'Amati A, Dolci M, et al. Osteoma of the Jaw as First Clinical Sign of Gardner's Syndrome: The Experience of Two Italian Centers and Review. *J Clin Med*. 2023 Feb 14;12(4):1496.
7. Kozan R, Taşdöven İ, Seven TE, Aydemir S, Doğan Gün B, Cömert M. Gardner's syndrome: Simultaneous diagnosis and treatment in monozygotic twins. *Turk J Surg*. 2022 Dec 20;38(4):413–7.
8. Saito K, Sekine M, Goto F, Yamamoto H, Kaneda S, Sakai A, et al. Gardner syndrome with odontogenic sinusitis: A case report. *Clin Case Rep*. 2021 Jun 23;9(6):e04256.
9. Seehra J, Patel S, Bryant C. Gardner's Syndrome Revisited: A Clinical Case and Overview of the Literature. *J Orthod*. 2016 Mar 1;43(1):59–64.
10. Charifa A, Jamil RT, Zhang X. Gardner Syndrome. In: StatPearls [Internet]. Treasure Island (FL): StatPearls Publishing; 2023 [cited 2024 Jan 2]. Available from: <http://www.ncbi.nlm.nih.gov/books/NBK482342/>
11. Aletaha M, Fateh-Moghadam H. Gardner Syndrome. *J Ophthalmic Vis Res*. 2012 Jul;7(3):257–60.
12. Lucamba AJ, Grillo R, Jodas CRP, Teixeira RG. Multiple Gardner Syndrome Osteomas Mimicking Temporomandibular Ankylosis: Case Report. *J Maxillofac Oral Surg*. 2023 Feb 25;1–4.
13. Fotiadis C, Tsekouras D, Antonakis P, Sfiniadakis J, Genetzakis M, Zografos G. Gardner's syndrome: A case report and review of the literature. *World J Gastroenterol*. 2005 Sep 14;11(34):5408–11.
14. Thomaidis V, Seretis K, Tsoucalas G, Razos K, Vasilopoulos A, Efenti GM, et al. A Case of Early FAP Diagnosis with Extraintestinal Manifestations on the Face. *Acta Medica Academica*. 2019 Oct 24;48(2):217–24.
15. Putro YAP, Magetsari R, Taroeno-Hariadi KW, Dwianingsih EK, Pribadi AW, Sukotjo KK. Classic and rare manifestations of multiple osteoma: A case report. *Int J Surg Case Rep*. 2023 Sep;110:108713.
16. Baumhoer D, Berthold R, Isfort I, Heinst L, Ameline B, Grünewald I, et al. Recurrent CTNNB1 mutations in craniofacial osteomas. *Mod Pathol*. 2022 Apr;35(4):489–94.
17. Tan EWK, Barco JB, Rehman MU, Tan CC. Retromastoid osteoma—a rare case report. *J Surg Case Rep*. 2020 Jan 13;2020(1):rjz381.
18. Angelo DF, Nunes M, Monje F, Mota B, Salvado F. A role for total alloplastic temporomandibular joint replacement in Gardner syndrome. *Int J Oral Maxillofac Surg*. 2023 Nov 18;S0901-5027(23)00293-X.
19. Heller GD. Conservative management of a fourth ventricular epidermoid in a patient with Gardner syndrome. *Ther Adv Rare Dis*. 2020 Oct 29;1:2633004020969702.
20. Kiessling P, Dowling E, Huang Y, Ho ML, Balakrishnan K, Weigel BJ, et al. Identification of aggressive Gardner syndrome phenotype associated with a de novo APC variant, c.4666dup. *Cold Spring Harb Mol Case Stud*. 2019 Apr;5(2):a003640.
21. Bedard T, Mohammed M, Serinelli S, Damron TA. Atypical Enostoses—Series of Ten Cases and Literature Review. *Medicina (Kaunas)*. 2020 Oct 13;56(10):534.
22. Lyons LA, Lewis RA, Strong LC, Zuckerbrod S, Ferrell RE. A genetic study of Gardner syndrome and congenital hypertrophy of the retinal pigment epithelium. *Am J Hum Genet*. 1988 Feb;42(2):290–6.
23. Ren M, Li R, Liu L. Atypical Gardner's Syndrome with Proptosis as the Primary Symptom. *Ophthalmology [Internet]*. 2023 Jun 28 [cited 2024 Jan 3];0(0). Available from: [https://www.aaojournal.org/article/S0161-6420\(23\)00419-0/fulltext](https://www.aaojournal.org/article/S0161-6420(23)00419-0/fulltext)
24. Blackwell MC, Thakkar B, Flores A, Zhang W. Extracolonic manifestations of Gardner syndrome: A case report. *Imaging Sci Dent*. 2023 Jun;53(2):169–74.
25. Jain A, Taneja S. Bilateral presentation of different supernumerary teeth in nonsyndromic patients: case reports. *Gen Dent*. 2020;68(2):39–42.
26. Ciriacks K, Knabel D, Waite MB. Syndromes associated with multiple pilomatricomas: When should clinicians be concerned? *Pediatric Dermatology*. 2020;37(1):9–17.
27. Smith C, Hamilton D, Waterston S. Rare case of multiple and perforating pilomatricomas in a young girl with lymphovascular malformation reveals a potential new disease association. *BMJ Case Rep*. 2022 May 25;15(5):e248076.
28. Tayeb C, Parc Y, Andre T, Lopez-Trabada Ataz D. Polypose adénomateuse familiale, tumeurs desmoïdes et syndrome de Gardner. *Bulletin du Cancer*. 2020 Mar 1;107(3):352–8.
29. Yu F, Cai W, Jiang B, Xu L, Liu S, Zhao S. A novel mutation of adenomatous polyposis coli (APC) gene results in the formation of supernumerary teeth. *J Cell Mol Med*. 2018 Jan;22(1):152–62.
30. Litchinko A, Brassat C, Tihy M, Amram ML, Ris F. Large Desmoid Tumour of the Pancreas: A Report of a Rare Case and Review of the Literature. *Am J Case Rep*. 2022 Nov 15;23:e937324-1-e937324-10.
31. Shayesteh S, Salimian KJ, Fouladi DF, Blanco A, Chu LC, Fishman EK. Pancreatic cystic desmoid tumour following metastatic colon cancer surgery: A case report. *Radiol Case Rep*. 2020 Nov;15(11):2063–6.
32. Bakker A, Slack JC, Caragea M, Kurek KC, Bründler MA. Adipocytic CTNNB1-mutated Intramuscular Gardner Fibroma Progressing to Desmoid Fibromatosis. *Pediatr Dev Pathol*. 2021;24(1):62–7.
33. Signoroni S, Piozzi GN, Collini P, Cocco IMF, Biasoni D, Chiaravalli S, et al. Gardner-associated fibroma of the neck: role of a multidisciplinary evaluation for familial adenomatous polyposis diagnosis. *Tumori*. 2021 Dec;107(6):NP73–6.
34. Ramírez Stieben LA, Pozzi D. Papillary thyroid carcinoma with desmoid fibromatosis: a case report and review of literature. *Rev Fac Cien Med Univ Nac Cordoba*. 2023 Sep 29;80(3):289–300.
35. Rangunwala J, Sitta J, Prakash V, Vyas K, Roda M. Complex Case of Aggressive Intra-abdominal Desmoid-type Fibromatosis Status Post Cholecystectomy. *Cureus*. 2020 Mar 6;12(3):e7193.
36. Aghighi M, Cloutier JM, Hoover WD, Roy K, Lo AA, Brown RA. Cutaneous desmoid-type fibromatosis: A rare case with molecular profiling. *J Cutan Pathol*. 2021 Sep;48(9):1185–8.
37. Abu-Jeyyab M, Al-Asbahi H, Al-Jafari M, Al-Tarawneh BK, Nashwan AJ. Aggressive Fibromatosis of the Left Mesocolon Mimicking a Gastrointestinal Stromal Tumour: A Case Report. *Case Rep Oncol*. 2023;16(1):1148–55.
38. Sioda NA, Wakim AA, Wong T, Patel S, Coan K, Row D. A Large Sporadic Intra-abdominal Desmoid-Type Fibromatosis in a Young Male: A Case Report. *Front Surg*. 2020;7:60.
39. Maimone S, Lewis JT. Gardner Syndrome With Breast Desmoid Tumours. *Mayo Clinic Proceedings*. 2022 Oct 1;97(10):1894–6.
40. Jin L, Tan Y, Su Z, Huang S, Pokhrel S, Shi H, et al. Gardner syndrome with giant abdominal desmoid tumour during pregnancy: a case report. *BMC Surg*. 2020 Nov 12;20:282.
41. Malik MN, Shah Z, Rafae A, Mahmood T, Fazeel HM. Small Intestinal Tumours: A Rare Case of Tubulovillous Adenoma in Duodenum. *Cureus*. 11(5):e4671.
42. Eizuka M, Toya Y, Kosaka T, Oizumi T, Morishita T, Kasugai S, et al. Attenuated Familial Adenomatous Polyposis. *Intern Med*. 2023 Sep 15;62(18):2651–4.
43. Ali A, Ahmad A, Taj S, Quadeer SA, Ahmed SE. Familial Adenomatous Polyposis (FAP) Presenting as Iron Deficiency Anemia in a 33-Year-Old Female: A Case Report. *Cureus*. 14(4):e24603.
44. Björk J, Akerbrant H, Iselius L, Alm T, Hultcrantz R. Epidemiology of familial adenomatous polyposis in Sweden: changes over time and differences in phenotype between males and females. *Scand J Gastroenterol*. 1999 Dec;34(12):1230–5.
45. Järvinen HJ. Epidemiology of familial adenomatous polyposis in Finland: impact of family screening on the colorectal cancer rate and survival. *Gut*. 1992 Mar;33(3):357–60.
46. Bülow S. Results of national registration of familial adenomatous polyposis. *Gut*. 2003 May;52(5):742–6.
47. Paramythiotis D, Kyriakidis F, Karlafti E, Koletsas T, Tsakona A, Papalexis P, et al. A Rare Case of Multiple Gastrointestinal Stromal Tumours Coexisting with a Rectal Adenocarcinoma in a Patient with Attenuated Familial Adenomatous Polyposis Syndrome and a Mini Review of the Literature. *Medicina (Kaunas)*. 2022 Aug 18;58(8):1116.
48. Shaukat A, Levin TR. Current and future colorectal cancer screening strategies. *Nat Rev Gastroenterol Hepatol*. 2022 Aug;19(8):521–31.
49. Mallinson EKL, Newton KF, Bowen J, Lalloo F, Clancy T, Hill J, et al. The impact of screening and genetic registration on mortality and colorectal cancer incidence in familial adenomatous polyposis. *Gut*. 2010 Oct;59(10):1378–82.
50. Gu X, Li X, Xu J, Yang J, Li H, Wu Q, et al. Accumulated genetic mutations leading to accelerated initiation and progression of colorectal cancer in a patient with Gardner syndrome. *Medicine (Baltimore)*. 2021 Apr 2;100(13):e25247.