



# Spindle cell carcinoma in the maxilla: an uncommon aggressive malignancy – case report

Lena Sobiech<sup>1,A-D</sup>, Magdalena Zawadka<sup>2,D-E</sup>, Aleksandra Dolina<sup>2,E-F</sup>

<sup>1</sup> Dentistry Student, Medical University, Gdańsk, Poland

<sup>2</sup> Department of Sports Medicine, Faculty of Health Science, Medical University, Lublin, Poland

A – Research concept and design, B – Collection and/or assembly of data, C – Data analysis and interpretation, D – Writing the article, E – Critical revision of the article, F – Final approval of the article

Sobiech L, Zawadka M, Dolina A. Spindle cell carcinoma in the maxilla: an uncommon aggressive malignancy – case report. J Pre-Clin Clin Res. doi: 10.26444/jpccr/174061

## Abstract

**Introduction.** Squamous cell carcinoma and sarcoma are malignant tumours, which can appear in different parts of the body. Spindle cell carcinoma (SCC), in terms of histopathology, is a type of cancer that has both spindle cell carcinoma and sarcoma features.

**Case Report.** The case is presented of a 45-year-old man with diagnosed spindle cell carcinoma which occurred on the right side of the patient's maxilla. This type of tumour is really rare for the area of the head and neck. The patient has been diagnosed using dental volumetric tomography, Cone Beam Computed Tomography (CBCT) and bone biopsy. The patient has undergone comprehensive treatment, which includes radical resection of the tumour area as well as chemotherapy and radiotherapy. Regular control visits and diagnosis after completed treatment are extremely important for the final outcome of treatment.

## Key words

oral cavity, plastic surgery, maxilla, Spindle cell carcinoma.

## INTRODUCTION

Spindle cell carcinoma (SCC) rates rare cancer and accounts for only 1–2% of all head and neck cancers [1–3]. It is mostly called: carcinosarcoma, pseudo sarcoma or so-called carcinosarcoma [4]. World Health Organization determine this cancer as spindle cell carcinoma [2].

It is considered a faintly diverse squamous cell carcinoma with elongated cells resembling sarcoma [5, 6]. Histologically, this tumour consists of malignant epithelial components and malignant mesenchyme [7, 8]. It is really rare for SCC to appear in the area of the head and neck, but when it does, in most cases it involves the larynx [9]. In the literature, there are also reports of cases found in the nasal cavity, oesophagus, trachea, jaw and skin [7]. This type of cancer appearing in the maxilla is far less common in literature [8, 9]. Scientific reports from 2013 Surveillance, Epidemiology and Results (SEER) quote a total of 250 cases of tumours in the area of the head and neck; nevertheless, none of the described cases present information about cancer in the maxillofacial bone tissue [11]. Until 2020, only 2 cases of primary bone spindle cell carcinoma of the maxillofacial area have been reported [12, 13].

The aim of this study is to present the case of a patient with diagnosed spindle cell carcinoma located in the maxilla.

## CASE REPORT

A 45-year-old man reported to a doctor with the symptom of an unstable tooth – the second incisor of the maxilla. The symptoms lasted for a month but the man did not feel any pain. In the dental examination, the vitality of the pulp of teeth 12 and 13 (according to Viöhl's system), which are correspondingly second incisor and canine of the patient's right side of the maxilla, was assessed using cotton wool soaked in ethyl chloride. The examination showed that the pulp was vital.

Because of the lasting Covid-19 pandemic, the patient underwent diagnostic imaging after a delay of 3 months. Dental 3D tomography (CBCT) of the patient's upper alveolar arch in the region of teeth 12–13 was performed. An extensive blurred area of osteolysis was found of the alveolar process of the right maxillary bone, with blurred outlines of the external bones of about 14 x 21 x 23 mm (ApxLPxCC) (Fig. 1). For in-depth diagnostics, bone material was taken under local anesthesia. Bone biopsy showed inflammation, squamous cell carcinoma and sarcoma cells.

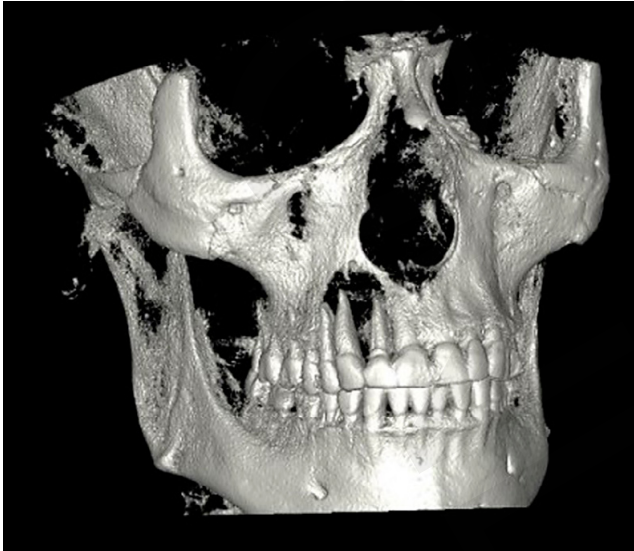
Within 6 months of the symptoms, the patient was qualified for surgical treatment at the Maria Skłodowska-Curie National Research Institute of Oncology in Gliwice, Silesia, western Poland.

Pre-operative preparation was carried out in accordance with the standards of the department, which included blood count and an anaesthetic consultation.

The procedure consisted of resection of the lesion and simultaneous reconstruction of the maxilla. Resection included maxillary bone from teeth 16–21 included with a margin of 15 mm (Fig. 2, Fig. 3). The lymph node on the right side of the neck and orbicularis oris were removed.

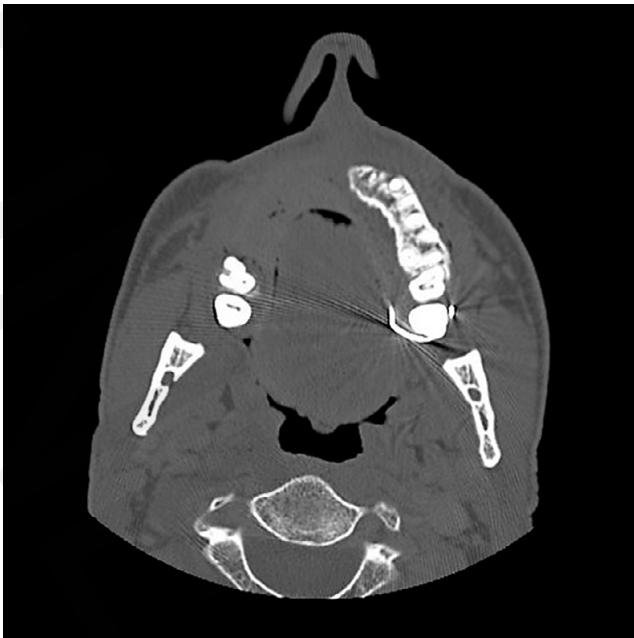
✉ Address for correspondence: Magdalena Zawadka, Department of Sports Medicine, Faculty of Health Science, Medical University of Lublin  
E-mail: magdalena.zawadka@umlub.pl

Received: 14.08.2023; accepted: 12.10.2023; first published: 18.10.2023



**Figure 1.** Cone-Beam Computer Tomography (CBCT) performed before surgery

The muscle was also involved with neoplastic lesions. The resulting post-resection bone loss was treated with a free left sagittal flap using a 3D printer template. In the post-operative imaging, a sinooral fistula was visible.

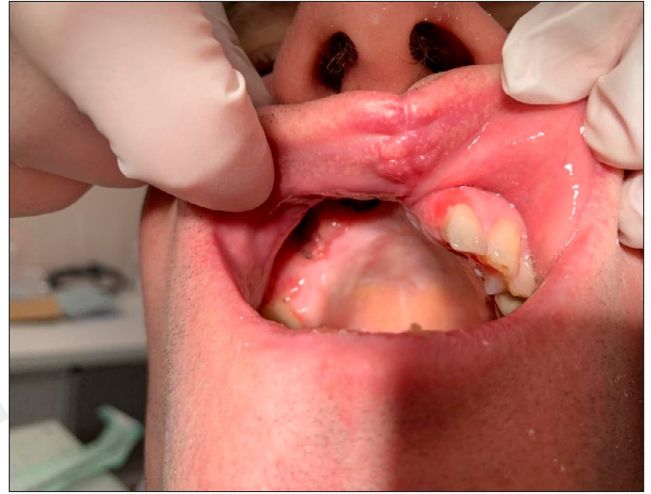

**Figure 2.** CT after resection of the tumour in the area of the right maxillary bone

In connection with antithrombotic prophylaxis after surgery, the patient was prescribed low-molecular-weight heparin Clexane 60 mg twice a day.

Unfortunately, after the surgery, disorders of the blood supply to the transplanted lobe appeared, and a clot was found in the area of the facial artery. Because of graft necrosis, excision of the tissue used for reconstruction was performed the day after. These post-operative complications were life-threatening for the patient.

Within one month, 2 more reconstructive operations were performed, taking a bone graft from the ilium and a muscle graft from the quadriceps femoris. However, the reconstructions culminated in progressive bone necrosis due



**Figure 3.** Post-operative photo

to venous thrombosis. During the procedure, a temporary tracheostomy was performed.

Pharmacological treatment included analgesic treatment, postoperative antibiotic therapy and antithrombotic treatment in the form of a therapeutic dose of low molecular weight heparin Clexane 60 mg twice daily. During hospitalization, haematological consultation for antiphospholipid syndrome and congenital thrombophilia due to venous thrombosis and triple lobar necrosis was ordered. After 2 months, the patient was discharged from hospital in good general condition, with recommendations to continue anticoagulant treatment until the next haematological visit in an outpatient setting.

The patient additionally had a nasal feeding tube inserted for 4 months, with no oral intake of food permitted. After one month, due to difficulty of feeding the patient, the nasal feeding tube was substituted for percutaneous endoscopic gastrostomy (PEG). The patient was also referred for tests to a haematology clinic with suspected thrombophilia. This was excluded by diagnostics.

Histopathological post-operative examination revealed infiltrates in the area of the upper margin and on the mucosa from the side of the oral vestibule. Computed tomography (CT) of the head, neck and lymph nodes did not show any malignant infiltration.

Two months after surgery, combined chemotherapy and radiotherapy were included in the treatment. The patient received 2 cycles of chemotherapy at the same time, based on Cisplatinum 100mg/m<sup>2</sup>, and radiotherapy in the area of the removed tumour. Radiotherapy consisted of 35 daily exposures. After completing the chemotherapy and radiotherapy, the patient could return home. PEG feeding was maintained until the post-operative wound had healed. One year after treatment, the patient received an obstructive prosthesis for the missing teeth on the right side of the palate (Fig. 4,5).

At the present time, the patient has been under the constant supervision of an oncologist for 2.5 years after treatment. MRI and CT of the head and chest showed no recurrence or metastases. The patient feels well.

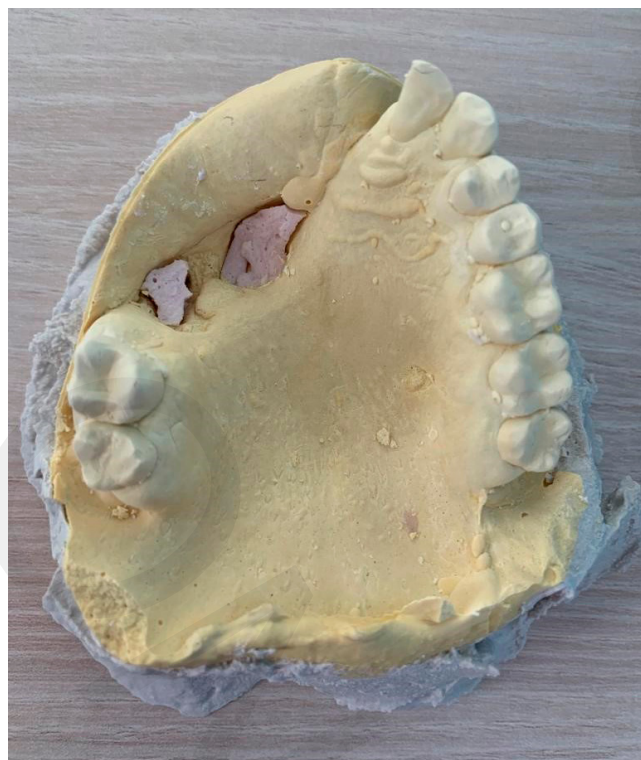

Figure 4. Impression. Gypsum model

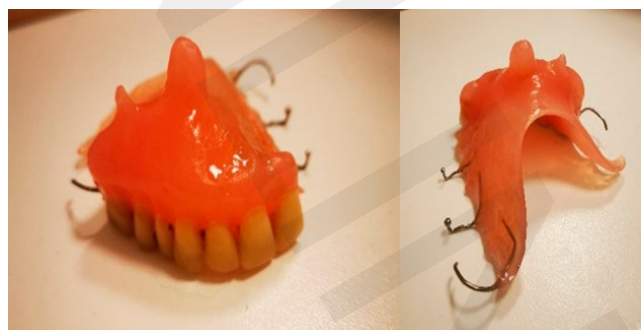


Figure 5. Obstructive prosthesis

## DISCUSSION

According to the WHO, the current classification of head and neck cancers defines the presented type of cancer as Spindle cell carcinoma. This name suggests that the epithelial cell is the starting point of both components of the tumour [2, 12], and microscopic imaging of this type of tumour shows the presence of epithelial and mesenchymal structures. In literature, it has been proven that epithelial components correspond to squamous cell carcinoma. Adenocarcinoma occurs sporadically. The spindle cells of the mesenchymal component may not have specific differentiation or may form bone, cartilage, smooth or striated muscle. The spindle cell component may both infiltrate deeply as well as metastasize [3].

Tumours of a complex microscopic structure occurring in different parts of the body, for example, breast, lung, uterus or head and neck, are often called carcinosarcoma or pseudosarcoma. They are rarely painful and usually produce distant metastases, mostly to the lungs [14]. The most common primary site, as in the presented patient, is

the oral cavity, followed by the larynx, oropharynx, maxilla, and metastatic nodes [15, 16].

Authors of scientific literature concerning spindle cell carcinoma believe that the optimal treatment includes complete resection with as large a margin as possible, and that the therapeutic approach should be the same as for squamous cell carcinoma [6, 17].

According to Thompson et al. there was no significant difference in life longevity between patients treated with radiotherapy to those treated by bone resection [18, 19]. Radiotherapy should be an alternative method for inoperable cases, and can also be beneficial in cases where surgical margins are positive or there are metastases to lymph nodes when the disease is detected [20].

When preparing the presented patient for surgery, the oral and maxillofacial surgeons used a 3D jaw template. The use of a 3D template in reconstructive surgery allows avoidance of intra-operative errors, including fistula formation or nerve damage. The 3D template reproduces anatomical structures, thanks to which the surgeon does not make mistakes during resection [21]. This procedure allows for shortening the operation time and optimal bone resection.

It should also be mentioned that the presented patient did not belong to the risk group for cancer which influence the development of this cancer, including people with addictions: smokers, alcoholics, and those exposed to ionizing radiation [4]. On the contrary, he is young and leads a healthy lifestyle, does not smoke or abuse alcohol. The period in which the symptoms of the disease appeared occurred during the very difficult time of the COVID-19 pandemic. Unfortunately, the patient had difficulties with quick access to health care, especially a dentist. This extended the waiting period for tests and diagnosis. In the course of this type of cancer, early and correct histopathological diagnosis is very important. Due to its aggressiveness, spindle cell carcinoma has a tendency to recur and early metastasis [3].

## CONCLUSION

A patient after a histopathological diagnosis of spindle cell carcinoma should be referred for treatment as soon as possible, including resection of the lesion with a large margin, and aggressive combined chemotherapy and radiotherapy. Regular control visits and diagnosis after completed treatment are extremely important for the final outcome of treatment.

## DECLARATIONS

No financial support was received for the study which was conducted in accordance with the Declaration of Helsinki. Informed consent was obtained from the patient involved in the study.

## Conflict of interest.

The authors declare no conflict of interest.

## Data Availability Statement

The data presented in this study are available on request from the corresponding author.

## REFERENCES

1. Siegel RL, Miller KD, Fuchs HE, et al. Cancer statistics, 2021. *CA Cancer J Clin.* 2021;71:7–33.
2. World Health Organization Classification of Tumours Editorial Board. Soft tissue and bone tumours. In: International Agency for Research on Cancer. Lyon, France: IARC. 2020;3(5).
3. Feng L, Wang M, Yibulayin F, et al. Spindle cell sarcoma: a SEER population-based analysis. *Sci Rep.* 2018;8(1):5024.
4. Prakash N, Kumar H, Sharada P, et al. Spindle cell carcinoma of the oral cavity: a case report of a rare entity and review of literature. *World J Dent.* 2010;1:55–58.
5. Panthi S, Poudel S, Khanal N, et al. Spindle cell sarcoma: a case report of diagnostic and therapeutic quandary in a low resource setting. *J Surg Case Rep.* 2022; 1.
6. Feng L, Cai D, Muhetaer A, et al. Spindle cell carcinoma: the general demographics, basic clinico-pathologic characteristics, treatment, outcome and prognostic factors. *Oncotarget.* 2017; 8(26): 43228–43236.
7. Colney L, Panigrahi C, Sultania M, et al. Second primary spindle cell carcinoma of the tongue: a rare histology. *Cureus.* 2022; 14(7):e27175.
8. Su HH, Chu ST, Hou YY, et al. Spindle cell carcinoma of the oral cavity and oropharynx: factors affecting outcome. *J Chin Med Assoc.* 2006; 69(10):478–483.
9. Neha B, Shashi D, Seema R. Spindle cell squamous cell carcinoma of head and neck region: a clinicopathological and immunohistochemical study. *Indian J Surg Oncol.* 2021; 12(4):699–705.
10. Colizza A, Gilardi A, Greco A, et al. Carcinosarcomas of the larynx: systematic review of the literature of a rare nosologic entity. *Eur Arch Otorhinolaryngol.* 2022; 279(3):1167–1173.
11. Doyle LA. Sarcoma classification: an update based on the 2013 World Health Organization classification of tumours of soft tissue and bone. *Cancer.* 2014; 120(12):1763–74.
12. Schwitzer D, Kim R, Williams F, et al. Spindle cell sarcoma of the maxilla: a rare entity, case report and review of the literature. *J Oral Maxillofac Surg.* 2020;78(8):1334–1342.
13. Varshini M, Salian V, Shetty P, et al. Spindle cell carcinoma in the maxilla: a rare case and literature review. *Dent Res J (Isfahan).* 2019;16(1):60–63.
14. Halappa Nagaraj R, Grezenko H, Raut Y, et al. Recurrent retroperitoneal spindle cell sarcoma: a challenging case report and management considerations. *Cureus.* 2023;15(7):e42658.
15. Long X, Heming W, Siyu L, et al. Spindle cell carcinoma of the mandible: a case report. *J Biomed Res.* 2017; 31(3):273–276.
16. Mahdavi N, Yasaman K, Garajei A, et al. Bisphosphonate-related spindle cell carcinoma and osteonecrosis. *J Oral Maxillofac Pathol.* 2020;24(1):168–171.
17. Purnomo S, Afriansyah A, Mirza H, et al. A rare case report of paratesticular spindle cell tumour: inflammatory myofibroblastic tumour. *Int J Surg Case Rep.* 2023;106:108235.
18. Thompson LD, Wieneke JA, Miettinen M, et al. Spindle cell (sarcomatoid) carcinomas of the larynx: a clinicopathologic study of 187 cases. *Am J Surg Pathol.* 2002; 26(2): 153–170.
19. Chiesa-Estomba CM, Barillari MR, Mayo-Yáñez M, et al. Non-squamous cell carcinoma of the larynx: a state-of-the-art Review. *J Pers Med.* 2023;13(7):1084.
20. Rizzardi C, Frezzini C, Maglione M, et al. A look at the biology of spindle cell squamous carcinoma of the oral cavity: report of a case. *J Oral Maxillofac Surg.* 2003;61(2):264–268.
21. Ciapinski D, Kubon M. Zastosowanie szablonów chirurgicznych w praktyce implantologicznej. Przegląd literatury i przypadki kliniczne. *Implantologia w praktyce. Implant Stom.* 2020;1(21): 72–78.