



Urinary tract infection as cause of a septic miscarriage and disseminated intravascular coagulation – case report and literature review

Zuzanna Paluch^{1,A-D}, Milena Krawczyk^{1,A-D}, Piotr Duda^{1,A-D}, Elżbieta Rypulak^{2,E-F},
Oksana Wichowska^{2,E-F}

¹ Student Research Group, Second Department of Anaesthesiology and Intensive Therapy, Medical University, Lublin, Poland

² Second Department of Anaesthesiology and Intensive Therapy, Medical University, Lublin, Poland

A – Research concept and design, B – Collection and/or assembly of data, C – Data analysis and interpretation, D – Writing the article, E – Critical revision of the article, F – Final approval of the article

Paluch Z, Krawczyk M, Duda P, Rypulak E, Wichowska O. Urinary tract infection as cause of a septic miscarriage and disseminated intravascular coagulation – case report and literature review. *J Pre-Clin Clin Res*. doi: 10.26444/jpccr/168416

Abstract

Urinary tract infection (UTI) is one of the most common bacterial infections which affect 150 million people worldwide annually. Pregnant women are particularly vulnerable to UTIs. Untreated asymptomatic bacteriuria in pregnancy can develop into an acute state, leading to serious complications, such as sepsis, pulmonary oedema, acute respiratory distress syndrome, anaemia, spontaneous miscarriage, or preterm labour. All bacteriuria in pregnancy should be treated, and antibiotic choice in pregnancy should reflect safety for both the mother and the foetus. The case is presented of a 37-year-old woman in 20 Hbd pregnancy who was transferred to an Intensive Care Unit due to right-side renal colic symptoms caused by urinary tract obstruction. Despite immediate treatment, the next day, septic miscarriage and disseminated intravascular coagulation (DIC) occurred.

Key words

pregnancy, urinary tract, bacteriuria, critical care

INTRODUCTION

According to the definition, sepsis is a specific, complex, and life-threatening response to infection in which uncontrolled complement activation, coagulation, and platelet dysfunction lead to tissue damage and organ dysfunction [1]. In the last 20 years, the number of cases of severe sepsis has doubled, the main reasons being an aging population, increasing antibiotic resistance, and invasive treatments [2, 3]. The number of sepsis cases worldwide is increasing at a rate of 1.5% per year. Sepsis is ranked 11th among all causes of death [4], and various types of coagulopathies are very common in patients with sepsis [1].

Urinary tract infection (UTI) is one of the most common bacterial infections, affecting 150 million people worldwide annually [5]. Microbial pathogens could be found in any part of the urinary tract, including the kidneys, ureters, bladder, or urethra [6]. UTI more often affects women. The close location of the urethra outlet relative to the rectum and the shorter urethra in women (compared to men) makes it easier for bacterial colonizers to reach the bladder [6, 7]. Pregnant women are particularly at risk of developing urinary tract infections. During pregnancy, numerous anatomical, physiological, and hormonal changes lead to the optimal development of the foetus. Since about 7 weeks of pregnancy, the ureters and renal calyx are dilated, caused by mechanical pressure of the ureters due to the increasing size of uterus,

and the action of progesterone [6, 7, 8]. Progesterone can also cause smooth muscle relaxation, which leads to spasms and stagnation of urine, and intensification of bladder-ureter outflow. In addition, glucosuria and decreased urine pH may promote the development of UTI [6, 8].

Urinary tract infections can have a very diverse clinical course – asymptomatic bacteriuria (ABI), infections of the lower urinary tract (cystitis), or infections of the upper urinary tract (pyelonephritis) [9]. ABI is defined as more than 100,000 organisms/ml in pure urine analysis obtained from a patient without symptoms and affects 2 – 10% of pregnant women [6, 7, 8]. All bacteriuria in pregnancy should be treated, and antibiotic choice in pregnancy should reflect safety for both the mother and the foetus [9,10]. Untreated asymptomatic bacteriuria in pregnancy can cause an acute state, leading to serious complications, such as sepsis, pulmonary oedema, acute respiratory distress syndrome, anaemia, spontaneous miscarriage, or preterm labour [8, 9, 10].

The case is presented of a 37-year-old woman in 20 Hbd pregnancy who was transferred to an intensive care unit due to right-side renal colic symptoms caused by urinary tract obstruction. Despite immediate treatment, the next day, the development of septic miscarriage and disseminated intravascular coagulation (DIC) occurred.

CASE REPORT

In 2022, a 37-year Caucasian female patient in 20 Hbd pregnancy presented to an Intensive Care Unit (ICU) due to right-side renal colic symptoms. Her previous gynaecologic history included two pregnancies with uncomplicated natural

Address for correspondence: Zuzanna Paluch, Student Research Group, Second Department of Anaesthesiology and Intensive Therapy, Medical University, Lublin, Poland

E-mail: zuza.paluch3@gmail.com

Received: 13.05.2023; accepted: 16.06.2023; first published: 26.06.2023

labour. Imaging diagnostic revealed right-side urinary tract obstruction, resulting in a JJ ureteric stent insertion. On the second day of hospitalization, the patient miscarried, and curettage of the uterine cavity was performed. Due to progressive coagulation impairments, the patient was transferred to a tertiary ICU on the same day.

The patient's circulation and respiratory systems were insufficient during admission to the tertiary ICU. Stomach examination revealed tenderness in the epigastrium and right subcostal area, and a petechial rash was noticed on the face and extremities. Obstetrician consultation revealed plentiful lochia rubra and the uterine fundus localized halfway between the umbilicus and pubic symphysis. Because the patient was at the onset of lactation, oral bromocriptine was administered to block it. The patient was conscious and remained in logical contact.

Laboratory testing performed during arrival at the ICU revealed several abnormalities in biochemical parameters, including significantly disrupted coagulation parameters, elevated acute phase proteins, and anaemia (Tab. 1).

Within the first day of the ICU administration, the patient received norepinephrine infusion and oxygen supplementation via nasal cannulas due to insufficiency of the circulatory and respiratory systems. Sepsis was treated with i.v. meropenem and i.v. levofloxacin. The coagulation abnormalities were treated with 5 units of cryoprecipitate, 2 units of red blood cells, and 3 gm of fibrinogen.

On the second day of hospitalization, urine analysis revealed leukocyturia, erythrocyturia, and bacteriuria. One

day later, a chest X-ray and chest ultrasonography (USG) showed the presence of fluid in the pleural cavity, with a slight progression on day 4. Consequently, thoracocentesis was performed on the 4th and the 5th day with 1000ml and 1,300ml of the pleural effusion collected from the right pleural cavity, respectively. On day 6 of hospitalization, a chest USG revealed pleural cavity fluid on the patient's left side. On the following day, another thoracocentesis was performed, with 700ml of the fluid collected from the left pleural cavity. On the 5th day of hospitalization, the bacterial culture of urine showed no bacterial growth, and the cultures of the nasopharynx and anus showed physiological bacterial microbiota. On the same day, minor oedema of the lower extremities appeared and persisted until discharge from the ICU to the primary hospital. Two days after the patient's discharge, the blood culture showed no bacterial growth.

In total, the coagulopathy was treated with 5 units of cryoprecipitate, 4 units of fresh frozen plasma, 3 units of platelets, and 3 g of fibrinogen. For treatment of the anaemia, 4 units of red blood cells were used. The noradrenaline flow was maintained until the 7th day, while the oxygen supplementation was administered until the patient was discharged from the ICU.

After 7 days in the ICU, the patient, in good condition with minor uterine bleeding and a minor lower extremities oedema, was transferred to the Department of Obstetrics and Gynaecology for the continuation of treatment. The case report timeline is presented in Figure 1.

Table 1. Patient's laboratory results

Laboratory test	1 day	2 day	3 day	4 day	5 day	6 day	7 day	8 day	Referential range	Unit
APTT	N/A	42.20	72.60	47.80	33.90	27.20	30.30	32.00	25.0–37.0	s
PT	N/A	15.2	17.3	14.8	13.1	12.9	12.4	12.6	9.2–13.8	s
D-dimers	N/A	Not measurable	437400	122641	56742	28043	14325	3932	<500	ng/ml
Fibrinogen	N/A	1.8	2.1	3.0	3.3	3.0	2.3	1.9	2.0–3.9	g/l
Neutrophils	N/A	19.49	24.91	34.68	26.14	21.07	22.60	23.13	2.25–12.5	K/ μ l
Lymphocytes	N/A	0.22	0.57	0.55	1.79	3.13	4.24	4.34	0.8–4.3	K/ μ l
Platelets	N/A	33	37	11	40	26	70	79	130–400	K/ μ l
Procalcitonin	N/A	N/A	188.3	57.74	17.26	7.44	3.99	1.8	<0.5	ng/ml
CRP	N/A	N/A	233.6	343.5	339.0	171.1	93.0	52.3	0.08–3.1*	mg/l

APTT – activated partial thromboplastin time; CRP – C-reactive protein; PT – prothrombin time; * referential range based on [11]

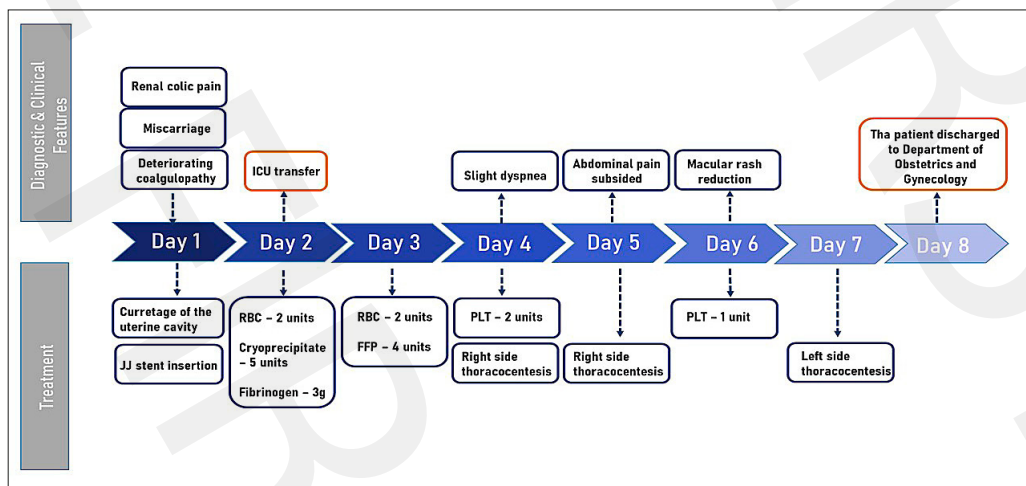


Figure 1. Case report timeline. ICU – Intensive Care Unit; RBC – Red Blood Cells; FFP – Fresh Frozen Plasma; PLT – Platelet Count

DISCUSSION

In the presented case, a 37-year-old woman in her 20 hbd pregnancy was admitted to the ICU for symptoms of right-sided renal colic. Imaging diagnosis revealed urinary tract obstruction on the right side, probably caused by the patient's overlooked infectious urinary tract infection. On the second day of hospitalization, the patient miscarried, and a uterine cavity curettage was performed. The most likely cause of the patient's miscarriage was progressive sepsis. Worldwide, miscarriage accounts for approximately 14% of pregnancy-related deaths, and septic miscarriages are the leading cause of miscarriage [12].

The patient progressed to cardiopulmonary failure with associated coagulation disorders on the same day. Laboratory tests indicated suspected DIC syndrome and sepsis (Tab. 1). No single laboratory or clinical test exists for the definitive diagnosis of DIC syndrome [13]. Results of laboratory tests indicated a diagnosis of DIC syndrome, and included assessment of platelet count (decrease), clotting time – APTT and/or PT (prolongation), fibrinogen concentration (reduction), and evaluation of fibrin/D-dimer breakdown products (increase). It is essential to repeat the tests in order to observe the correlation between laboratory findings and the patient's clinical condition [14 – 17]. In the presented case, the patient's sepsis probably developed during a urinary tract infection that had been untreated for too long. As a probable complication of sepsis, the patient developed DIC syndrome.

The mechanism of sepsis involves direct and indirect platelet activation, increased platelet reactivity, and increased platelet release from the bone marrow [1]. Furthermore, the patient was also after a fresh miscarriage. The incidence of DIC during pregnancy varies between cohorts and ranges from 0.03% – 0.35% [18, 19]. In DIC syndrome, treatment options include identifying and treating the underlying disease, supporting the haemostatic system with blood products, and close observation of the patient [13].

In the presented case, the patient's coagulation disorder was treated with 5 units of cryoprecipitate, 4 units of fresh frozen plasma, 3 units of platelets, and 3 g fibrinogen. The patient's sepsis, which was the most likely cause of DIC syndrome, was treated with i.v. meropenem and i.v. levofloxacin, as laboratory tests did not identify the causative pathogen. According to the study, starting empirical treatment with broad-spectrum antibiotics as soon as possible is crucial when sepsis is reasonably suspected [20, 21]. In addition, due to circulatory and respiratory failure, the patient was given oxygen supplementation and norepinephrine infusions, as supportive vasopressors are also recommended in the initial treatment of sepsis [20].

To conclude, DIC is a complicated life-threatening condition characterized by systemic activation of coagulation in various diseases, particularly sepsis [22]. For the treatment of DIC in sepsis, prompt recognition, transfer of the patient to a qualified ICU, and implementation of antibiotic therapy are essential. Administration of blood products to maintain homeostasis is also crucial. Early implementation of effective treatment is a critical factor in patient survival [1, 18].

REFERENCES

- Giustozzi M, Ehrlinder H, Bongiovanni D, et al. Coagulopathy and sepsis: Pathophysiology, clinical manifestations and treatment. *Blood Rev.* 2021;50:100864. doi:10.1016/j.blre.2021.100864
- Kutnik P, Szczukocka M, Borys M, et al. Procalcitonin dynamics, lactates, and haemoglobin serum levels might be a useful predictive

- tool of mortality in patients undergoing veno-venous extracorporeal oxygenation membrane support. Single centre experience. *Anaesthesiol Intensive Ther.* 2019;51(5):343–347. doi:10.5114/ait.2019.90235. PMID: 31893600
- Onichimowski D, Będzowska A, Ziółkowski H, et al. Population pharmacokinetics of standard-dose meropenem in critically ill patients on continuous renal replacement therapy: a prospective observational trial. *Pharmacol Rep.* 2020;72(3):719–729. doi:10.1007/s43440-020-00104-3. Epub 2020 Apr 16. PMID: 32301057; PMCID: PMC7329797
- Angus DC, Linde-Zwirble WT, Lidicker J, et al. Epidemiology of severe sepsis in the United States: analysis of incidence, outcome, and associated costs of care. *Crit Care Med.* 2001;29(7):1303–10. doi:10.1097/00003246-200107000-00002
- McLellan LK, Hunstad DA. Urinary Tract Infection: Pathogenesis and Outlook. *Trends Mol Med.* 2016;22(11):946–957. doi:10.1016/j.molmed.2016.09.003
- Kalinderi K, Delkos D, Kalinderis M, et al. Urinary tract infection during pregnancy: current concepts on a common multifaceted problem. *J Obstet Gynaecol.* 2018;38(4):448–453. doi:10.1080/0144336.15.2017.1370579. Epub 2018 Feb 6. PMID: 29402148
- Geerlings SE. Clinical Presentations and Epidemiology of Urinary Tract Infections. *Microbiol Spectr.* 2016;4(5). doi:10.1128/microbiolspec.UTI-0002-2012. PMID: 27780014
- Habak PJ, Griggs, Jr RP. Urinary Tract Infection In Pregnancy. In: StatPearls. StatPearls Publishing, Treasure Island (FL); 2022. PMID: 30725732
- Glaser AP, Schaeffer AJ. Urinary Tract Infection and Bacteriuria in Pregnancy. *Urol Clin North Am.* 2015;42(4):547–60. doi:10.1016/j.ucl.2015.05.004. Epub 2015 Aug 1. PMID: 26475951
- Bookstaver PB, Bland CM, Griffin B, et al. A Review of Antibiotic Use in Pregnancy. *Pharmacotherapy.* 2015;35(11):1052–62. doi:10.1002/phar.1649. PMID: 26598097
- Gajewski P, et al. Interna Szczeklika 2022 – Mały Podręcznik. 14th ed. Kraków; 2022.
- Eschenbach D, Treating spontaneous and induced septic abortions. *Obstet Gynecol.* 2015;125(5):1042–1048. doi:10.1097/AOG.0000000000000795
- Erez O. Disseminated intravascular coagulation in pregnancy – Clinical phenotypes and diagnostic scores. *Thrombosis Res.* 2017;S56–S60. doi:10.1016/S0049-3848(17)30069-5
- Levi M, Toh CH, Thachil J, et al. Guidelines for the diagnosis and management of disseminated intravascular coagulation. British Committee for Standards in Haematology. *Br J Haematol.* 2009;145(1):24–33. doi:10.1111/j.1365-2141.2009.07600.x
- Wada H, Thachil J, Di Nisio M, et al. Harmonized guidance for disseminated intravascular coagulation the International Society on Thrombosis and Haemostasis and the current status of anticoagulant therapy in Japan: a rebuttal. *J Thromb Haemost.* 2013;11(11):2078–9. doi:10.1111/jth.12366
- Gando S, Wada H, Thachil J. Scientific and Standardization Committee on DIC of the International Society on Thrombosis and Haemostasis (ISTH). Differentiating disseminated intravascular coagulation (DIC) with the fibrinolytic phenotype from coagulopathy of trauma and acute coagulopathy of trauma-shock (COT/ACOTS). *J Thromb Haemost.* 2013;11(5):826–35. doi:10.1111/jth.12190
- Piwożarczyk P, Borys M, Kutnik P, et al. Unfractionated Heparin Versus Subcutaneous Nadroparin in Adults Supported With Venovenous Extracorporeal Membrane Oxygenation: a Retrospective, Multicenter Study. *ASAIO J.* 2021;67(1):104–111. doi:10.1097/MAT.0000000000001166. PMID: 32404610
- Rattray DD, O'Connell CM, Baskett TF. Acute disseminated intravascular coagulation in obstetrics: a tertiary centre population review (1980 to 2009). *J Obstet Gynaecol Can.* 2012;34(4):341–347. doi:10.1016/S1701-2163(16)35214-8
- Erez O, Novack L, Beer-Weisel R, et al. DIC score in pregnant women – a population based modification of the International Society on Thrombosis and Hemostasis score. *PLoS One.* 2014;11(9):e93240. doi:10.1371/journal.pone.0093240
- Font MD, Thyagarajan B, Khanna AK. Sepsis and Septic Shock – Basics of diagnosis, pathophysiology and clinical decision making. *Med Clin North Am.* 2020;104(4):573–585. doi:10.1016/j.mcna.2020.02.011
- Borsuk-De Moor A, Rypulak E, Potręć B, et al. Population Pharmacokinetics of High-Dose Tigecycline in Patients with Sepsis or Septic Shock. *Antimicrob Agents Chemother.* 2018;62(4):e02273–17. doi:10.1128/AAC.02273-17. PMID: 29358291; PMCID: PMC5913959
- Iba T, Levi M, Levy JH. Sepsis-Induced Coagulopathy and Disseminated Intravascular Coagulation. *Semin Thromb Hemost.* 2020;46(1):89–95. doi:10.1055/s-0039-1694995