



Guillain-Barré syndrome associated with COVID-19 infection – Case Report and literature review

Zuzanna Paluch^{1,A-D}✉, Natalia Biedroń^{1,A-D}, Agnieszka Kaczmarek^{1,A-D},
Justyna Sysiak-Sławecka^{2,E-F}

¹ Student Research Group / Second Department of Anaesthesiology and Intensive Therapy, Medical University, Lublin, Poland

² Second Department of Anaesthesiology and Intensive Therapy, Medical University, Lublin, Poland

A – Research concept and design, B – Collection and/or assembly of data, C – Data analysis and interpretation, D – Writing the article, E – Critical revision of the article, F – Final approval of the article

Paluch Z, Biedroń N, Kaczmarek A, Sysiak-Sławecka J. Guillain-Barré syndrome associated with COVID-19 infection – case report and literature review. J Pre-Clin Clin Res. doi: 10.26444/jpccr/166116

Abstract

Guillain-Barré syndrome (GBS) is a rare, acute immune-mediated polyradiculoneuropathy that accounts for an estimated 100,000 new cases annually worldwide. The typical clinical manifestations of the disease are progressive, ascending paralysis, classically involving bilateral upper and lower extremities. In most patients, the acute onset of neurological symptoms is preceded by an infectious respiratory or gastrointestinal illness. The case is presented of a 50-year-old man who was transferred to an intensive care unit from the Department of Neurology, due to a worsening state of bilateral weakness of limbs, with symptoms of respiratory failure and hemodynamic instability. Guillain-Barré syndrome was diagnosed in the previous clinic on the basis of the typical symptoms and results of cerebrospinal fluid, in which albuminocytological dissociation was detected. Furthermore, two weeks previously, the patient had been infected with COVID-19.

Key words

respiratory failure, COVID-19, Guillain-Barré syndrome

INTRODUCTION

Coronavirus disease 2019 (COVID-19), an infection caused by the coronavirus 2 severe acute respiratory syndrome (SARS-CoV-2), began in Wuhan, China, in December 2019 [1]. What originally had been a local epidemic evolved into a global pandemic with uncertain and tragic consequences that also affected Polish citizens [2]. Although the earliest reports naturally highlighted respiratory symptoms, it was quickly recognized that SARS-CoV-2, like other coronaviruses, can affect the central and peripheral nervous system [3]. Clinical presentations of COVID-19 may include dizziness, confusion, seizures, anosmia, dysgeusia, myalgia, and headache in the early stage of the disease. Late consequences of COVID-19 may include stroke and impaired level of consciousness [4, 5]. According to current knowledge, Guillain-Barré syndrome (GBS) can also be associated with COVID-19 infection [6].

Guillain-Barré syndrome (GBS) is an acute immune-mediated disease in which the immune system invades the Schwann cells of the peripheral nerves and nerve roots (polyradiculoneuropathy) [7, 8, 9]. GBS is a rare disease that accounts for an estimated 100,000 new cases annually worldwide [10]. The disease affects men with a slightly higher incidence than women [10]. The typical clinical manifestations of the disease are progressive, ascending, symmetrical flaccid bilateral upper and lower extremities paralysis, areflexia or

hyporeflexia, with or without cranial nerve involvement, and can progress over days to several weeks [7, 11]. In addition, half of the patients may also experience a sensory disturbance in the form of paraesthesia or numbness [11].

About 30% of patients develop acute respiratory failure and haemodynamic disability by disruption of the autonomic nervous system [8, 10]. In most patients, the acute onset of neurological symptoms is preceded by an infectious respiratory or gastrointestinal illness [9, 10, 11]. This acute polyradiculoneuropathy is preceded by a symptomatic bacterial or viral infection, most often with *Campylobacter jejuni*, *Mycoplasma pneumoniae*, *Haemophilus influenzae*, cytomegalovirus (CMV), influenza, enteroviruses, Epstein-Barr virus (EBV), herpes simplex virus, hepatitis, human immunodeficiency virus and Zika virus [7, 8]. Diagnosis of the disease is mainly based on the typical clinical manifestations, albuminocytological dissociation in cerebrospinal fluid, and electrodiagnostic evidence of neuropathy [9, 10, 11]. The treatment of choice is intravenous immunoglobulin, plasma exchange, intensive care and long-term rehabilitation therapy [7, 9, 11].

The study aimed to present the case report of a 50-year-old patient with Guillain-Barré syndrome associated with COVID-19.

CASE REPORT

A 50-year-old man was admitted to the Department of Neurology, presenting with significant muscle weakness of bilateral lower limbs and difficulty in moving. Two weeks previously, the patient was diagnosed with COVID-19.

✉ Address for correspondence: Zuzanna Paluch, Student Research Group, Second Department of Anaesthesiology and Intensive Therapy, Medical University, Lublin, Poland

E-mail: zuza.paluch3@gmail.com

Received: 27.02.2023; accepted: 12.05.2023; first published: 22.05.2023

In the patient's history, he was treated for hypertension. Results of the analysis of cerebral spinal fluid (CSF) revealed an albuminocytological dissociation and based on clinical presentation and CSF analysis, the patient was diagnosed with Guillain-Barré syndrome. He was referred to the Department of Anaesthesiology and Intensive Care for further treatment.

On admission to the department, the patient was conscious and in logical contact. On physical examination, the patient was afebrile, with blood pressure of 200/105 mmHg, respiratory rate – 33 per minute, and oxygen saturation – 88–90% on air. Lung ultrasonography demonstrated massive consolidation in the lower lobes of both lungs, but he was breathing spontaneously during passive oxygen therapy. Neurological examination showed weakness of the bilateral lower limbs which progressed in an ascending pattern involving both upper limbs and neck muscles, requiring assisted ventilation. Babinski's response was not observed. Non-invasive mechanical ventilation with a 40–35% fraction of inspired oxygen (FiO₂) with positive end-expiratory pressure (PEEP) of 8 cmH₂O was used. Dysphagia and speech impairments were also observed.

On the first day of hospitalization, the patient received plasmapheresis treatment (12 j FFP). After the procedure, significant improvement in the muscle strength of the upper and lower limbs was observed, with improved respiratory mechanics, and the possibility of swallowing. Due to hyperglycaemia (209 mg/dL) and glucose in the urine, insulin was included.

On the third day of hospitalization, after the second plasmapheresis, muscular strength significantly improved, together a decreased respiratory rate compared to the previous days. The patient was breathing spontaneously, supported by passive oxygen therapy using a venturi mask containing FiO₂ 0.6.

During the whole hospitalization, a total number of 5 plasmapheresis treatments were performed. The patient's condition improved significantly – respiratory failure and dysphagia subsided. Weakness of the bilateral lower limbs and radiculitis remained unchanged. The patient stayed in the intensive care unit (ICU) for two weeks.

He was discharged in a haemodynamically and respiratory stable condition, conscious in logical, verbal contact, to the Department of Neurology to continue treatment. The case report timeline is presented in Figure 1.

DISCUSSION

The prevalence of neurological complications in COVID-19 patients is estimated to be 30%–80% of cases, depending on the severity of the disease [12]. Neurological complications may be caused directly by a viral infection or may occur as a consequence of treatment [13]. The cause of neurological disorders in COVID-19 may be a dysfunction of gas exchange in the lungs, leading to poor oxygenation of the brain, which may explain encephalopathy and other symptoms; however, despite several hypotheses in the literature, the pathophysiological mechanism of many neurological disorders as a result of COVID-19 remains unclear [14]. Berra et al. hypothesized that the pathogenesis of GBS after COVID-19 may be also indirectly related to ICU treatment, thrombotic complications in coagulopathy, endotheliopathy, and/or vasculitis involving vasa nervorum [15]. Inadequate dosing of thromboprophylaxis in the population of critically ill COVID-19 patients may be one of the factors predisposing to neuropathies [16]. In addition, some patients have been diagnosed with autoimmune neurological disorders due to COVID-19, including Guillain-Barré Syndrome (GBS) [12]. GBS has also been reported in several people worldwide after COVID-19 vaccination. Furthermore, some studies suggest a link between GBS and different types of COVID-19 vaccines [17].

The average time from the onset of infectious symptoms of COVID-19 to a presentation of GBS was two weeks, similar to other infections prior to GBS [18, 19]. The latency between COVID-19 infection and GBS was more than a week for most cases, but it should be taken into consideration that COVID-19 can initially be asymptomatic, which makes the latency duration arguably longer than reported. This suggests post-infectious immune pathogenesis rather than direct neural damage or a para-infective mechanism [18]. Currently, there are still no biomarkers with good sensitivity and specificity for GBS, and the diagnosis of GBS relies on the results of clinical, electrophysiological, and cerebrospinal fluid (CSF) examinations [19].

The basis for the diagnosis of Guillain-Barré syndrome is a clinical analysis of the patient, consisting of the search for symptoms based on the interview and the detection of symptoms in the physical examination. The mandatory characteristics of the diagnosis to be made are a progressive weakness of the limbs, accompanied by decreased reflexes in the affected limbs. Factors supporting the diagnosis involve:

- a progression of up to four weeks;
- symmetry of motor and sensory deficit;
- mild sensory involvement;
- involvement of the cranial nerves (principally VII);

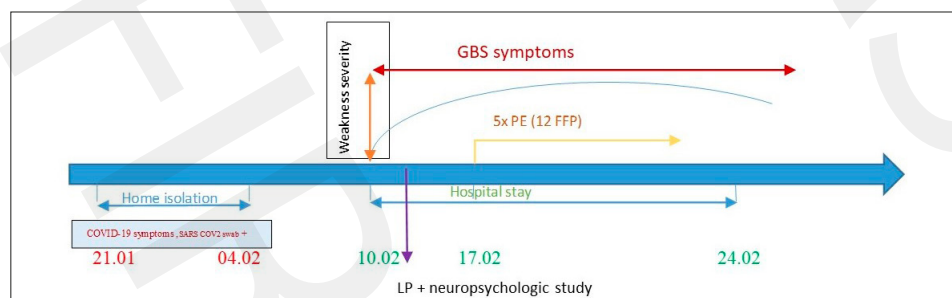


Figure 1. Timeline of clinical events, diagnostic and treatment interventions. Covid-19- coronavirus disease 2019, GBS Guillain-Barré Syndrome, LP- lumbar puncture, PE- plasma exchange, FFP- fresh frozen plasma

- onset of recovery four weeks from the stop of progression, autonomic dysfunction;
- absence of fever at onset, albuminocytological dissociation in CSF;
- slow or blocked nerve conduction for several weeks on electroneuromyography [6].

The results of cerebrospinal fluid analysis reflect typical neurochemical results in GBS other than COVID-19. The latest analyses have shown that most COVID-19-related GBS patients observe: albumin-cytological dissociation, elevated protein levels, and normal white blood cell levels [20]. Laboratory tests, including glucose and electrolytes, may be helpful in the diagnosis of GBS in order to exclude other causes of flaccidity, such as hypoglycaemia, hypokalemia, periodic thyrotoxic-hypokalemic paralysis, hypomagnesemia, hypophosphatemia, hypothyroidism, or porphyria [10]. Isolated cases with positive anti-ganglioside antibodies have been observed in COVID-19-related GBS [19, 20]. However, a positive test result can be helpful, especially when the diagnosis is questionable, but a negative test result does not exclude GBS.

Electrodiagnostic examinations are not necessary to diagnose GBS, but they can prove very helpful, especially for patients with unusual images of the disease and the differentiation of its subtypes. The most common findings were: decreased conduction speed, decreased amplitude of the functional potential of the muscles, and decreased/no sensory amplitude of the functional potential. As regards the distribution of the electrophysiological variants of GBS, several studies have shown that COVID-19-related GBS is mainly manifested as acute inflammatory demyelinating polyneuropathy – AIDP. To a lesser extent, cases of acute motor axonal neuropathy (AMAN), acute motor sensory axonal neuropathy (AMSAN), pharyngeal–cervical–brachial variant, and Miller-Fisher syndrome (MFS) have been reported [19, 20].

The patient described in the case report showed albuminocytological dissociation, i.e., an elevated CSF protein level and a standard number of CSF cells, which occurs in GBS [21]. The patient presented with typical GBS symptoms about two weeks after recovering from COVID-19. The literature indicates that two-thirds of GBS patients present with symptoms of infection within the past six weeks [22]. Reasons for admission of patients with GBS to the intensive care unit include respiratory failure, severe cardiovascular dysfunction, such as arrhythmias or significant changes in blood pressure, severe swallowing dysfunction or reduced cough reflex, and rapid progression of muscle weakness [21]. The described patient had most of the symptoms mentioned above, therefore, treatment was initiated in the ICU. During hospitalization, the patient developed hyperglycaemia (209 mg/dl) and the presence of glucose in the urine. Higher fasting plasma glucose levels are often seen in patients with cranial nerve involvement or autonomic deficits, which are associated with a poorer short-term prognosis; therefore, glucose monitoring is essential to predict the prognosis of patients with GBS. In addition, high levels of glucose in the cerebrospinal fluid are observed in approximately half of the patients and are significantly associated with severe GBS impairment [23, 24]. This factor is particularly evident in patients with diabetes or hyperglycaemia who experience an increased violation of the blood-brain barrier

[20]. In addition, dysglycaemia is correlated with neurological disability at ICU discharge and may delay motor recovery in patients dependent on mechanical ventilation [25].

Treatment of inflammatory neuropathies, including GBS, includes immunomodulatory and immunosuppressive therapies such as intravenous immunoglobulin, corticosteroids, or plasma exchange [26–29]. Different treatment methods of GBS, their effectiveness, duration of use, and dosage are presented in Table 1 [28–33]. The patient was treated with plasmapheresis – a total of five procedures. One year after treatment, full recovery of muscle strength is thought to be more likely to occur with plasma exchange than with adjunctive therapy alone in adults with GBS [34].

Table 1. Different methods of treatment of GBS, their effectiveness, duration of use, and dosage [28–33]

Treatment methods			
Plasmapheresis	Proven effectiveness	Administered for 1-2 weeks	Five exchanges, one volume of plasma each time (approximately 50 ml/kg body weight). Mild GBS-2 exchange. Moderate or heavy - minimum 4 replacements
IVIg immunoglobulins		For five consecutive days	0.4 g/kg body weight per day - 2 g/kg total
Corticosteroids	Lack of effectiveness		
Interferon β -1a	No direct confirmation of effectiveness		
Brain-derived neurotrophic factor			
Cerebrospinal fluid filtration			

In patients with COVID-19-related GBS, the course of the disease is often severe with a high rate of respiratory dysfunction requiring mechanical ventilation and ICU hospitalization [35]. By analogy with classic GBS, approximately one-fifth of patients with COVID-19-related GBS required mechanical ventilation during hospitalization [19]. Men are at higher risk of contracting COVID-19 and have a relatively higher risk of developing severe COVID-19 symptoms once they are hospitalized, and are more likely to require ICU admission [20]. This may be related to a generally shorter life expectancy or to higher circulating Angiotensin-Converting-Enzyme 2 (ACE2) levels, the cellular receptor for SARS-CoV-2 [19, 20]. In addition, autonomic dysfunction, advanced age (average 60 years), and comorbid lung disease are associated with a long duration of mechanical ventilation and the need for tracheostomy. Serum biomarkers including low albumin, low immunoglobulin elevation, and high serum neurofilament light chain may also be associated with inferior outcomes [10].

Despite the severity of the disease, however, most patients showed clinical improvement with partial or complete remission of GBS symptoms after treatment, and the residual ones did not include motor activity. Therefore, the development of GBS seems to be related to COVID-19 infection. In a recent meta-analysis [6] of 295 patients, 41 had a complete recovery, 148 had general or unspecified

improvement of the symptoms, and 67 patients had residual muscle weakness. Few had residual cranial nerve symptoms, paresthesia, neuropathic pain, sensory loss, remained areflexia, or dysautonomic symptoms. Mortality is estimated at 9.1% while no clinical improvement was observed in 4,7% of patients [6].

Additionally, clinicians should also be aware that approximately one-third of COVID-19-related GBS patients may develop neurological symptoms despite the absence of clinical and/or radiological signs of pneumonia [19]. This is evidence that GBS may also develop in the context of an asymptomatic or oligosymptomatic COVID-19, which makes it more difficult to diagnose post-COVID-19 GBS and underlines the need for SARS-CoV-2 screening in all cases.

In conclusion, GBS should be considered a neurological complication of COVID-19 infection. Given that the most common symptoms of COVID-19 infection are respiratory infections and most Guillain-Barre patients usually mention infections before symptoms, GBS should therefore be considered a neurological complication of COVID-19 infection. Early diagnosis of GBS in patients infected with COVID-19 is important because such a syndrome can be associated with a worrying evolution of their health condition requiring intensive therapy and mechanical ventilation. The described clinical case demonstrates that Guillain-Barré syndrome can occur as a complication of COVID-19, and plasmapheresis can be considered as an effective treatment modality in GBS.

REFERENCES

- Zhu N, Zhang D, Wang W, et al. A Novel Coronavirus from Patients with Pneumonia in China, 2019. *N Engl J Med*. 2020;382(8):727–733. doi:10.1056/NEJMoa2001017
- Piowarczyk P, Szczukocka M, Kutnik P, et al. Risk factors and outcomes for acute respiratory failure in coronavirus disease 2019: An observational cohort study. *Adv Clin Exp Med*. 2021;30(2):165–171. doi:10.17219/acem/130603
- Rogers JP, Watson CJ, Badenoch J, et al. Neurology and neuropsychiatry of COVID-19: a systematic review and meta-analysis of the early literature reveals frequent CNS manifestations and key emerging narratives. *J Neurol Neurosurg Psychiatry*. 2021;92(9):932–941. doi:10.1136/jnnp-2021-326405.
- Flores-Silva FD, García-Grimshaw M, Valdés-Ferrer SI, et al. Neurologic manifestations in hospitalized patients with COVID-19 in Mexico City. *PLoS One*. 2021;16(4):e0247433. doi:10.1371/journal.pone.0247433.
- Collantes MEV, Espiritu AI, Sy MCC, et al. Neurological Manifestations in COVID-19 Infection: A Systematic Review and Meta-Analysis. *Can J Neurol Sci*. 2021;48(1):66–76. doi:10.1017/cjn.2020.146.
- Pimentel V, Luchsinger VW, Carvalho GL, et al. Guillain-Barré syndrome associated with COVID-19: A systematic review. *Brain Behav Immun Health*. 2023;28:100578. doi:10.1016/j.bbih.2022.100578
- Goodfellow JA, Willison HJ. Guillain-Barré syndrome: a century of progress. *Nat Rev Neurol*. 2016;12(12):723–731. doi:10.1038/nrneurol.2016.172.
- Babazadeh A, Mohseni Afshar Z, Javanian M, et al. Influenza Vaccination and Guillain-Barré Syndrome: Reality or Fear. *J Transl Int Med*. 2019;31(7):137–142. doi:10.2478/jtim-2019-0028.
- Nguyen TP, Taylor RS. Guillain Barre Syndrome. 2022 Jul 4. In: *StatPearls* [Internet]. Treasure Island (FL): StatPearls Publishing; 2022 Jan-. PMID: 30335287.
- Shahrizaila N, Lehmann HC, Kuwabara S. Guillain-Barré syndrome. *Lancet*. 2021 Mar 27;397(10280):1214–1228. doi:10.1016/S0140-6736(21)00517-1.
- Malek E, Salameh J. Guillain-Barre Syndrome. *Semin Neurol*. 2019;39(5):589–595. doi:10.1055/s-0039-1693005.
- Ariño H, Heartshorne R, Michael BD, et al. Neuroimmune disorders in COVID-19. *J Neurol*. 2022;269(6):2827–2839. doi:10.1007/s00415-022-11050-w.
- Dangayach NS, Newcombe V, Sonnerville R. Acute Neurologic Complications of COVID-19 and Postacute Sequelae of COVID-19. *Crit Care Clin*. 2022 Jul;38(3):553–570. doi:10.1016/j.ccc.2022.03.002.
- Ahmad SJ, Feigen CM, Vazquez JP, et al. Neurological Sequelae of COVID-19. *J Integra Neurosci*. 2022;6;21(3):77. doi:10.31083/j.jin2103077.
- Berra E, Fundarò C, Chimento P, et al. Unusual sensory-motor neuropathies in post-COVID-19 patients admitted in rehabilitation hospitals: a case-series. *Eur J Phys Rehabil Med*. 2022;58(4):655–658. doi:10.23736/S1973-9087.21.06663-6
- Piowarczyk P, Szczukocka M, Cios W, et al. Population Pharmacokinetics and Probability of Target Attainment Analysis of Nadroparin in Different Stages of COVID-19. *Clin Pharmacokinet*. 2023;1-13. doi:10.1007/s40262-023-01244-4
- Abolmaali M, Rezaia F, Behnagh AK, et al. Guillain-Barré syndrome in association with COVID-19 vaccination: a systematic review. *Immunol Res*. 2022;70(6):752–764. doi:10.1007/s12026-022-09316-6. Epub 2022 Sep 13. PMID: 36098903; PMCID: PMC9469827.
- Aladawi M, Elfil M, Abu-Esheh B, et al. Guillain Barre Syndrome as a Complication of COVID-19: A Systematic Review. *Can J Neurol Sci*. 2022;49(1):38–48. doi:10.1017/cjn.2021.102
- Abu-Rumeileh S, Abdelhak A, Foschi M, et al. Guillain-Barré syndrome spectrum associated with COVID-19: an up-to-date systematic review of 73 cases. *J Neurol* 2021;268:1133–1170 doi:10.1007/s00415-020-10124-x
- Bentley SA, Ahmad S, Kobeissy FH, et al. Concomitant Guillain-Barré Syndrome and COVID-19: A Meta-Analysis of Cases. *Medicina (Kaunas)*. 2022;58(12):1835. doi:10.3390/medicina58121835
- Leonhard SE, Mandarakas MR, Gondim FAA, et al. Diagnosis and management of Guillain-Barré syndrome in ten steps. *Nat Rev Neurol*. 2019;15(11):671–683. doi:10.1038/s41582-019-0250-9.
- Doets AY, Verboon C, van den Berg B, et al. Regional variation of Guillain-Barré syndrome. *Brain*. 2018;141(10):2866–2877. doi:10.1093/brain/awy232.
- Mehta S. Neuromuscular disease causing acute respiratory failure. *Respir Care*. 2006;51(9):1016–21; discussion 1021–3. PMID: 16934165.
- Gong Q, Liu S, Xiao Z, et al. Elevated Blood and Cerebrospinal Fluid Glucose Levels Affect the Severity and Short-Term Prognosis of Guillain-Barré Syndrome. *Neurol Res*. 2021;44:121–127. doi:10.1080/01616412.2021.1965337.
- Shang P, Feng J, Wu W, et al. Intensive Care and Treatment of Severe Guillain-Barré Syndrome. *Front Pharmacol*. 2021;27:12:608130. doi:10.3389/fphar.2021.608130.
- Querol L, Lleixà C. Novel Immunological and Therapeutic Insights in Guillain-Barré Syndrome and CIDP. *Neurotherapeutics*. 2021;18(4):2222–2235. doi:10.1007/s13311-021-01117-3.
- Rypulak E, Borys M, Piowarczyk P, et al. Successful treatment of anti-NMDA receptor encephalitis with a prompt ovarian tumour removal and prolonged course of plasmapheresis: A case report. *Mol Clin Oncol*. 2016;5(6):845–849. doi:10.3892/mco.2016.1054.
- Liu S, Dong C, Ubogu EE. Immunotherapy of Guillain-Barré syndrome. *Hum Vaccin Immunother*. 2018;14(11):2568–2579. doi:10.1080/21645515.2018.1493415.
- Hughes RA, Swan AV, van Doorn PA. Intravenous immunoglobulin for Guillain-Barré syndrome. *Cochrane Database Syst Rev*. 2012;11(7):CD002063. doi:10.1002/14651858.CD002063.pub5.
- Hughes RA, Brassington R, Gunn AA, et al. Corticosteroids for Guillain-Barré syndrome. *Cochrane Database Syst Rev*. 2016;24(10):CD001446. doi:10.1002/14651858.CD001446.pub5.
- Zhang X, Xia J, Ye H. Effect of Tripterygium polyglycoside on interleukin-6 in patients with Guillain-Barre syndrome. *Zhongguo Zhong Xi Yi Jie He Za Zhi*. 2000;20(5):332–4. Chinese. PMID: 11789240.
- Wollinsky KH, Hülser PJ, Brinkmeier H, et al. CSF filtration is an effective treatment of Guillain-Barré syndrome: a randomized clinical trial. *Neurology*. 2001;11;57(5):774–80. doi:10.1212/wnl.57.5.774.
- Donofrio PD. Immunotherapy of idiopathic inflammatory neuropathies. *Muscle Nerve*. 2003;28(3):273–92. doi:10.1002/mus.10402. PMID: 12929187.
- Chevret S, Hughes RA, Annane D. Plasma exchange for Guillain-Barré syndrome. *Cochrane Database System Rev*. 2017;27(2):CD001798. doi:10.1002/14651858.CD001798.pub3.
- Shang P, Zhu M, Baker M, et al. Mechanical ventilation in Guillain-Barré syndrome. *Expert Rev Clin Immunol*. 2020;16:1053–64. doi:10.1080/1744666X.2021.1840355.