



Compartment syndrome – a complex and insidious medical problem

Michał Miciak^{1,A-D}, Krzysztof Jurkiewicz^{1,A-D}

¹ Medical University, Wrocław, Poland

A – Research concept and design, B – Collection and/or assembly of data, C – Data analysis and interpretation, D – Writing the article, E – Critical revision of the article, F – Final approval of the article

Miciak M, Jurkiewicz K. Compartment syndrome – a complex and insidious medical problem. J Pre-Clin Clin Res. doi: 10.26444/jpccr/163321

Abstract

Introduction and Objective. Compartment syndrome (CS) is a severe and rapidly progressing condition associated with muscle compartments restricted by fascia. It most commonly affects the lower extremities and develops as a result of bone fractures or soft tissue injuries. The essence is an increased pressure within the compartments which have limited ability to compensate their volumes. The aim of this review paper is to present the complexity of the problem, its pathophysiology and current methods of diagnosis and treatment.

Review Methods. Printed literature, PubMed and Google Scholar databases were searched using key words related to compartment syndrome, fasciotomy, fracture and trauma. Articles and book sections in English were searched and two positions from printed literature in Polish were used. Articles were selected after analyzing abstracts, and those which were incomplete or outdated were excluded. The types of articles included prospective studies, retrospective studies and reviews. The summary was supported by case studies to add imaging and clinical value to the study.

Brief description of the state of knowledge. From the initial search, 40 articles were retrieved for final analysis. The available data provide the latest information specifically on the diagnosis of compartment syndrome. Intra-compartmental pressure measuring devices currently in use were utilised. Treatment is based on surgical decompression called fasciotomy. The list of symptoms is intended to increase the consciousness in proceeding with this condition. New non-invasive diagnostic and treatment options are currently used in clinical research and provide a hopeful future in the described disease.

Summary. Compartment syndrome is a relatively uncommon trauma-related condition, and if untreated can lead to severe complications or even limb amputation. Management is urgent and strictly surgical.

Key words

surgery, compartment syndrome, fasciotomy, orthopaedics, intracompartmental pressure

Abbreviations

ΔP – delta pressure; **ACS** – acute compartment syndrome; **ATP** – adenosine triphosphate; **CECS** – chronic exertional compartment syndrome; **CS** – compartment syndrome; **HBO** – hyperbaric oxygen therapy; **ICP** – intracompartmental pressure; **IMA** – ischaemia-modified albumin; **NPWT** – negative pressure wound therapy

INTRODUCTION

Compartment syndrome (CS) is one of the few true emergency conditions in orthopaedics and traumatology. It is essentially a swelling of soft tissues in fascial compartments, which can lead to pain, compression of blood vessels and necrosis of the affected tissues. The entire process and circulatory disorders result from increased ICP (intra-compartmental pressure), which in CS is higher than 30mmHg (normal 0–8 mmHg) [1, 2]. The condition is most often located in the lower leg, although other parts of the body, such as the forearm, hand, foot, abdominal wall or buttock can also be affected. Depending on the severity and rapidity of the symptoms progression, the syndrome can be acute (acute compartment syndrome – ACS) or chronic (chronic exertional compartment syndrome – CECS). The causes of the acute condition mostly include severe trauma, bone fractures, crushing, and iatrogenic causes. The chronic condition results most frequently from over-exertion [3,6]. CS is an uncommon condition – the annual incidence is

estimated at 1–7.3 cases per 100,000 patients [1]. There is a gender disparity: men present a 10 times higher exposure to CS than women. The most typical age of onset of the syndrome is about 30 years for men and 44 years for women [7]. Despite the first description of CS more than 140 years ago by Richard von Volkmann, the disease remains a challenge for physicians, and its diagnosis and treatment continue to be a major difficulty for clinicians [4, 5].

STATE OF KNOWLEDGE

ACS – causes, locations and pathophysiology. ACS occurs most often after trauma. For ACS to occur, the fascial compartment must be affected somehow, the most common reason being an increase in its volume. The condition is typically the result of haemorrhage from damaged vessels, or transudation into the extravascular space. The great majority of cases (75%) are caused by fractures of the long bones, with the tibia being the cause reported most often. Other causes can be soft tissue injuries, ischemia, burns, crush injuries, thrombosis, infection, drug overdose (cocaine use, creatine supplementation), or post-reperfusion syndrome. However, iatrogenic ACS results from the too-tight placement

of plaster dressings, or improper patient positioning during surgery. [6, 37] Invasive diagnostic procedures, especially those that compromise arterial continuity, can also cause the described syndrome. Cases of patients after radial artery catheterization, confirm this infrequent etiology of ACS [10]. Substances administered during diagnostic procedures, can also cause the syndrome. A case has been described of ACS after intravenous administration and extravasation of methylene blue in urological diagnosis of ureteral injury [38]. Coagulation disorders are another rare cause of ACS in which cases have been described of patients taking antiplatelet (clopidogrel) or anticoagulant (warfarin) therapy, as well as patients with haemophilia B, who developed ACS after a minor trauma to the lower extremities and the formation of an intramedullary haematoma [8].

Idiopathic ACS is the rarest; the patient manifests characteristic symptoms of the syndrome such as pain or swelling, but without a clear cause or etiology [10]. In addition to the lower extremity, which is the most common site where ACS is experienced, symptoms can also affect other locations. Cases have been described of patients who developed ACS after injuries to the feet, upper extremities, buttocks, trunk wall, back muscles or pelvis [11–14]. In children, most often fractures of the humerus and forearm bones lead to ACS syndrome, following which ACS localizes precisely in the upper limb in this age group. These and not other locations of ACS are explained by the pathophysiology of the syndrome. It can arise in areas that have a very poor capacity for tissue expansion within themselves, and the intrafascial compartments are undoubtedly such locations [7]. When factors such as an increase in compartment volume (e.g. bleeding) or loss of ability to regulate compartment volume (e.g. a too tight plaster bandage) are triggered, an increase in ICP pressure occurs. At some point – once it reaches $>30\text{mmHg}$ – it exceeds the pressure in the venous capillary bearing, blood stagnates and finally compresses the arterial vessels. The arterial system tries to dilate which leads to a vicious circle mechanism and transpiration of higher amounts of fluid into the extracellular space, raising ICP even further [15, 16]. Reduced capillary perfusion leads to hypoxia, inflammation, decreased ATP concentration and oedema at the cellular level. Ultimately, all of these processes lead to imminent skeletal muscle necrosis in the absence of efficient diagnosis of the disease and implementation of treatment [16, 17]. The most common causes of ACS are summarized in Table 1.

Table 1. Most frequent causes of ACS [6]

CAUSES	NOTICES
long bone fractures	the tibia (mainly) the humerus (children)
soft tissue injuries	crushing, contusion, burn, frostbite
vascular causes	hemorrhage, ischemia
coagulation disorders	antiplatelet therapy, anticoagulation therapy, haemophilia, thrombosis
iatrogenic causes	improperly fitting splints, too tight bandages and casts, invasive vascular diagnostic procedures, improper patient position during surgery
others	infections, drug overdose, post-reperfusion syndrome, intense exercise

Calf compartments anatomy. The most common cause of ACS is a tibial fracture. In clinical practice, not only an

orthopaedic traumatologist will be encountered by patients suffering from lower limb fractures. Another specialty physician could also manage a patient after a recent fracture, with the limb stabilized by a plaster dressing, it is therefore important to know and understand the anatomy of the lower extremity and to note alarming symptoms in a patient after a fracture. There are three anatomical compartments of the lower leg: anterior (compartmentum cruris anterioris), posterior (compartmentum cruris posterius) and lateral (compartmentum cruris laterale). Considering the activity of the muscles located in these compartments, they are called the extensor, flexor and peroneal compartments, respectively. The posterior compartment is further divided into superficial and deep parts. The compartments are separated from each other by intermuscular septa: anterior and posterior. The anterior septum separates the anterior and lateral compartments, while the posterior septum separates the lateral and posterior compartments [18]. The septa are formed from the fascia of the lower leg, which surrounds the muscles from the outside and connects to the periosteum of the lower leg bone to form the compartments described (Fig. 1). The anterior compartment includes the extensor muscles, the anterior tibial artery and nerve, the lateral compartment includes the fibular muscles and the superficial fibular nerve, and the posterior compartment includes the flexor muscles, the fibular artery and the posterior tibial artery and nerve. The arteries are accompanied by unicompartimental deep veins of the lower leg. The vessels and nerves are additionally surrounded by connective tissue sheaths, which hold the structures in their proper position, facilitate venous return and protect against the spread of infection from adjacent tissues [19, 20]. The anterior compartment, due to its location and its restriction by the anterior edge of the tibia and a particularly thick layer of fascia of the lower leg, can generate the greatest pressure, it therefore appears to have the greatest contribution during the onset of ACS of the lower limb [21].

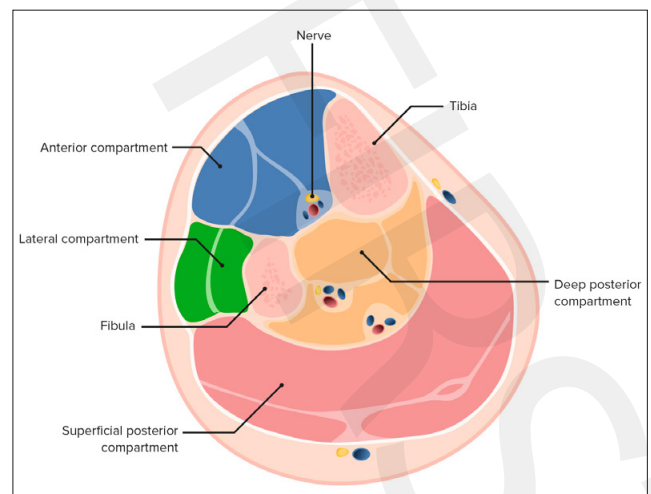


Figure 1. Calf compartments [42]

ACS – symptoms and diagnostics. A patient developing ACS will present symptoms that worsen with every passing minute. The classic symptoms are described with the phrase ‘Five Ps’ consisting of pain, pulseless, paresthesia, paralysis and pallor. In the literature, there are also additions to the phrase adding another ‘P’ which can be poikothermia or

pressure (high ICP). [1,2] Symptoms appear a few hours after the provoking factor of ACS, but it is also possible to postpone their onset for up to 48 hours. The earliest symptom is a feeling of tension in the involved part of the body. This is followed by tingling, paresthesias and pain. The pain is not relieved by pain medications, even with morphine, worsens when trying to passively stretch the muscles in the compartment, and can be sharp or burning. Paresthesias are the result of ischemia of peripheral nerves present earliest in distal areas (such as the foot). Pallor, pulseless, poikothermia and paralysis are late symptoms of ACS. Sensory deficits usually precede abnormalities in the movement of the extremity. Impaired active muscle mobility or muscle paresis are other late symptoms of ACS.

The patient may retain mobility of the foot in the early stages of ACS, but with time of hypoxia and muscle damage this mobility will increasingly disappear. Therefore, the diagnosis of ACS should not be delayed if the patient demonstrates proper mobility at onset of ACS (Tab. 2) [6,7,43]. Note that the listed symptoms are uncharacteristic (limited sensitivity and specificity), but may be helpful in diagnosing ACS. The patient should be examined for general (temperature, swelling, skin changes), neurological (motor function, two-point discrimination test) and vascular (pulse rate) abnormalities to adequately assess the involved area [22,23]; however, objective methods are needed to diagnose ACS.

Table 2. Most common symptoms of ACS. Based on [1, 2]

the classic „Five P’s”	Pain Pulseless Paresthesia Paralysis Pallor
others	6th „P” (Poikothermia or high intracompartmental Pressure) swelling tenderness burning numbness tingling

Compartment pressure monitoring. The most useful method in the diagnosis of ACS with which it is possible to obtain the value of the ICP parameter, which determines the correct diagnosis and the necessity for urgent surgical intervention. There are many devices for ICP monitoring, from traditional methods (Whiteside’s technique needle manometry) to the use of dedicated ICP monitors with a pressure transducer. In the method described by Whiteside, a needle is inserted into the muscle compartment and saline injected. The air resistance it must overcome is read as pressure by a mercury manometer connected through a tube to the needle [24]. Modern ICP measuring devices are also based during the injection of saline into the muscle compartment, and the pressure is read on the device’s screen (Stryker ICP monitoring system) (Fig. 2). The threshold for ACS is considered to be an ICP > 30mmHg. Today, the more commonly used parameter is delta pressure (ΔP), calculated from the formula: diastolic blood pressure – ICP. A value of $\Delta P < 30$ mmHg is considered the borderline of urgent surgical intervention. The importance of measuring ICP in any compartment, not just the anterior compartment (burdened with the highest probability of ACS), is further emphasized [25].

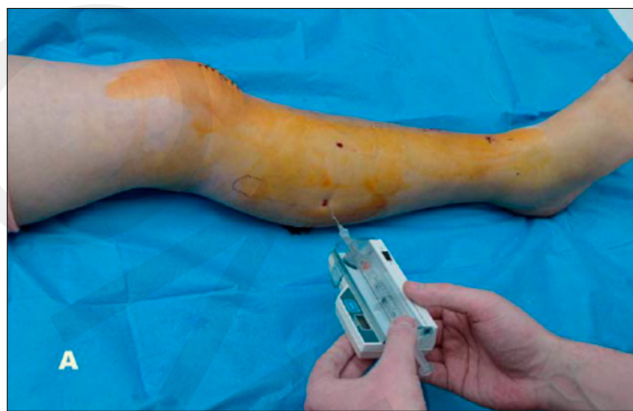

Figure 2. ICP measurement. Lateral compartment [26]

Other methods described in the diagnosis of ACS include: near-infrared spectroscopy – measurement of tissue oxygen saturation using a probe placed on the skin, pulsed phased-locked loop ultrasound (measurement of muscle fascial motion in relation to arterial motion in compartments), photoplethysmography, scintigraphy (specific measurement of arterial pressure, ICP and perfusion in compartments), measurements of tissue metabolism (muscle glucose utilization, intra-compartmental pH) or specific biomarkers (ischaemia-modified albumin – IMA). The usefulness of these methods is currently in the research stage, and it seems that refining their use in combination with ICP measurement and clinical examination will lead to better treatment outcomes for ACS patients [24, 27].

In addition, recent studies at the molecular level have identified some differences in immune cells in ACS patients. In the CD4 cell group, the GZMK+IFN-act subtype and high expression of genes responsible for the production of interferon and heat shock proteins were found [34]. This gives hope for the discovery of targeted cell-based treatments for ACS in the future.

ACS treatment. The treatment of ACS is surgical. ACS is an emergency condition that threatens the loss of a limb, therefore the procedure, a fasciotomy, must be performed immediately [1]. During the surgical procedure, the skin, subcutaneous tissue and fascia are cut through to lower the ICP pressure and release the compressed structures. The procedure must be performed within a maximum of 8 hours of the diagnosis of ACS. Objective indications for fasciotomy are ICP > 30mmHg and $\Delta P < 30$ mmHg. However, if ICP > 40mmHg, and the patient presents severe clinical symptoms (including general symptoms), fasciotomy should be performed within one hour of diagnosis [28]. Any dressings, bandages or plaster should be removed. It is not recommended to elevate the limbs above the heart level (due to ischemia). The procedure should be performed under general anesthesia in an Operating Theater [6]. A lower leg fasciotomy is usually a 4-compartment procedure, performed with 2 incisions – lateral and medial (Fig. 3). The lateral incision runs from the level of the tibial tuberosity to the lateral ankle, a few centimeters lateral to the anterior edge of the tibia. The anterior and lateral compartments are then opened through a fascial incision. The medial incision runs from the level of the tibial tuberosity to the medial ankle, a few centimeters back from the medial edge of the tibia. The

fascia is also incised and access to the posterior compartment is gained. It is important to remember to release also its deep part located under the soleus muscle. When performing a lateral incision, special attention should be paid to the superficial fibular nerve, and when performing a medial incision, to the saphenous vein and the saphenous nerve. These are superficially lying structures and there is a chance of injuring them [25,29].

Fasciotomy of the forearm, as the second most common site of ACS, must also be performed immediately after diagnosis. The forearm consists of 3 compartments: volar, dorsal and radial ('wad of three' compartment). The pronator quadratus muscle is described as a separate fourth compartment. Unlike the lower leg, these compartments are not independent and can be decompressed by common fascial incisions [7]. The cubital fossa area with lacertus fibrosus and carpal tunnel should be released first, due to the tightness of these areas and the fastest progressing vascular and nerve damage. A fasciotomy is performed using Henry's method with a Brunner zigzag incision running from the medial epicondyle region of the humerus to the carpal tunnel region, along with its decompression. Carpal tunnel decompression can also be performed independently in the metacarpus. Incisions are made parallel to the radial and ulnar carpal eminence. The dorsal side of the metacarpal is decompressed with 2 longitudinal incisions between the first and second, and third and fourth interosseal spaces [44]. In addition, release of entire neurovascular bundles may be required in cases of burns or electrical trauma.

Other modifications of these procedures utilize the formation of flaps covering the median nerve and radial artery, which is helpful in later possible reconstructive procedures and skin grafts [45]. A loose dressing moistened with saline is recommended immediately after surgery. Wounds are inspected at least once a day, and the possibility of closing them with sutures or using other methods, such as negative pressure wound therapy (NPWT), hyperbaric oxygen therapy (HBO), or covering with a skin graft, is evaluated. [25]

Complications of ACS and fasciotomy. Complications after fasciotomy are common (up to 1/3 of patients), and include wound infection, suture separation, soft tissue necrosis, osteomyelitis or blood vessel damage [25,29]. The timing for closing an incision and debridement at the surgery are equally important factors in reducing complications after fasciotomy. It has been described that patients with a wound uncovered up to 4 days after fasciotomy were reported to develop infection at a lower rate than patients with a wound uncovered more than 7 days after surgery. Also in open fractures, early closure and limiting the amount of time the bone is uncovered helps to decrease the incidence of wound infection and osteomyelitis [46]. Rhabdomyolysis can develop secondary to ACS in about 40% of patients, leading to renal failure. If untreated, ACS can lead to more severe conditions. Limb amputation appears to be by far the worst complication and occurs in about 10% of ACS patients [31–33], and usually develops on the irreversible tissue loss and infection. In order to recover, patients must undergo difficult and long-term rehabilitation [40]. Another consequence of untreated ACS can be Volkmann's ischemic contracture. This is a relatively rare condition, most often occurring after upper extremity injuries. Muscle ischemia is caused by arterial embolism or specifically ACS (the most common cause of Volkmann's

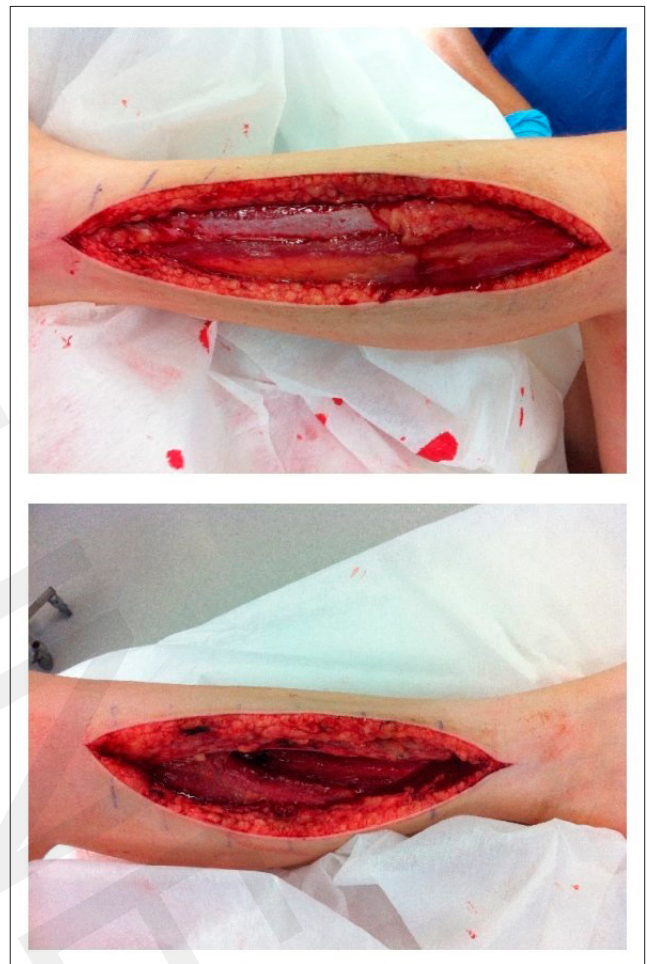

Figure 3. Fasciotomy of the left lower extremity. Upper image – lateral incision, lower image – medial incision [30]

contracture). Impaired arterial circulation leads to muscle necrosis, fibroblast proliferation, scarring and formation of adhesions that cause contracture, and pulling of the fingers of the affected extremity. Depending on the volume of ischemic muscles and contracted fingers, the syndrome can take mild, moderate or severe forms. In addition to standard blood tests and ICP measurement, ultrasound is useful in diagnosis to differentiate Volkmann's contracture from ACS. Treatment depends on severity. The mild form can be treated with physical therapy and splints, while the severe form often requires tendon or whole muscle grafts [47]. Quick diagnosis and intervention are essential. Severe consequences can be avoided if short term fasciotomy (up to 4h) is performed before Volkmann's contracture develops.

CECS – chronic exertional compartment syndrome. A chronic variant of CS which, like ACS, more frequently affects the lower extremities and occurs after intense exercise; the group most susceptible to developing the condition are runners. Symptoms reported by patients include pain, paresthasias and numbness in the affected part of the body, but more severe symptoms, such as pulseless or tissue paralysis (characteristic in ACS), do not occur. Patients most commonly report the onset and progression of symptoms already during exercise and their relief within minutes to hours after stopping exercise. The diagnosis of CECS is based on measurement of ICP. Diagnostic criteria have been

proposed to help diagnose the condition: ICP \geq 15mmHg before exercise, ICP \geq 30mmHg after the first minute of exercise, or ICP \geq 20 mmHg after 5 minutes of exercise.

Treatment of CECS begins with non-operative management. Numerous methods have been proposed, such as discontinuation of weight-bearing activities, changing the type of walking and running pattern to forefoot striking, massage, kinesiotaping, chemodenervation, ultrasound-guided fascial fenestration or injection of botulinum toxin A [35,36]. However, these methods have a limited role in the treatment of CECS due to the frequent recurrence of the condition or side-effects, including loss of muscle strength after botulinum toxin A [37]. Surgical fasciotomy, often performed with minimally invasive techniques in the case of CECS, also appears to obtain the best results, as the method of choice for ASC [41].

CONCLUSIONS

- 1) Compartment syndrome is an emergency condition requiring urgent diagnosis and immediate implementation of appropriate therapy.
- 2) The condition can result from various causes (trauma, burns, coagulation disorders), but the most common cause is a tibial fracture.
- 3) It is important to consider the possibility of iatrogenic CS (too tight dressings) and preventing it.
- 4) The most important parameter for the diagnosis of compartment syndrome is ICP, being $>$ 30mmHg when the condition is present.
- 5) Chronic compartment syndrome, unlike acute compartment syndrome, does not require urgent surgery but it is also a condition that requires increased attention.
- 6) Fasciotomy is the procedure of choice for compartment syndrome, and its short term implementation can avoid severe complications like Volkmann's ischemic contracture.

REFERENCES

1. Via AG, Oliva F, Spoliti M, et al. Acute compartment syndrome. *Muscles Ligaments Tendons J.* 2015;5(1):18–22.
2. Garner MR, Taylor SA, Gausden E, et al. Compartment syndrome: diagnosis, management, and unique concerns in the twenty-first century. *HSS J.* 2014;10(2):143–152. <https://doi.org/10.1007/s11420-014-9386-8>.
3. van der Kraats AM, Winkes M, Janzing HMJ, et al. Review of Reliable and Valid Noninvasive Tools for the Diagnosis of Chronic Exertional Compartment Syndrome. *Orthop J Sports Med.* 2023;11(1). <https://doi.org/10.1177/23259671221145151>
4. Guo J, Yin Y, Jin L, et al. Acute compartment syndrome: Cause, diagnosis, and new viewpoint. *Medicine (Baltimore).* 2019;98(27):e16260. <https://doi.org/10.1097/MD.00000000000016260>
5. von Volkmann R. Ischaemic muscle paralyses and contractures. 1881. *Clin Orthop Relat Res.* 2007;456:20–21. <https://doi.org/10.1097/BLO.0b013e318032561f>
6. Torlincasi AM, Lopez RA, Waseem M. Acute Compartment Syndrome. In: *StatPearls. Treasure Island (FL): StatPearls Publishing LLC* 2022.
7. Taylor RM, Sullivan MP, Mehta S. Acute compartment syndrome: obtaining diagnosis, providing treatment, and minimizing medicolegal risk. *Curr Rev Musculoskelet Med.* 2012;5(3):206–213. <https://doi.org/10.1007/s12178-012-9126-y>
8. Jones G, Thompson K, Johnson M. Acute compartment syndrome after minor trauma in a patient with undiagnosed mild haemophilia B. *Lancet.* 2013;382(9905):1678. [https://doi.org/10.1016/S0140-6736\(13\)61954-6](https://doi.org/10.1016/S0140-6736(13)61954-6)
9. Amado FC, Noversa C, Moura A, et al. Necrotizing Fasciitis Causing Acute Compartment Syndrome after Radial Artery Catheterization. *Eur J Case Rep Intern Med.* 2020;7(4). https://doi.org/10.12890/2020_001525
10. Edigin E, Shaka H. Idiopathic Acute Compartment Syndrome of the Leg with Incidental Deep Venous Thrombosis: A Case Report. *Cureus.* 2019;11(7):e5130. <https://doi.org/10.7759/cureus.5130>
11. Lutter C, Schöffel V, Hotfiel T, et al. Compartment Syndrome of the Foot: An Evidence-Based Review. *J Foot Ankle Surg.* 2019;58(4):632–640. <https://doi.org/10.1053/j.jfas.2018.12.026>
12. Ilyas H, Fagan C, Roser F, et al. Lumbar Paraspinal Compartment Syndrome: Case Report and Critical Evaluation of the Literature. *Clin Spine Surg.* 2022;35(7):301–309. <https://doi.org/10.1097/BSD.0000000000001254>
13. Marin AC, Hechter S, Prasad A, et al. Abdominal Compartment Syndrome (ACS) With Sigmoid Volvulus (SV): Lost Hours Are Lost Lives. *Cureus.* 2023;15(1):e33741. <https://doi.org/10.7759/cureus.33741>
14. Bennis M, Miller K, Harbrecht B, et al. Heroin-Related Compartment Syndrome: An Increasing Problem for Acute Care Surgeons. *Am Surg.* 2017;83(9):962–965.
15. Tiwari A, Haq AI, Myint F, et al. Acute compartment syndromes. *Br J Surg.* 2002;89(4):397–412. <https://doi.org/10.1046/j.0007-1323.2002.02063.x>
16. Novak M, Penhaker M, Raska P, et al. Extremity compartment syndrome: A review with a focus on non-invasive methods of diagnosis. *Front Bioeng Biotechnol.* 2022;10:801586. <https://doi.org/10.3389/fbioe.2022.801586>
17. Turner J, Thies KC. Intra-osseous-access-associated lower limb compartment syndrome in a critically injured paediatric patient. *Eur J Anaesthesiol.* 2018;35(12):981–983. <https://doi.org/10.1097/EJA.0000000000000873>
18. Bochenek A, Reicher M. *Anatomia Człowieka. Vol I.* Warszawa: PZWL; 2019. p. 911–913.
19. Mostafa E, Graefe SB, Varacallo M. Anatomy, Bony Pelvis and Lower Limb, Leg Posterior Compartment. In: *StatPearls. Treasure Island (FL): StatPearls Publishing LLC*; 2022.
20. Wilke J, Schleip R, Yucesoy CA, et al. Not merely a protective packing organ? A review of fascia and its force transmission capacity. *J Appl Physiol.* 1985. 2018;124(1):234–244. <https://doi.org/doi:10.1152/jappphysiol.00565.2017>
21. Benjamin M. The fascia of the limbs and back—a review. *J Anat.* 2009;214(1):1–18. <https://doi.org/10.1111/j.1469-7580.2008.01011.x>
22. Oliver JD. Acute Traumatic Compartment Syndrome of the Forearm: Literature Review and Unfavorable Outcomes Risk Analysis of Fasciotomy Treatment. *Plast Surg Nurs.* 2019;39(1):10–13. <https://doi.org/10.1097/PSN.0000000000000255>
23. Schellenberg M, Chong V, Cone J, et al. Extremity compartment syndrome. *Curr Probl Surg.* 2018;55(7):256–273. <https://doi.org/10.1067/j.cpsurg.2018.08.002>
24. McMillan TE, Gardner WT, Schmidt AH, et al. Diagnosing acute compartment syndrome—where have we got to? *Int Orthop.* 2019;43(11):2429–2435. <https://doi.org/10.1007/s00264-019-04386-y>
25. Cone J, Inaba K. Lower extremity compartment syndrome. *Trauma Surg Acute Care Open.* 2017;2(1). <https://doi.org/10.1136/tsaco-2017-000094>
26. A comparison of pressure measurement devices used in the acute compartment syndrome of the limbs – Scientific Figure on ResearchGate. www.researchgate.net/figure/Measurement-technique-using-the-Stryker-intracompartmental-pressure-monitors-system-A_fig2_281242191 (access: 2023.03.31).
27. McQueen MM, Duckworth AD. The diagnosis of acute compartment syndrome: a review. *Eur J Trauma Emerg Surg.* 2014;40(5):521–528. <https://doi.org/10.1007/s00068-014-0414-7>
28. Coccolini F, Improta M, Picetti E, et al. Timing of surgical intervention for compartment syndrome in different body region: systematic review of the literature. *World J Emerg Surg.* 2020;15(1):60. <https://doi.org/10.1186/s13017-020-00339-8>
29. Ellison CE, Zollinger RM. *Zollinger Atlas Zabiegów Chirurgicznych.* Wrocław: Edra Urban & Partner; 2019. p. 638–639.
30. Lower Leg Compartment Syndrome after Appendicectomy. www.hindawi.com/journals/crior/2015/585986 (access: 2023.03.31).
31. Jeong JG, Choi SH, Kim AR, et al. Gluteal Compartment Syndrome and Rhabdomyolysis after Prolonged Laparoscopic Nephroureterectomy and Treatment Strategies Including Rehabilitation: A Case Report. *Healthcare (Basel).* 2021;10(1):47. <https://doi.org/10.3390/healthcare10010047>
32. Tsai WH, Huang ST, Liu WC, et al. High risk of rhabdomyolysis and acute kidney injury after traumatic limb compartment syndrome. *Ann Plast Surg.* 2015;74(2):158–161. <https://doi.org/10.1097/SAP.0000000000000460>
33. Lollo L, Grabinsky A. Clinical and functional outcomes of acute lower extremity compartment syndrome at a Major Trauma Hospital. *Int J Crit Illn Inj Sci.* 2016;6(3):133–142. <https://doi.org/10.4103/2229-5151.190648>

34. Wang T, Long Y, Ma L, et al. Single-cell RNA-seq reveals cellular heterogeneity from deep fascia in patients with acute compartment syndrome. *Front Immunol.* 2023;13. <https://doi.org/10.3389/fimmu.2022.1062479>
35. Buerba RA, Fretes NF, Devana SK, et al. Chronic exertional compartment syndrome: current management strategies. *Open Access J Sports Med.* 2019;10:71–79. <https://doi.org/10.2147/OAJSM.S168368>
36. Houston A, Cosma G, Turner P, et al. Predicting surgical outcomes for chronic exertional compartment syndrome using a machine learning framework with embedded trust by interrogation strategies. *Sci Rep.* 2021;11(1):24281. <https://doi.org/10.1038/s41598-021-03825-4>
37. Charvin M, Orta C, Davy L, et al. Botulinum Toxin A for Chronic Exertional Compartment Syndrome: A Retrospective Study of 16 Upper- and Lower-Limb Cases. *Clin J Sport Med.* 2022;32(4):436–440. <https://doi.org/10.1097/JSM.0000000000000958>
38. Robles EL, Pache KM, Gluck JS. Acute compartment syndrome of the leg caused by cocaine use, creatine supplementation and vigorous exercise. *J Surg Case Rep.* 2022;2022(11). <https://doi.org/10.1093/jscr/rjac502>
39. AlShammari H, AlDuwaisan W, Akbar Z, et al. Compartment syndrome secondary to intra-operative IV methylene blue extravasation to detect ureteral injury. *Urol Case Rep.* 2023;47:102340. <https://doi.org/10.1016/j.eucr.2023.102340>
40. Chouhan D, Phansopkar P, Chitale NV, et al. Physiotherapy Rehabilitation in an Above-Knee Amputee Following Compartment Syndrome in Post-tibial Plateau Fracture: A Case Report. *Cureus.* 2022;14(12). <https://doi.org/10.7759/cureus.32855>
41. van Zantvoort APM, de Bruijn JA, Hundscheid HPH, et al. Fasciotomy for Lateral Lower-leg Chronic Exertional Compartment Syndrome. *Int J Sports Med.* 2018;39(14):1081–1087. <https://doi.org/10.1055/a-0640-9104>
42. Compartment Syndrome. www.lecturio.com/concepts/compartment-syndrome/ (access: 2023.03.31).
43. Hammerberg EM. Acute compartment syndrome of the extremities. In: UpToDate. Post TW, editor. UpToDate: Waltham (MA): UpToDate Inc. 2023.
44. Ipaktchi K, Wingfield J, Colakoglu S. Fasciotomy: Upper Extremity. In: Mauffrey C, Hak DJ, Martin III MP, editors. *Compartment Syndrome: A Guide to Diagnosis and Management.* Springer; 2019. p. 59–66. https://doi.org/10.1007/978-3-030-22331-1_7
45. Lee DH, Desai MJ, Gauger EM. Electrical Injuries of the Hand and Upper Extremity. *J Am Acad Orthop Surg.* 2019;27(1):e1–e8. <https://doi.org/10.5435/JAAOS-D-17-00833>
46. Merchan N, Ingalls B, Garcia J, et al. Factors Associated With Surgical Site Infections After Fasciotomy in Patients With Compartment Syndrome. *J Am Acad Orthop Surg Glob Res Rev.* 2022;6(2):e22.00002. <https://doi.org/10.5435/JAAOSGlobal-D-22-00002>
47. Mirza TM, Taqi M. Volkmann Contracture. In: StatPearls. Treasure Island (FL): StatPearls Publishing LLC 2022.