



# Delayed HIV diagnosis of patients due to the COVID-19 pandemic

Małgorzata Sierpień<sup>1,A-B,F</sup>, Anna Sobstyl<sup>1,A,D,F</sup>, Natalia Sergiel<sup>1,B-C</sup>, Dominika Górską<sup>1,D</sup>, Justyna Stempkowska-Rejek<sup>1,E</sup>, Krzysztof Tomaszewicz<sup>1,E-F</sup>

<sup>1</sup> Department of Infectious Diseases, Medical University, Lublin, Poland

A – Research concept and design, B – Collection and/or assembly of data, C – Data analysis and interpretation, D – Writing the article, E – Critical revision of the article, F – Final approval of the article

Sierpień M, Sobstyl A, Sergiel N, Górską D, Stempkowska-Rejek J, Tomaszewicz K. Delayed HIV diagnosis of patients due to COVID-19 pandemic. *J Pre-Clin Clin Res.* 2022; 16(2): 42–44. doi: 10.26444/jpccr/150518

## Abstract

**Introduction.** The AIDS disease epidemic is still a global problem. To date, finding the connection between HIV and SARS-CoV-2 infection is very significant.

**Case Report.** A 51-year-old woman was admitted to the Neurology Department due to neurological symptoms lasting for 1.5 months. Imaging examinations of the CNS, chest CT and cerebrospinal fluid examination revealed significant abnormalities. Tests for HIV and SARS-CoV-2 were both positive. *Klebsiella pneumoniae* ESBL+ was detected in rectal swab as well as findings of *Candida* antigens and antibodies of *Cryptococcus neoformans* mycosis in serum. Due to these results, appropriate treatment was implemented but with a time delay which resulted in the death of the patient.

**Conclusion.** HIV infection may be associated with an increased risk of severe SARS-CoV-2 infection causing an increase in mortality rate during the COVID-19 pandemic. Confirmation and early detection of HIV infection permits early and accurate diagnosis and faster treatment decisions.

## Key words

COVID-19, *Cryptococcus neoformans* mycosis, delayed HIV diagnosis

## INTRODUCTION

AIDS (Acquired Immunodeficiency Syndrome) is caused by HIV (Human Immunodeficiency Virus). The first cases of AIDS were recorded in 1981 [1]. According to UNAIDS (United Nations Programme on HIV/AIDS), in 2020, there were approximately 37.7 million people living with HIV worldwide [2]. So far, an effective vaccine to prevent the disease has not been developed. Currently, antiretroviral drugs (ART) are used, which are able to inhibit viral replication, this can improve the patient's prognosis and quality of life, and may be used at an early stage of the infection. Delayed ART use associated with a late disease course may result in hospitalization for concomitant opportunistic infections [3]. Delayed diagnosis of HIV is diagnosed with a CD4 cell count <350/μl or an AIDS-defining event without regard to the CD4 cell count. Advanced HIV infection is diagnosed when the CD4 cell count is less than 200 cells / μl or an AIDS-defining event at the first control test [4].

The COVID-19 pandemic caused a negative impact of diagnosis and proper onset of pharmacological HIV treatment. A study by Kowalska JD et al. showed that HIV clinics in Central and Eastern Europe were functioning normally in only about 30% of the countries [5]. The study estimated that 19% of HIV-infected patients were unable to receive antiretroviral drugs as a result of the pandemic [6]. Due to the COVID-19 pandemic, HIV diagnosis and treatment were often delayed [2]. Initial diagnosis of HIV which occurs on time is essential in order to start treatment

early and prevent further progression of the disease [7]. The presence of indicator diseases of AIDS should force HIV test. A great deal of data from randomized, controlled trials confirm the consequences of not treating HIV positive people with AIDS related diseases, which are presented below [8, 9,10].

## CASE REPORT

A 51-year-old woman was reported to the Emergency Department with the following symptoms: weakness, dizziness, pain in the lumbar and sacral spine, abnormal gout, and fever. Due to neurological symptoms that lasted for 1.5 months, she was admitted to the Department of Neurology. During the admission, the *patient's* Glasgow Coma Scale score was 15 (GCS 15). Meningeal symptoms, sensory disturbances, ataxia and paresis were absent. Laboratory tests showed several abnormalities (Tab.2). Imaging examinations of the central nervous system, spine and chest were performed which showed numerous small foci of ischemic strokes in CNS, most likely embolic, with a predominance on the right side. CT of the spine showed disc protrusion at the L5-S1 level. Chest CT showed an area of consolidation in the right lung and fluid on both sides of the chest. Cerebrospinal fluid examination performed on the 5<sup>th</sup> day of hospitalization revealed the following abnormalities: incomplete transparency, increased pleocytosis (28 cells/μl), increased protein level (175 mg/dl), and decreased glucose level (1.5 mg/dl). Antigen tests for the most common etiological factors of meningitis, such as *S. pneumoniae*, *N. meningitidis*, *H. influenzae*, and cerebrospinal fluid culture were negative. The results of microbiological tests for tuberculosis, syphilis, Lyme disease and COVID-19 were negative.

Address for correspondence: Anna Sobstyl, Department of Infectious Diseases, Medical University, Lublin, Poland  
e-mail: sobstyl.anna@onet.pl

Received: 23.04.2022; accepted: 30.05.2022; first published: 13.06.2022

**Table 1.** Examples of indicator diseases

Respiratory	Pneumonia, recurrent ( $\geq 2$ or more episodes in 12 months) <sup>1</sup> Tuberculosis pneumocystis <sup>1</sup> Histoplasmosis, disseminated/ extra pulmonary <sup>1</sup> Candidiasis, bronchial/lungs <sup>1</sup> Mycobacterium avium complex (MAC) or Mycobacterium kansasii, disseminated or extrapulmonary <sup>1</sup> Herpes simplex <sup>1</sup> bronchitis/pneumonitis <sup>1</sup> Bacterial pneumonia aspergillosis <sup>2</sup>	Neurology	Cerebral toxoplasmosis <sup>1</sup> Cryptococcal meningitis <sup>1</sup> Primary cerebral lymphoma <sup>1</sup> Progressive multifocal leukoencephalopathy <sup>1</sup> Dementia <sup>2</sup> Aseptic meningitis or encephalitis <sup>2</sup> Guillain-Barré syndrome <sup>2</sup> Leucoencephalopathy <sup>2</sup> Peripheral neuropathy <sup>2</sup> Cerebral abscess <sup>2</sup> Space occupying lesion of unknown cause <sup>2</sup> Transverse myelitis <sup>2</sup>
Oncology and Haematology	Non-Hodgkin lymphoma <sup>1</sup> Lung cancer <sup>2</sup> Malignant lymphoma <sup>2</sup> Anal cancer or anal intraepithelial dysplasia <sup>2</sup> Seminoma Head and neck cancer <sup>2</sup> Castleman's disease <sup>2</sup> Unexplained leukocytopenia/thrombocytopenia lasting >4 weeks <sup>2</sup>	Dermatology/ Dermatovenerology	Kaposi's sarcoma <sup>1</sup> Herpes simplex ulcer(s) <sup>1</sup> Severe or recalcitrant seborrhoeic dermatitis <sup>2</sup> Severe or recalcitrant psoriasis <sup>2</sup> Multidermatomal or recurrent herpes zoster <sup>2</sup> Candidiasis <sup>2</sup>
Gastroenterology	Cryptosporidiosis diarrhoea, > 1 month <sup>1</sup> Candidiasis, oesophageal <sup>1</sup> Hepatitis B or C infection <sup>2</sup> Oral candidiasis <sup>2</sup> Oral hairy leukoplakia <sup>2</sup> Chronic diarrhoea of unknown cause <sup>2</sup> Salmonella, Shigella or Campylobacter enteritis <sup>2</sup> Weight loss of unknown cause <sup>2</sup>	Ophthalmology	Cytomegalovirus retinitis <sup>1</sup> Any unexplained retinopathy <sup>2</sup> Infective retinal diseases including herpes viruses and toxoplasma <sup>2</sup>
Ear, nose and throat	Candidiasis tracheal/oesophageal <sup>1</sup> Lymphoepithelial parotid cysts <sup>2</sup> Lymphadenopathy of unknown cause <sup>2</sup> Mononucleosis-like illness <sup>2</sup> Chronic parotitis <sup>2</sup>	Gynaecology	Cervical cancer <sup>1</sup> Cervical intraepithelial neoplasia (grade II or above) <sup>2</sup> Vaginal intraepithelial neoplasia <sup>2</sup>
		Other	Any lymphadenopathy of unknown cause <sup>2</sup> Mononucleosis-like syndrome (primary HIV infection) <sup>2</sup> Pyrexia of unknown origin <sup>2</sup> Any sexually-transmitted infection <sup>2</sup>

<sup>1</sup> AIDS-defining conditions<sup>2</sup> Other conditions in which HIV testing is strongly recommend

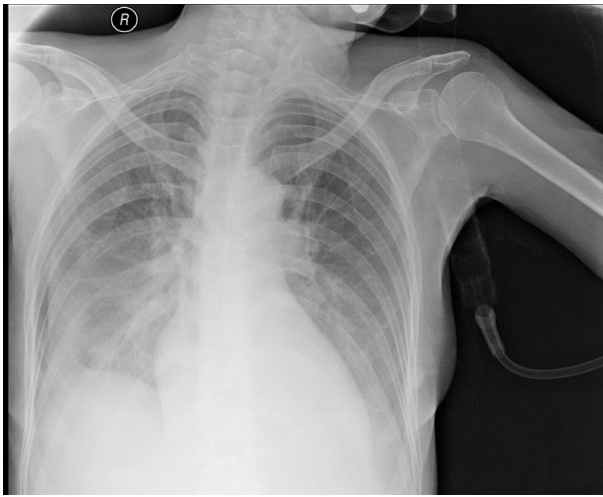
The patient's condition deteriorated on the 12<sup>th</sup> day of hospitalization. The patient was conscious but without verbal contact, opened her eyes in response to pain (GCS 7), meningeal symptoms were positive. Due to the serious worsening of the patient's condition and the detection of the COVID-19 outbreak, the test for SARS-CoV-2 infection was repeated. The presence of SARS-CoV-2 RNA was confirmed through a nasopharyngeal swab. The patient was transferred to a unit dedicated for patients infected with SARS-CoV-2. Test for HIV infection was performed, which proved positive. The CD4 cell count was 13 cells/ $\mu$ l.

On the 19<sup>th</sup> day of hospitalization, the patient was transferred to the Department of Infectious Diseases. She was unconscious (GCS 6), with positive meningeal symptoms, paralysis of cranial nerves and fever up to 40°C. A chest X-ray result was similar to the previous one (Fig. 1). Laboratory test showed inflammatory parameters enhancement and exacerbation of anaemia (Tab.2). The following examinations were then performed: blood cultures, blood cultures for mycobacteria, rectal swab culture, testing for the presence of *Aspergillus* and *Candida* antigens in the serum, HCV, HBV, CMV and *Toxoplasma gondii* tests. *Klebsiella pneumoniae* ESBL + (Extended-spectrum  $\beta$ -lactamase) was detected in rectal swab culture. The presence of *Candida* antigens in the serum was confirmed, as well as the presence of IgG anti-CMV and anti-*Toxoplasma gondii* antibodies. The remaining tests gave negative results. Due to late-stage HIV infection, the differential diagnosis included AIDS-related dementia, CNS toxoplasmosis, progressive multifocal leukoencephalopathy, CNS lymphoma, CNS tuberculosis and CNS mycosis. The

**Table 2.** Laboratory tests results

	ON ADMISSION	19TH DAY OF HOSPITALIZATION
CRP	17,2 mg/l	177.7 mg/l
PCT	0.03 ng/ml	0.27 ng/ml
WBC	4.5 K/ $\mu$ l	3.69 K/ $\mu$ l
NEU	2.1 K/ $\mu$ l	3.03 K/ $\mu$ l
PLT	179 K/ $\mu$ l	292 K/ $\mu$ l
HGB	8.9 g/dl	7.7 g/dl
CREATININ	0,36 mg/dl	0,27 mg/dl
AST	13 IU/L	53.9 IU/L
ALT	14 IU/L	73.8 IU/L
D-DIMERS	5,432 ng/ml	6,011 ng/ml
IL-6	250 pg/ml	377.9 pg/ml
FERRITIN	200 $\mu$ g/l	831.1 $\mu$ g/l

clinical picture and the results of the examinations raised the suspicion of CNS mycosis. *Cryptococcus neoformans* was found in the CSF and in the blood. Based on the results of clinical examination, treatment with amphotericin B, flucytosine, meropenem, co-trimoxazole and symptomatic treatment was initiated. As a result of increasing respiratory failure, the patient died after 35 days of hospitalization.



**Figure 1.** Chest x-ray performed after transmission to the department of infectious disease

## DISCUSSION

The presented case should emphasize the importance of early diagnosis of HIV infection in COVID-19 patients in order to accelerate initiation of causative treatment, and therefore to decrease mortality rates. Detection of the human immunodeficiency virus should narrow down the possible opportunistic infections, such as *Candidiasis* or *Pneumonia*. Furthermore, opportunistic infections involving lung diseases and central nervous system infections with early diagnosis and specific treatment initiation proceed with better prognosis [11,12].

Although several studies have been conducted analyzing HIV and SARS-CoV-2 co-infection, it remains unclear whether patients with HIV are at higher risk of COVID-19 infection, or with the controversial suggestion that they could be protected from severe COVID-19 due to antiretroviral therapy or their immunosuppression [6,13].

However, most of the published studies imply that there is no significant correlation between HIV and SARS-CoV-2 infections. Antiretroviral treated HIV patients have approximately the same chances of recovery from COVID-19 compared to non-HIV patients, but are not immune to COVID-19 or severity of the disease. In addition, their immunosuppression might increase the risk of COVID-19 severity [6, 14].

Nonetheless, one of the systemic reviews and a meta-analysis maintain that HIV infection has negative influence on COVID-19 patients, and lead to much higher mortality among COVID-19 patients without prior HIV infection. [15].

Consequently 'late presenters' with delayed diagnosis of HIV infection have higher risk of severe COVID-19, hospitalization and death.

*Cryptococcus neoformans* infection is the most common etiological factor of CNS mycosis among HIV+ individuals. As in the presented case, cryptococcosis is mostly responsible for establishing severe clinical presentation in the CNS and lungs. Cryptococcosis often concerns patients with severe deficit of cellular immunity and HIV-positive patients [16].

## CONCLUSION

Due to the presented clinical case, attention should be paid to early detection and treatment of HIV infection. Confirmation of HIV infection permits taking diagnostics focused on diseases characteristic for infected people. During a pandemic, it is especially important to maintain the continuation of HIV treatment due to the negative consequences of its neglect [17]. Another important aspect is the prevention of SARS-CoV-2 infection among immunosuppressed people, such as those with HIV. Despite numerous research studies about the impact of HIV infection on the course of COVID-19, there are still questions without unambiguous answers. This highlights the need to deepen knowledge on this topic by conducting further researches.

## REFERENCES

- Gazzard B. AIDS. *Baillieres Clin Gastroenterol.* 1987;1(3):567–587. [https://doi.org/10.1016/0950-3528\(87\)90048-0](https://doi.org/10.1016/0950-3528(87)90048-0).
- UNAIDS report shows that people living with HIV face a double jeopardy, HIV and COVID-19, while key populations and children continue to be left behind in access to HIV services. [https://www.unaids.org/en/resources/presscentre/pressreleaseandstatementarchive/2021/july/20210714\\_global-aids-update](https://www.unaids.org/en/resources/presscentre/pressreleaseandstatementarchive/2021/july/20210714_global-aids-update) (access: 2021.07.19).
- Lehmann C, Malin J, Suárez I, et al. Moderne HIV-Therapie. *Internist.* 2019;60(4):411–419. <https://doi.org/10.1007/s00108-019-0564-0>
- Wójcik-Cichy K, Jablonowska O, Piekarska A, et al. The high incidence of late presenters for HIV/AIDS infection in the Lodz province, Poland in the years 2009–2016: we are still far from the UNAIDS 90% target. *AIDS Care.* 2018;30(12):1538–1541. <https://doi.org/10.1080/09540121.2018.1470306>
- Kowalska JD, Skrzat-Klapaczynska A, Bursa D, et al. HIV care in times of the COVID-19 crisis — Where are we now in Central and Eastern Europe? *Int J Infect Dis.* 2020;96:311–314. <https://doi.org/10.1016/j.ijid.2020.05.013>
- Kanwugu ON, Adadi P. HIV/SARS-CoV-2 coinfection: A global perspective. *J Med Virol.* 2020;10.1002/jmv.26321. <https://doi.org/10.1002/jmv.26321>
- Kendall CE, Shoemaker ES, Raboud J, et al. Assessing Timely Presentation to Care Among People Diagnosed with HIV During Hospital Admission: A Population-Based Study in Ontario, Canada. *AIDS Behav.* 2018;22(8):2575–2583. <https://doi.org/10.1007/s10461-018-2063-z>
- Raben D, Sullivan AK, Mocroft A, et al. Improving the evidence for indicator condition guided HIV testing in Europe: Results from the HIDES II Study – 2012 – 2015. *PLoS ONE.* 2019;14(8):e0220108. <https://doi.org/10.1371/journal.pone.0220108>
- Bull L, Rayment M. HIV-indicator-condition-driven HIV testing: clinically effective but still rarely implemented. *Clin Med.* 2016;16(2):175–179. <https://doi.org/10.7861/clinmedicine.16-2-175>
- Ahee A van, Combs K, Delpech V, et al. Public Health Guidance on HIV, Hepatitis B and C Testing in the EU/EEA: An Integrated Approach; 2018. <http://dx.publications.europa.eu/10.2900/79127>. (access 2021.07.19).
- Thakur KT. CNS infections in HIV. *Curr Opin Infect Dis.* 2020;33(3):267–272. <https://doi.org/10.1097/QCO.0000000000000652>
- Cribbs SK, Crothers K, Morris A. Pathogenesis of HIV-Related Lung Disease: Immunity, Infection, and Inflammation. *Physiol Rev.* 2020;100(2):603–632. <https://doi.org/10.1152/physrev.00039.2018>
- Joob B, Wiwanitkit V. SARS-CoV-2 and HIV. *J Med Virol.* March 2020;10.1002/jmv.25782. <https://doi.org/10.1002/jmv.25782>
- Baluku JB, Mwebaza S, Ingabire G, et al. HIV and SARS-CoV-2 coinfection: A case report from Uganda. *J Med Virol.* 2020;10.1002/jmv.26044. <https://doi.org/10.1002/jmv.26044>
- Ssentongo P, Heilbrunn ES, Ssentongo AE, et al. Epidemiology and outcomes of COVID-19 in HIV-infected individuals: a systematic review and meta-analysis. *Sci Rep.* 2021;11:6283. <https://doi.org/10.1038/s41598-021-85359-3>
- Maziarz EK, Perfect JR. Cryptococcosis. *Infect Dis Clin North Am.* 2016;30(1):179–206. <https://doi.org/10.1016/j.idc.2015.10.006>
- Huang J, Xie N, Hu X, et al. Epidemiological, virological and serological features of COVID-19 cases in people living with HIV in Wuhan City: A population-based cohort study. *Clin Infect Dis Off Publ Infect Dis Soc Am.* 2020;ciaa1186. <https://doi.org/10.1093/cid/ciaa1186>