



Gullo's Syndrome – case report

Anna Rycyk^{1,C-D}, Paulina Furtak^{2,B}, Agnieszka Mądro^{1,A}, Beata Kasztelan-Szczerbińska^{1,E}, Halina Cichoż-Lach^{1,F}

¹ Department of Gastroenterology with Endoscopy Unit, Medical University, Lublin, Poland

² Gastroenterology Unit, Independent Public Teaching Hospital No. 4, Lublin, Poland

A – Research concept and design, B – Collection and/or assembly of data, C – Data analysis and interpretation, D – Writing the article, E – Critical revision of the article, F – Final approval of article

Rycyk A, Furtak P, Mądro A, Kasztelan-Szczerbińska B, Cichoż-Lach H. Gullo's Syndrome: case report. J Pre-Clin Clin Res. doi: 10.26444/jpccr/127792

Abstract

Benign pancreatic hyperenzymemia (BPH) or Gullo's Syndrome is a persistent elevation of pancreatic enzymes activity, observed for at least one year, with no pancreatic disorder. This diagnosis is extremely important because it allows us to avoid many unnecessary examinations performed during the diagnostic process. We present a case of a 25-year-old man who was admitted for recurrent elevated lipase and amylase serum values over a time period of 2 years who presented with non-specific abdominal complaints. Interestingly, his routine tests showed sustained elevated serum amylase and lipase activity. He was intensively diagnosed due to pancreatic hyperenzymemia, but no pancreatic disease was detected. The observation lasted two years. The serum lipase and serum amylase levels continued to increase after that time. This diagnosis requires attention because BPH can be the first symptom of pancreatic cancer.

Keywords

amylase, lipase, Gullo's Syndrome, benign pancreatic hyperenzymemia (BPH), elevated pancreatic enzyme activity, pancreatic hyperenzymemia, pancreatic enzymes (PE)

INTRODUCTION

Benign pancreatic hyperenzymemia (BPH) is a condition which appears as a persistent increase in the serum pancreatic enzymes (PE), amylase and lipase. However, no pancreatic disease is detected [1, 2]. It is crucial that this is recognized although it is very difficult to do because the diagnosis is one of the exclusion of other causes of pancreatic hyperenzymemia. There are many conditions which can lead to elevated pancreatic enzymes levels, such as inflammatory bowel disease, renal insufficiency, diabetes mellitus, acute cholecystitis, ectopic pregnancy, liver diseases, and infections [3, 4]. The most common diseases which are manifested as an elevation of PE are pancreatic neoplasms or acute pancreatitis [5], first described by an Italian gastroenterologist Gullo who later published many articles on the condition and remained the main pioneer of BPH, called Gullo's Syndrome [1, 3].

CASE REPORT

We present a case of a 25-year-old man who was admitted to the Department of Gastroenterology due to recurrent elevation in lipase and amylase serum values over a time period of two years, and non-specific abdominal complaints. He presented with epigastric pain without nausea or vomiting. He was treated for left inguinal hernia. There was no familial history of pancreatic hyperenzymemia or other relevant diseases. Physical examination revealed no abnormalities, and the patient denied any weight loss. During the last two years, the serum lipase activity reached 1,150 U/L (normal values range <53), and amylase raised to 385 U/L (normal

Table 1. Laboratory tests for diagnosing patients with Gullo's Syndrome

Laboratory test	Result	Normal range
Total cholesterol	141 mg/dl	100–199 mg/dl
Lipoprotein cholesterol	79 mg/dl	0–99 mg/dl
Triglycerides	131 mg/dl	0–149 mg/dl
IgG4	0.48 g/L	<1.35 g/L
Parathormon	33 pg/ml	10–60 pg/ml
Glycosylated hemoglobin	5 %	4–6 %
Glucose	98 mg/dl	70–99 mg/dl
Alanine aminotransferase	16 U/l	<33 U/l
Aspartate aminotransferase	24 U/l	<32 U/l
Alkaline phosphatase	75 U/l	27–90 U/l
Total bilirubin	0.7 mg/dl	0.2–1.2 mg/dl
Anti-tissue transglutaminase antibodies	3.8 U/l	0–20 U/l
C-reactive protein	1.3 mg/l	0–3 mg/l
Sodium	145 mmol/L	136–145 mmol/L
Potassium	4.6 mmol/L	3.5–5.1 mmol/L
Calcium	9.2 mg/dl	9.2–10.1 mg/dl

range 30–118) (Fig. 1, Tab. 1). Glucose and glycosylated hemoglobin levels were in the normal range. Serological tests for hepatitis A, B, and C viruses, cytomegalovirus, Epstein-Barr virus, and human immunodeficiency virus (HIV) were negative. Tumour markers, such as carcinoembryonic antigen (CEA), carbohydrate antigen 19–9 (CA19–9), alpha-fetoprotein (AFP), and carbohydrate antigen 125 (CA125), were also within normal range. Genetic tests towards NOD2 (nucleotide-binding oligomerization domain containing 2) were negative. Deregulated NOD2 signalling is claimed to be associated with Crohn's disease while NOD1/2 signaling disturbances are common in many diseases, such as

Address for correspondence: Anna Rycyk, Department of Gastroenterology with Endoscopy Unit, Medical University, Lublin, Poland
E-mail: aniarycyk@op.pl

Received: 20.08.2020; accepted: 24.09.2020; first published: 30.09.2020

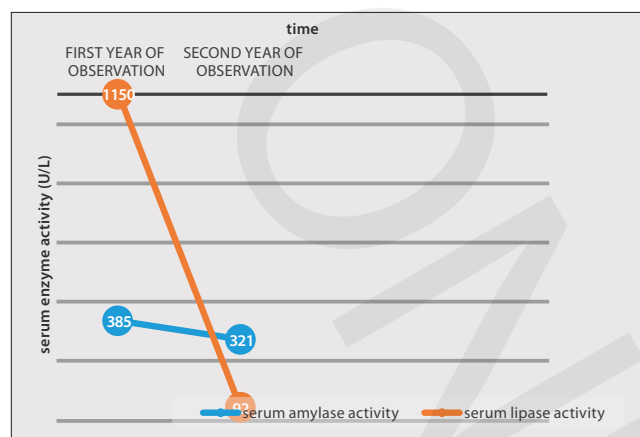


Figure 1. Serum values of amylase and lipase of patient with Gullo's Syndrome during the two years of observation

sarcoidosis, rheumatoid arthritis, solid cancers, uveitis, neuropathic pain, and type 2 diabetes mellitus [6].

Since pancreatic enzymes were significantly raised with no other symptoms, additional diagnostic tests were performed. Abdominal ultrasonography, and computed tomography, as well as magnetic resonance imaging revealed no pancreatic abnormalities. Esophagogastroduodenoscopy showed erosive gastritis which was related to epigastric pain. No other alterations were found. Serum amylase and lipase activity were checked after one year, and were found to be elevated. Serum amylase was 321 IU/L while serum lipase was 92 IU/L (Fig. 1). Control abdominal ultrasonography and computed tomography scanings repeated over time did not show any abnormalities in the abdomen. Ultrasound of the abdomen revealed normal-sized pancreatic head and body, and sub-optimally assessed due to overlaying bowel gas tail. CT of the abdomen detected a normal heterogenous normal-sized pancreas (17.5 × 4 × 2cm) with hyperechogenicity of the parenchyma, negative for pancreatitis. The patient remains under observation.

DISCUSSION

Although the patient presented a perfect example of Gullo's Syndrome, some limitations should be noted. As it is a newly-discovered disease and the consequences of this illness are undocumented, it is not known for how long BPH patients should remain under observation. The authors therefore report that benign pancreatic hyperenzymemia may be the first sign of a pancreatic cancer in 1–2% of patients, according to the medical literature which can appear in the next years, according to the medical literature [1]. The day-to-day fluctuations with transient normalization have been observed in many clinical researches [2]. In some cases (5% of BPH patients), only one of the PE, amylase or lipase, is elevated [2, 7, 8]. According to the researchers, no matter which enzyme is elevated, it requires further investigation. What is more, the gluten-free diet does not improve test results of amylase and lipase activity. Celiac disease does not seem to have any influence on PE levels [1]. Schnedl et al. have shown that no specific foods have an impact on increased enzyme levels [4]. Drugs taken daily by the patient should always be taken into consideration. For example, the case of a patient with ulcerative colitis and coexisting of BPH

has been described which, however, could be a side-effect of azathioprine treatment [9].

Gullo's Syndrome can appear at almost every age, even in childhood [1]. The ratio of men to women of BPH frequency is 1.5/1 [1, 2]. It is very important to note the patient's history, including family history, in order to recognize either the familiar type of BPH or a sporadic type [5]. The CFTR mutation is observed in Gullo's Syndrome as often as in the healthy population [1]. The PRSS1 and SPINK mutations which are related to the pancreatitis, appear with the same frequency in BPH patients and in healthy people [1]. Unfortunately, the ethiology of Gullo's Syndrome remains unknown [3]. However, it is known that there is a defect in the basolateral surface of the acinar cells that causes the increased secretion of PE into the blood [1, 3, 5]. Di Leo et al. (2016) showed that in patients with chronic asymptomatic pancreatic hyperenzymemia (CAPH), endoscopic ultrasonography (EUS) and secretin – magnetic resonance cholangio-pancreatography (s-MRCP) are both recommended to be performed before Gullo's Syndrome diagnosis [10]. While Vanella et al. (2019) did not find s-MRCP or EUS, which are more costly and invasive, to be more valuable than magnetic resonance cholangio-pancreatography (MRCP), Amodio et al. recommend s-MRCP as an effective diagnostic tool for follow-up in BPH patients [11, 12]. Therefore, it must be borne in mind that expensive tests do not guarantee a proper diagnosis, and performing unnecessary medical procedures should be avoided [13]. The research by Italian scientists who confirm that BPH patients have a quality of life similar to healthy patients seems to be optimistic in determining the proper diagnosis of Gullo's Syndrome [14].

List of abbreviations

BPH – benign pancreatic hyperenzymemia
 PE – pancreatic enzymes
 HIV – human immunodeficiency virus
 CEA – carcinoembryonic antigen
 CA19-9 – carbohydrate antigen 19-9
 AFP – alpha-fetoprotein
 CA125 – carbohydrate antigen 125
 NOD2 – nucleotide-binding oligomerization domain containing 2
 PRSS1 – serine protease 1
 SPINK1 – serine protease inhibitor Kazal-type 1
 CAPH – chronic asymptomatic pancreatic hyperenzymemia
 EUS – endoscopic ultrasonography
 s-MRCP – secretin-magnetic resonance cholangio-pancreatography
 MRCP – magnetic resonance cholangio-pancreatography

Availability of data and materials

All data generated or analyzed during this study are available from the corresponding author on reasonable request.

Competing interests

The authors declare that they have no competing interests.

Funding

No funding was received.

REFERENCES

1. Mehta P, Reddivari AKR. A Case Report of Benign Pancreatic Hyperenzymemia (Gullo's Syndrome). *Cureus*. 2020 May 15; 12(5): e8143.
2. Kumar P, Ghosh A, Tandon V, et al. Gullo's Syndrome: A Case Report. *J Clin Diagn Res*. 2016 Feb; 10(2): OD21-OD22.
3. Ainahi A, Ziane A, Wakrim L, et al. An Unusual Case of Gullo's Syndrome Concomitant with Serious Endometriosis Disease in a Postmenopausal Woman. *Case Rep Med*. 2018; 2018: 6310245.
4. Schnedl WJ, Enko D, Mangge H, et al. Benign pancreatic hyperenzymemia (Gullo syndrome), histamine intolerance, and carbohydrate malabsorption. *Proc (Bayl Univ Med Cent)*. 2017 Apr; 30(2): 177–178.
5. Yang BL, Wu WC, Su CW, et al. Healthy Chinese with benign pancreatic hyperenzymemia. *J Chin Med Assoc*. 2015; 78(10): 623–6.
6. Heim VJ, Stafford CA, Nachbur U. NOD Signaling and Cell Death. *Front Cell Dev Biol*. 2019; 7: 208.
7. Rosell-Camps A, Martínez-Cepas P, Riera-Llodrá JM, et al. Benign Pancreatic Hyperenzymemia, Also Known as Gullo's Syndrome. *Lab Med*. 2019. pii: lzm077.
8. Lionetti E, Francavilla R, Leonardi S, et al. Two rare cases of benign hyperlipasemia in children. *World J Clin Cases*. 2014; 2(1): 16–9.
9. Liverani E, Leonardi F, Castellani L, et al. Asymptomatic and persistent elevation of pancreatic enzymes in an ulcerative colitis patient. *Case Rep Gastrointest Med*. 2013; 2013: 415619.
10. Di Leo M, Petrone MC, Zuppardo RA, et al. Pancreatic morpho-functional imaging as a diagnostic approach for chronic asymptomatic pancreatic hyperenzymemia. *Dig Liver Dis*. 2016; 48(11): 1330–1335.
11. Vanella G, Arcidiacono PG, Capurso G. Chronic Asymptomatic Pancreatic Hyperenzymemia (CAPH): Meta-analysis of pancreatic findings at second-level imaging. *Pancreatol*. 2019; 19(2): 237–244.
12. Amodio A, De Marchi G, Granato A, et al. Chronic Asymptomatic Pancreatic Hyperenzymemia: A Long-term Follow-up. *Pancreas*. 2019; 48(4): 544–547.
13. Catanzaro R, Sciuto M, Adamo G, et al. Benign pancreatic hyperenzymemia-Gullo's syndrome: focus on this clinical challenge. A monocentric retrospective study. *Minerva Med*. 2019 Dec; 110(6): 490–498.
14. Pezzilli R, Brighi N, Calculli L. Quality of life in patients with long-standing chronic non-pathological pancreatic hyperenzymemia. *Pancreatol*. Mar-Apr 2015; 15(2): 131–5.