



Metallic foreign body in the orbit – case report

Jolanta Elżbieta Wojciechowicz^{1,A-F}, Anna Gawęda^{1,A-F}, Mateusz Wachowicz^{1,B-D}, Sara Dweik^{1,C-D}

¹ Department of Maxillofacial Surgery, Medical University, Lublin, Poland

A – Research concept and design, B – Collection and/or assembly of data, C – Data analysis and interpretation,

D – Writing the article, E – Critical revision of the article, F – Final approval of article

Wojciechowicz J, Gawęda A, Wachowicz M, Dweik S. Metallic foreign body in the orbit – case report. J Pre-Clin Clin Res. 2020; 14(1): 11–13. doi: 10.26444/jpccr/118672

Abstract

The presented case report concerns a patient with a foreign body in the orbital cavity – a fishing weight. After performing diagnostic tests, a multidisciplinary procedure was performed to remove the foreign body under general anaesthesia. Ophthalmologic consultation carried out after the procedure showed normal vision of the right and left eye. Penetrating foreign bodies of the orbit due to the variety of shapes and sizes, chemical composition and location, as well as potential serious consequences of such an injury require accurate diagnosis. This starts with determining the pathomechanism of the injury and selecting the appropriate radiological methods, and ends with a multidisciplinary approach to treatment.

Key words

foreign body, orbit, eye injury

INTRODUCTION

Injuries involving the presence of foreign bodies around the orbital area, due to their location and consequences, require the cooperation of doctors of various specialists, including jaw surgeons, ophthalmologists, neurosurgeons, laryngologists, radiologists and psychologists [8, 9]. Such injuries are usually the result of non-compliance with basic health and safety rules, traffic accidents, assaults with sharp tools, or gunshots (1). Due to the type of material they are made of, they can be divided into metallic, non-metallic and organic bodies (2). The most common foreign bodies are larger or smaller fragments of metal, glass shards, wood splinters, and bullets from firearms (1). Small elements can also enter the orbit through closed eyelids, piercing them, which often escapes the patient's attention and sometimes causes further complications (4). The prognosis for this type of injury depends on the location and size of the foreign body, the chemical composition and degree of damage to the surrounding anatomical structures (6). The variety of foreign bodies affects the selection of appropriate radiological diagnostic methods. The most frequently used are: classic radiographs, ultrasound, computer tomography supplemented with angiographic examination, and magnetic resonance imaging [3]. It should be remembered that in classical radiography, metallic bodies distort the image by numerous artifacts. Some of the unknown components of metal and ferro-magnetics make it impossible to safely perform the MR examination [1]. The paper presents the case of a patient with a cylindrical metallic foreign body in the orbit, and the preoperative diagnosis and treatment.

CASE STUDY

A 19-year-old male patient, admitted to Department of Maxillofacial Surgery due to an injury in the right orbital region. He was conscious, and in good general condition. In a medical interview, he reported that while fishing the day before hospitalization, a friend accidentally hit him in the face with a fishing-weight which struck in the area of the upper right eye. The patient was transported by ambulance to the Emergency Department of the Ophthalmology Clinic where an ophthalmological examination was performed, complemented by a Computer Tomography of the facial skull without contrast, and a posterior x-ray of the skull. The patient was referred for further treatment to the Department of Maxillofacial Surgery. Numerous artifacts? resulting from the metallic structure of the foreign body have made it difficult to accurately assess the orbital structures in the CT scan. The description of the study revealed a metallic foreign body with dimensions of 11 × 10 × 31 mm in the right orbit, most likely in the region of the medial straight muscle, placed externally. Both eyeballs were without pathological changes, with smooth strokes. Right optic nerve of preserved continuity? bone structure without perceptible traumatic lesions – incomplete assessment? Clinical examination on the day of admission showed an injury to the upper right eyelid, near the medial angle of the eye, with a clearly visible embedded metallic body. Significant swelling of the upper right eyelid with post-traumatic haematoma. The patient was qualified for team-surgical-ophthalmological surgery to remove the foreign body under general anaesthesia.

The treatment was carried out by applying antibiotic, intravenous – Taromentin 2 × 1.2 g and Oftaquix drops to the eye. The foreign body was removed through the wound without additional surgical accesses, the wound was revised, and a rubber drain installed, which was removed the following day. A control sinus of the lateral nasal sinuses was performed.

An ophthalmological consultation carried out 4 days after the surgical procedure showed normal vision of both the right and left eyes, without the features of splitting? and a slight fall of the upper eyelid of the right eye. The front

Address for correspondence: Jolanta Wojciechowicz, Department of Maxillofacial Surgery, Medical University, Staszica 11, 20-081 Lublin, Poland
E-mail: lanyfztk@wp.pl

Received: 03.11.2019; accepted: 03.03.2020; first published: 31.03.2020

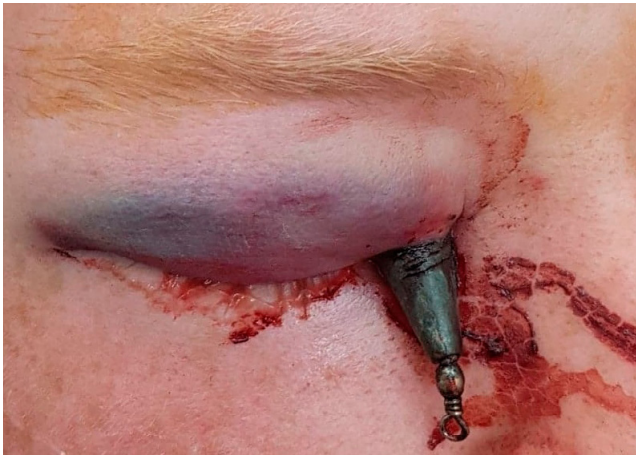

Figure 1. Patient after admission to the Maxillofacial Clinic. Foreign body visible

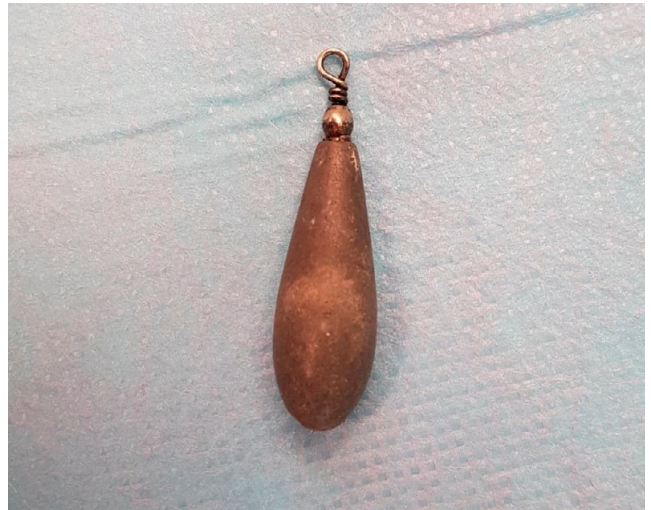

Figure 4. Removed foreign body – fishing weight

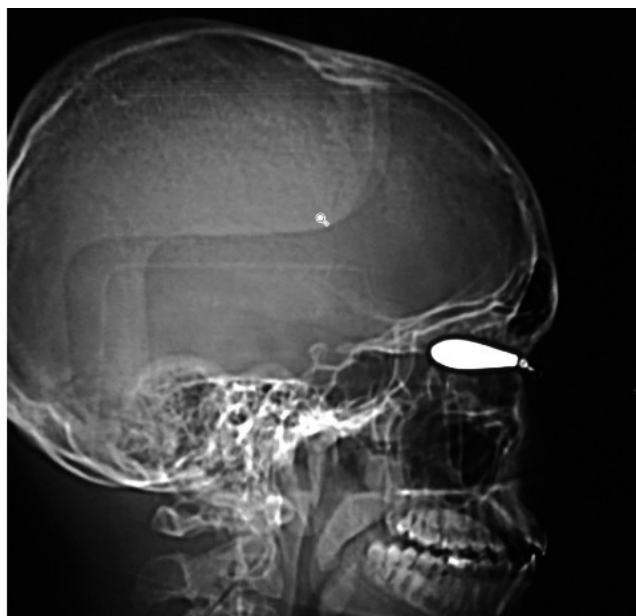


Figure 2. Lateral X-ray of skull. Foreign body visible in the orbital projection

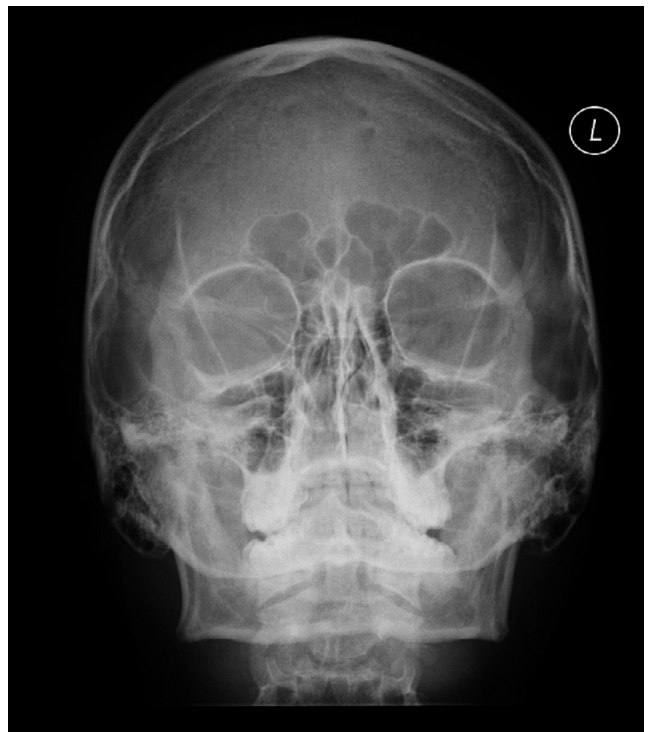

Figure 5. X-ray control of nasal sinuses after removal of the foreign body

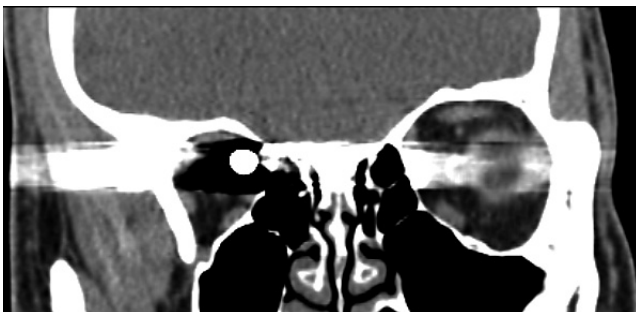


Figure 3. CT – frontal projection. Rear of the foreign body visible

section and fundus of the eyewear correct. The patient was discharged home in a generally good condition, with the recommendation of control a check-up on the ophthalmic and maxillofacial surgery, as well as continuation of antibiotic therapy.

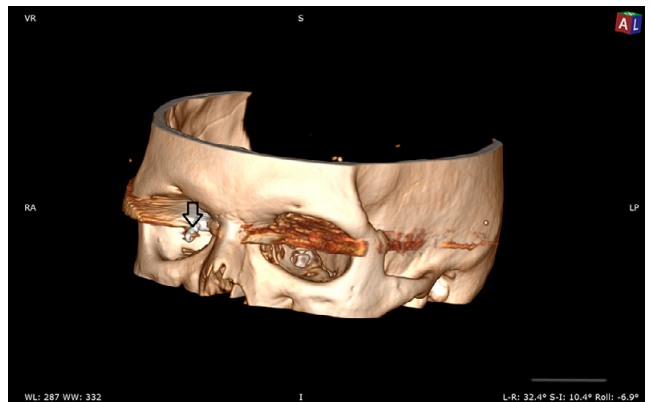


Figure 6. Scan 3-D reconstruction after trauma before surgical treatment. Artifacts visible in the imaging field

DISCUSSION

Among the many divisions of alien bodies in the orbit, classifications based on localization in the anatomical structures of the orbital and surrounding spaces, are most useful for clinicians in establishing a therapeutic treatment plan. Barthendu Shukla developed a division which distinguishes foreign bodies located strictly within the structures of the eyeball and those located in the vicinity of retrobulbar structures [7]. Finkelstein et al. divided foreign bodies into those in the front, located in the area of the eyelids and anterior segment of the eyeball, intraocular and posterior retrobulbar [10]. Identification of the chemical composition of foreign bodies, e. g. metallic, non-metallic (organic, inorganic), is not without significance. It affects, among others, the selection of the diagnostic imaging method to be used, which allows determination of the position of the foreign body, its size, consistency, and the injuries it caused in the surrounding tissues [2]. Sometimes, imaging examinations are the only source of information about a foreign body, in the case when it is not seen itself or the place of penetration into the orbit [4]. Metallic bodies, due to possible ferromagnetic properties, exclude the use of MR in the diagnostics. Non-metallic objects, such as wood, are much more likely to be sources of infection for surrounding tissues. For this reason, their immediate removal is very important in the prevention of complications, such as abscess, inflammation of the eyeball with loss of vision, inflammation of the optic nerve, meninges, formation of fistulas or sinusitis. [1, 2, 5, 6]. In the presented case, the patient provided information about the exact the circumstances in which the injury was incurred, and the foreign body was partially visible and identifiable in the traumatic wound. Diagnostics were selected using classic radiographs and computed tomography. Despite partially obscuring the image of artifacts resulting from the construction of a foreign body, the study examination showed that the bony structures of the facial skull and the eyeball itself were not affected. Photos of the type of fishing tackle were also found, which matched exactly the same as that embedded in the patient's orbit. It could be seen that the part inherent in the wound was smooth and round, which would facilitate its removal.

At the time of the injury, the patient was some distance away after the accident?, which significantly weakened the kinetic energy of the object thrown and did not cause bone tissue injuries (2, 3, 6). The decision was made to remove the foreign body via the entry wound and under general anaesthetic, in cooperation with an ophthalmologist, using

peri-operative local and general antibiotics. No additional surgical access was necessary.

CONCLUSIONS

In the case described, the foreign body that penetrated the eye socket was a fishing weight. Its smooth and round shape and low impact energy did not lead to deep and extensive damage to the surrounding tissues. The location of the foreign body allowed for a relatively simple removal via the entry wound without additional surgical accesses. The procedure was performed in cooperation with a maxillary surgeon and ophthalmologist, after thorough clinical and radiological diagnostics.

Conflict of interests

The authors declare that there are no conflicts of interests

REFERENCES

1. Trojanowski P, Kaczmarczyk R, Trojanowska A, Szczepanek D, A case of a metallic foreign body in the orbit removed endoscopically through the maxillary sinus using neuronavigation, *Post N Med* 2017; XXX(10): 567–569.
2. Ananth Kumar GB, Dhupar V, Akkara F, Praveen Kumar S. Foreign Body in the Orbital Floor: A Case Report. *J Maxillofac Oral Surg*. 2014; 14(3): 832–835.
3. Dekker AP, El-Sawy AH, Rejali DS. An unusual transorbital penetrating injury and principles of management. *Craniofacial Trauma Reconstr*. 2014; 7(4): 310–312.
4. Ohtsubo M, Fujita K, Tsunekawa K, Yuzuriha S, Matsuo K. CASE REPORT Penetrating Injury of the Orbit by a Needlefish. *Eplasty*. 2013; 13: e41. Published 2013 Aug 6.
5. Lewandowski B, Brodowski R, Dymek M, Wojnar J, Stopa P, Rejdak R, Orbital Trauma Complicated by Penetrating Foreign Body, *OKULISTYKA Kwartalnik medyczny*. 2010; 4: 34.
6. Detorakis ET, Symvoulakis EK, Drakonaki E, Halkia E, Tsilimbaris MK, Unexpected Finding in Ocular Surface Trauma: A Large Intraorbital Foreign Body (Bullet). *Acta medica (Hradec Králové) / Universitas Carolina, Facultas Medica Hradec Králové*. 2012; 55: 100–3.
7. Shukla B. New classification of ocular foreign bodies. *Chin J Traumatol*. 2016; 19(6): 319–321.
8. Rahnama M, Świątkowski W, Łobacz M, Kuczyński M, Majewski J, Foreign body in the orbit – case report, *Magazyn Stomatologiczny*. 2011; 21(4): 74–77.
9. Orzechowska-Wylęgała B, Dobrowolski D, Wylęgała A, Niedzielska I, Ciała obce wewnątrz oczodołu w materiale Kliniki Chirurgii Czaszkowo-Szczękowo-Twarzowej w Katowicach, *Magazyn Lekarza Okulisty*. 2015; 9(2).
10. Skorek A, Gębka A, Babiński D, Raczyńska D, Metallic foreign bodies in the orbit, *Otolaryngologia Polska*. 2013; 67(1): 57–60.